

H6e

D.3.8.c

UNIVERSITY OF BRISTOL.

Medical Library.


.....19

Store 576903

SHELF

D.A.





DISEASES AND REFRACTION OF THE EYE.



N. C. MACNAMARA, F.R.C.S.


SURGEON TO THE ROYAL WESTMINSTER OPHTHALMIC HOSPITAL; SURGEON AND
LECTURER ON SURGERY, WESTMINSTER HOSPITAL; SURGEON-MAJOR
H.M. INDIAN MEDICAL SERVICE;

AND

GUSTAVUS HARTRIDGE, F.R.C.S.

SURGEON TO THE ROYAL WESTMINSTER OPHTHALMIC HOSPITAL; OPHTHALMIC
SURGEON TO ST. BARTHOLOMEW'S HOSPITAL, CHATHAM; CONSULTING OPHTHALMIC
SURGEON TO ST. GEORGE'S, HANOVER SQUARE, DISPENSARY.

FIFTH EDITION.



LONDON

J. & A. CHURCHILL

11, NEW BURLINGTON STREET

1891

DISEASES AND REFRACTION
OF THE EYE

BY
J. W. M. JONES



This Volume is Dedicated

TO

HENRY POWER, M.B., F.R.C.S.,

CONSULTING SURGEON, ROYAL WESTMINSTER OPHTHALMIC HOSPITAL ;
OPHTHALMIC SURGEON AND LECTURER ON OPHTHALMIC SURGERY,
ST. BARTHOLOMEW'S HOSPITAL,

IN ACKNOWLEDGMENT OF THE HIGH ESTEEM IN WHICH HE IS HELD
BY HIS FORMER COLLEAGUES,

THE AUTHORS,

AND FOR NUMEROUS ACTS OF KINDNESS AND FRIENDSHIP THEY
HAVE RECEIVED FROM HIM.

The Volume is Dedicated

HENRY TOWER, M.B., V.M.C.

BY THE AUTHOR

THE AUTHOR

AND THE MEMBERS OF THE BOARD AND STAFF OF THE

PREFACE TO THE FIFTH EDITION.

The fifth edition of this manual, so far as diseases of the eye are concerned, has been extensively revised; and with reference to Errors of Refraction, Mr. G. Hartridge's work on this important subject has been incorporated into the volume. The authors have endeavoured in the following pages to describe the practice carried on in a large Ophthalmic Hospital, rather than to discuss the views of various authorities on ophthalmology. Not that we ignore the value of the work which is being done by surgeons in this and other parts of the world, but to a large extent the result of their labours is sifted out in hospital practice, and much of what is sound clings to, and infuses itself into, our everyday work, and will therefore, we hope, be found fairly described in this volume. Our efforts have been directed towards producing a work from which students may learn the diagnosis, pathology, and treatment of diseases of the eye and errors of refraction, and to which busy practitioners may refer for definite information, when in doubt, as to the nature of ophthalmic cases under their care.

London, 1891.

PREFACE TO THE FIFTH EDITION.

The fifth edition of this manual, so far as concerns the text, has been extensively revised; and with reference to those of the illustrations, Mr. G. Lindbergh's work on this important subject has been incorporated into the volume. The authors have endeavored in the following pages to describe the various conditions of the eye, and to explain the principles of their treatment, rather than to discuss the various theories of ophthalmology. But that we regard the value of the work which is being done by surgeons in this and other parts of the world, but to a large extent the result of their labors is set out in a separate part, and we hope to what we regard things to and interest itself in every work, and will therefore, we hope, be found largely beneficial in this volume. Some errors have been observed in the previous editions which will not be repeated in this edition. The illustrations have been improved in the design, and the text has been revised in the most careful manner, and in which every possible error has been corrected, when in doubt as to the nature of ophthalmic cases and their cure.

London, 1861.

CONTENTS.

SECTION I.

CHAPTER I.

	PAGE
Method of Examining the Eyelids—Lachrymal Apparatus and Eyeball—Visual Acuteness—Visual Field—Colour Sense—Tests for Colour Blindness—Light Sense—The Ophthalmoscope: Its Principle and Use—Retinoscopy—Ophthalmoscopic Appearances of the Healthy Eye—Tension of the Eyeball	1

CHAPTER II.

DISEASES OF THE EYELIDS.

Anatomy — Wounds and Injuries — Œdema — Inflammation — Blepharitis — Pediculi — Erysipelas — Syphilitic Ulceration — Epithelioma — Rodent Ulcer — Lupus — Herpes Zoster — Chromohydrosis — Xanthelasma — Horny Excrescences — Miliun — Tumor Tarsi — Nævi — Abnormal Positions of the Eyelids and Eyelashes — Entropion — Ectropion — Trichiasis — Adhesions — Ptosis — Paralysis of Orbicularis Palpebrarum	25
--	----

CHAPTER III.

DISEASES OF THE LACHRYMAL APPARATUS.

The Lachrymal Gland—Acute and Chronic Inflammation—Hyper-trophy—Sarcoma and Carcinoma—Lachrymal Cysts—Displacement and Obstruction of the Puncta and Canaliculi—Epiphora—Inflammation of the Sac—Obstruction of the Nasal duct—Lachrymal Cysts and Fistulæ	62
--	----

CHAPTER IV.

PAGE

DISEASES OF THE CONJUNCTIVA.

Anatomy—Hyperæmia—Muco-Purulent—Purulent—Diphtheritic—Granular—Pustular Conjunctivitis—Injuries of the Conjunctiva—Hypertrophy and Atrophy—Pterygium—Serous and Bloody Effusions into the Conjunctiva—Tumours of the Conjunctiva—Diseases of the Caruncle	75
---	----

CHAPTER V.

DISEASES OF THE CORNEA.

Anatomy—Keratitis—Inherited Specific Keratitis—Plyctenular Keratitis—Fascicular Keratitis—Rheumatic Keratitis—Keratitis Punctata—Suppurative Keratitis—Ulcers of the Cornea—Hernia—Staphyloma—Fistula—Opacities—Pannus—Conical Cornea—Wounds and Injuries—Senile Degeneration—Leprosy—Calcareous Film—New Growths	120
---	-----

CHAPTER VI.

DISEASES OF THE SCLEROTIC.

Anatomy—Episcleritis—Anterior Staphyloma—Wounds of the Sclerotic—Contusions—Tumours	166
---	-----

CHAPTER VII.

DISEASES OF THE IRIS AND CILIARY BODY.

Anatomy—Hyperæmia of the Iris—Iritis—Varieties—Detachment—Coloboma—Tumours—Mydriasis—Myosis—Iridectomy—Cyclitis—Sympathetic Ophthalmitis	174
--	-----

CHAPTER VIII.

DISEASES OF THE CHOROID.

Structure—Choroiditis—Varieties—Tubercle—Sarcoma—Injuries—Detachment—Posterior Staphyloma—Colloid Disease—Coloboma—Ossification	214
---	-----

CHAPTER IX.

PAGE

DISEASES OF THE VITREOUS.

Anatomy—Hyalitis—Muscæ—Opacities—Sparkling Synchrony— Hæmorrhage—Entozoa—Foreign Bodies—Pseudo-Glioma— New Vessels.	235
---	-----

CHAPTER X.

DISEASES OF THE OPTIC NERVE.

Anatomy—Hyperæmia of the Optic Disc—Optic Neuritis— Syphilitic—Malarial Rheumatic Papillitis—Œdema of the Optic Disc—Atrophy of Disc—Congenital Defects of Disc ..	246
--	-----

CHAPTER XI.

GLAUCOMA.

Anatomy—Excavation of the Optic Disc—Glaucoma—Pathology— Symptoms—Treatment	269
---	-----

CHAPTER XII.

DISEASES OF THE RETINA.

Anatomy—Hyperæmia—Retinitis—Retinitis Albuminurica—In Pregnancy—Diabetic Retinitis—Retinitis Pigmentosa— Hæmorrhage into the Retina—Retinitis Apoplectica—Em- bolism of the Central Artery of the Retina—Detachment of the Retina—Opaque Nerve Fibres—Glioma	283
---	-----

CHAPTER XIII.

Colour Blindness—Idiopathic Night Blindness, or Hemeralopia— Snow Blindness—Lightning Blindness—Hemiopia—Scotoma — Amaurosis and Amblyopia—Micropsia—Erythropsia ..	306
---	-----

CHAPTER XIV.

DISEASES OF THE LENS.

Anatomy—Cataracts—Varieties—Operations for—Dislocation of the Lens	329
--	-----

CHAPTER XV.

PAGE

DISEASES OF THE ORBIT.

Injuries—Diseases of the Bones—Inflammation of the Cellular Tissue—Orbital Growths and Tumours—Dislocation of the Globe—Extirpation of the Eyeball—Evisceration	364
---	-----

CHAPTER XVI.

INNERVATION AND ACTION OF MUSCLES.

Diplopia—Paralysis of Orbital Muscles—Causes of Paralysis or of Paresis of Muscles—Treatment—Strabismus—Convergent—Divergent—Treatment—Nystagmus	389
--	-----

SECTION II.

CHAPTER XVII.

OPTICS	423
Reflection	423
Refraction	427
Formation of Images	435

CHAPTER XVIII.

REFRACTION OF THE EYE	440
ACCOMMODATION	446
CONVERGENCE	452

CHAPTER XIX.

METHODS OF DETERMINING THE REFRACTION	460
Acuteness of Vision	461
Scheiner's Method	467

CHAPTER XX.

THE OPHTHALMOSCOPE	469
The Indirect Method	469
The Direct Method	473

CHAPTER XXI.

	PAGE
RETINOSCOPY	481

CHAPTER XXII.

HYPERMETROPIA	503
APHAKIA	513

CHAPTER XXIII.

MYOPIA	515
----------------	-----

CHAPTER XXIV.

ASTIGMATISM	530
ANISOMETROPIA	547

CHAPTER XXV.

PRESBYOPIA	549
Paralysis of Accommodation	554
Spasm of Accommodation.. .. .	555
ASTHENOPIA	556

CHAPTER XXVI.

SPECTACLES	563
CASES	566
APPENDIX	574
REGULATIONS FOR ARMY, NAVY, &C.	576
TEST TYPES	577

LIST OF ILLUSTRATIONS.

FIG.	PAGE
1. Priestley Smith's perimeter	8
2. Normal field of vision	9
3. Illumination of the eye.. .. .	12
4. The ophthalmoscope, direct	14
5. The ophthalmoscope, indirect	14
6. Meibomian cyst	37
7. Operation for entropion.. .. .	40
8. Canthoplasty	42
9. Operation for ectropion.. .. .	46
10. Operation for ectropion.. .. .	46
11. Ectropion.. .. .	47
12. Ectropion.. .. .	48
13. Ectropion.. .. .	49
14. Operation for trichiasis	51
15. Operation for trichiasis	51
16. Operation for trichiasis	51
17. Operation for trichiasis	51
18. Operation for trichiasis	53
19. Puncta and canaliculi	65
20. Passage of probe down nasal duct	70
21. Granular conjunctivitis	96
22. Symblepharon operation.. .. .	114
23. Symblepharon operation	114
24. Symblepharon operation	115
25. Pterygium	115
27. Nerves of cornea	122
28. Staphyloma of the cornea	143
29. The operation of abscission	145
30. The operation of abscission	145
31. Conical cornea	153
32. Arcus senilis	163
33. Anterior staphyloma	169
33A. Detachment of the iris	191
34. Operation for artificial pupil	201
35. Iridectomy	203
36. Iridectomy	203
37. Iridectomy	203
38. Posterior staphyloma	229

FIG.	PAGE
39. Posterior staphyloma	229
40. Structure of optic nerve.. .. .	247
41. Optic neuritis	249
42. Optic neuritis	250
43. The angle of the anterior chamber	270
44. The anterior lymphatic system.. .. .	271
45. Lymph channels	273
46. Glaucoma cup	274
47. Glaucoma cup	274
48A. Sarcoma of retina	304
49. Colour vision	308
50. Colour blindness.. .. .	310
51. Colour blindness.. .. .	310
52. Colour blindness.. .. .	311
53. Section in cataract operation	345
53A. Blunt hook for cataract extraction	346
54. Extraction of lens	347
55. Triangular knife	357
56. Stages of cataract operation	358
57. Stages of cataract operation	358
57A. Scoop	358
58. Stages of cataract operation	358
59. Sarcoma of the orbit	376
60. Removal of the eyeball	385
61. Axis of rotation of the eyeball	390
62. Homonymous diplopia	392
63. Crossed diplopia	392
64. Angle α in emmetropia	405
65. Angle α in hypermetropia.. .. .	405
66. Angle α in myopia	405
67. Strabismometer	408
68. Measurement of the angle of the strabismus	408
69. Convergent strabismus	409
70. Divergent strabismus	413
71. Slide for stereoscope	416
72. Reflection from a plane surface	424
73. Virtual image formed by a plane mirror	424
74. Reflection from a concave surface	425
75. Reflection from a concave surface	426
76. Reflection from a convex surface	427
77. Rays refracted by a medium	428
78. Rays refracted by a prism	428
79. Rays refracted by a prism	428
80. Refraction by a spherical surface	429
81. Refraction by a spherical surface	430
82. Refraction by lenses	430
83. Different forms of lenses.. .. .	431
84. Refraction of rays (secondary axes) by a biconvex lens	432
85. Refraction of parallel rays by a convex lens	432
86. Refraction by a convex lens	433


FIG.	PAGE
87. Refraction by a convex lens	433
88. Refraction by a convex lens	434
89. Refraction by a biconcave lens	434
90. Refraction by a concave lens	435
91. Formation of image	435
92. Formation of image by convex lens	436
93. Formation of image by convex lens	437
94. Formation of image by concave lens	437
95. Cardinal points of the eye	440
96. Formation of image in the eye	441
97. Refraction by dioptric system	443
98. Refraction by convex lens	443
99. Visual angle	445
100. Accommodation	448
101. Scheiner's test	449
102. Diagram representing the accommodation	451
103. Diagram of convergence	454
104. Ophthalmodynamometer	456
105. Relative accommodation	458
106. Visual angle	462
107. Scheiner's test	467
107A. Indirect method in emmetropia	469
108. Indirect method in hypermetropia	470
109. Indirect method in myopia	470
110. Emmetropia	472
111. Hypermetropia	472
112. Hypermetropia	472
113. Direct method in emmetropia	473
114. Direct method in hypermetropia	473
115. Direct method in myopia	473
116. Estimation of the refraction by direct method	476
117. Estimation of the refraction by direct method	476
118. Estimation of the refraction by direct method	476
119. Hypermetropia, issuing rays	479
120. Myopia, issuing rays	479
121. Image of a candle formed on retina	483
122. Image formed at different distances	484
123. Real movements of retinal image	484
124. Image in emmetropia	485
125. Image in hypermetropia.. .. .	485
126. Image in myopia.. .. .	486
127. Rate of movement in myopia	487
128. Rate of movement in hypermetropia	488
129. The oblique shadow	492
130. Plan of recording astigmatism as found by retinoscopy	493
131. Refraction of hypermetropic eye	503
132. Refraction increased by accommodation	504
133. Correction by a convex lens	504
134. Accommodation at different ages in a hypermetrope.. .. .	505
135. Refraction of a myopic eye	516

LIST OF ILLUSTRATIONS.

XV

FIG.	PAGE
136. Refraction of a myopic eye	516
137. Correction by a biconcave glass.. .. .	517
138. Section of a myopic eyeball	519
139. Accommodation at different ages in a myope of 2 D.. .. .	519
140. Size of retinal image in myopia.. .. .	522
141. Section of cone of light after passing through an astigmatic cornea	532
142. Diffusion patches when the cone is divided at right angles ..	532
143. Interval of Sturm	532
144. Simple hypermetropic astigmatism	533
145. Compound hypermetropic astigmatism	534
146. Simple myopic astigmatism	534
147. Compound myopic astigmatism.. .. .	534
148. Mixed astigmatism	535
149. Astigmatic clock face	538
150. Astigmatic fan	539
151. Erect image of a disc seen through an astigmatic cornea ..	540
152. Same disc seen by the indirect method.. .. .	540
153. Tweedy's optometer	544
154. Diagram of the accommodation.. .. .	550
155. Graefe's test for insufficiency of internal recti muscles ..	560
156. Convex and concave glasses acting as prisms	561

Lithographic Plate opposite page 524





CHAPTER I.

Method of examining the Eyelids, Lachrymal Apparatus, and Eyeball—Visual Acuteness—Visual Field—Colour Sense— Test for Colour Blindness— Light Sense— The Ophthalmoscope: its Principle and Use— Retinoscopy— Ophthalmoscopic Appearances of the Healthy Eye— Tension of Eyeball.

EXAMINATION OF THE EYE.

THE essential point to attend to in examining the eye is, that it should be illuminated by a clear, bright light. The patient may conveniently be seated before a window, the surgeon standing in such a position, that no part of his person intercepts the rays of light from falling directly on the patient's eye, and yet enabling him to examine the part thoroughly. The next thing to be done is to open the eyelids, the upper one with the thumb of one hand, and the lower with the other. This manipulation, though simple enough, requires care; even slight pressure on a diseased eyeball frequently causing pain and irritation, followed by a gush of tears from the eye, which for the moment prevents us from proceeding with our examination. The lids having been separated as far as possible, the condition of the cilia, puncta, conjunctiva, sclerotic, cornea, and iris should be carefully noticed.

If one eye only is diseased, we must compare its condition with the sound eye; slight alterations in the colour and brightness of the iris, which may nevertheless be very significant, are often thus distinguishable, and any abnormal appearance of one cornea will be made more apparent by contrast with the other. It is, moreover, by a comparative examination of this kind, that we ascertain the nature of the various derangements that are met with in connection with the muscular apparatus and movements of the eyeball.

EYELIDS AND LACHRYMAL APPARATUS.—The eyelids first call for notice; they may be inflamed or thickened, their movements may be defective, or their position faulty; sometimes they are the seat of small cysts or tumours. The eyelashes may be stunted or displaced, when turned inwards they may rub against the conjunctiva and cornea, and so set up irritation, in these cases the lashes are often small and white, and may easily escape detection. Foreign bodies, in the shape of dust, coal, chips of metal, seeds, wing cases of insects, or the insects themselves, frequently get between the lids and cause intense discomfort, especially when they become lodged under the upper one; usually the sudden onset of the symptoms leads one to suspect a foreign body; we first inspect the cornea, and then the lower conjunctival sac, by gently pulling down the lid, nothing being found, the upper lid must be inverted; a steel probe, or some other instrument which will not easily bend, is laid against the skin of the lid along the upper border of the tarsal cartilage, or about half an inch from the free border of the lid; the surgeon with the other hand takes hold of some of the most prominent ciliæ, and after gently drawing the lid forward, turns it back over the probe; or a simple method, but one requiring a little knack, is to use the thumb of the left hand on the upper lid as a fulcrum instead of the probe, taking hold of the eyelashes with the right, then a slight movement downwards is made with the left thumb, while at the same time the edge of the lid is everted over it. In cases where there is much photophobia, or the patient is nervous, a drop of a solution of cocaine will facilitate the proceeding; should inspection of the inner surface of the upper lid lead to the discovery of no foreign body, it might be lodged in the cul-de-sac of the retro-tarsal fold above the cartilage; this may be carefully sought for with a director; many quite large objects have been missed from neglecting to examine this retro-tarsal fold. Supposing the conjunctiva to be congested and that no foreign body is present to account for it, we press our examination a stage further and endeavour to find out if the congestion is limited to this membrane or involves deeper structures; this can easily be decided by placing one finger against the lower lid and making gentle pressure with it near the edge of the cornea, then slide the lid quickly down so as to empty the conjunctival vessels, when the congestion is limited to the conjunctiva, the pres-

sure will produce a white streak from emptying of these vessels; should deeper structures be involved, then the track will be pink at the corneal margin, due to congestion of the fine network of ciliary vessels which are not thus emptied by pressure.

The condition of the passages by which the lachrymal secretion passes from the eye into the nose often requires investigation, for should they become occluded, the tears will be unable to escape through their proper channel, and accumulating at the inner corner of the eye will overflow and run down the cheek. In these circumstances an idea may be gained of the seat of the obstruction from the following considerations:—If the puncta and canaliculi are healthy, gentle pressure made over the lachrymal sac will cause a minute drop of fluid to ooze out through the puncta; but supposing these structures to be impervious, no such regurgitation of fluid can take place. If, therefore, constant lachrymation exists, and on making pressure below the tendon of the orbicularis, a drop of fluid oozes out through the puncta, we may conclude that the obstruction is in the nasal duct.

There are, however, exceptions to this rule, for if the lachrymation depends on malposition of the puncta, either from chronic inflammation and thickening of the conjunctiva, from paralysis of the orbicularis, or any other cause slightly displacing the puncta, it is evident that only a portion of the tears can gain access to the sac, the remainder flowing over the cheek. In these circumstances, the lachrymal sac being partly full, if pressure is made over it, a drop of fluid will ooze out through the puncta; but in such cases there can be no difficulty in ascertaining the cause of the overflow, the displacement of the puncta being readily seen.

If we have reason to suppose that either the puncta or canaliculi are closed, we may explore the parts by introducing a fine probe into the punctum, and passing it along the canaliculus into the lachrymal sac. In this operation the lid should be slightly everted, so as to expose the punctum, and a probe should be passed into it for about half a line in a perpendicular direction, the instrument being afterwards directed horizontally inwards towards the lachrymal sac. Some slight resistance to the passage of the probe is often felt at one or both extremities of the canaliculus; this arises from the presence of two small valves, and the involuntary contraction of the sphincter muscle which surrounds the

orifices of the duct. Gentle, but continued pressure with the probe, in the direction above indicated, will speedily overcome the spasm of these contractile fibres, and the instrument will then readily enter the sac, and its point may be pushed against the inner bony wall.

THE CORNEA next calls for notice ; it should be perfectly transparent, with a good polish, and should offer no impediment to a thorough examination of the anterior chamber and iris. The corneal examination may be much facilitated by concentrating a cone of light on to it by means of a convex lens (called focal illumination), thus, any slight opacity, irregularity, or want of polish may be detected ; sometimes vessels may be traced upon the cornea. Opacities cause disturbance of vision partly by producing alterations in the curve of the cornea, and partly, also, by the amount of light they obstruct, and the shadows they throw on the retina ; besides these, irregularities of the cornea may be caused by ulceration, which may be of various kinds, abrasions or abscesses. Blood vessels in the cornea may be on the surface, as in pannus, and in those cases where an ulcer travels on to the cornea, carrying with it a leash of vessels ; or they may be in the substance of the cornea, as in interstitial keratitis, when they are so small and closely packed together, that no interspaces can be seen, forming what are called "salmon patches."

Sometimes the posterior layer of the cornea is dotted with a number of small spots, "keratitis punctata," usually in the shape of a pyramid with its base downwards to the margin of the cornea, and its apex near the centre ; these dots are small deposits of lymph on Descemet's membrane, accompanied with proliferation of the epithelium. The examination of minute changes in the cornea may be facilitated by means of a magnifying glass, which may be employed with focal illumination. An exceedingly valuable plan is to employ the direct ophthalmoscope, with a +20D behind it. In this way a good illumination is obtained, together with a strong magnifying power, so that very minute changes may be detected ; thus, in interstitial keratitis which has completely cleared up, nothing may be seen with focal illumination, yet, with the ophthalmoscope and +20D, fine branching lines may be detected, which are the remains of vessels developed during the progress of the keratitis, which remain as direct evidence of its previous existence.

THE ANTERIOR CHAMBER AND IRIS.—The aqueous in health should be colourless and quite transparent, so as to offer no impediment to the examination of the iris, lens, &c. ; but it may be turbid from inflammatory effusion, blood, or pus. In iritis, the colour of the aqueous is usually altered, so that the fibres of the iris will appear less distinct as well as being of a somewhat different colour, thus the blue iris will appear greenish. Attention must next be directed to the iris, which should be clear and bright, showing the arrangements of the fibres on its anterior surface; the pupil should be round and regular, responding readily to light, and also to accommodation. To determine if the pupil acts well to light, the patient should be placed before a moderately strong light, which falls obliquely, from one side only, on the eye. The unaffected eye should be closed with a handkerchief, or the hand. The surgeon alternately covers and uncovers the affected eye with his hand, keeping the pupil well in view. If the iris is healthy the pupils will have dilated while the light was shaded from the eye, but will contract again the instant that bright luminous rays reach the retina. Any deviations from this rule should be carefully noticed, for, in the absence of synechia or other mechanical impediment to the motions of the iris, the character of its response to luminous impressions afford us valuable information in many disorders affecting the deep-seated structures of the eye. The retina of one eye, may, however, be diseased and yet the pupil dilates and contracts on the stimulus of light, for light, falling on the retina of a healthy eye, will, through reflex action, cause the contraction of the iris in the other eye, although it be amaurotic; and, on the other hand, an inactive and dilated pupil does not invariably indicate a diseased condition of the retina.

The patient is next directed to look steadily at some distant object, and then, suddenly, to turn his attention to some object a foot or so in front of the eye, so as to call into action the accommodation; contraction of the pupil should at once take place. In some cases the pupil loses its power of contracting to light, while, at the same time, it retains its power of acting with the accommodation; this condition is sometimes spoken of as the "Argyll-Robertson pupil." The next point to notice is, if the iris be steady or tremulous, and if it retains its vertical position, for it may bulge forward or be pushed backward in abnormal conditions. In all doubtful

cases apply a weak solution of atropine to the eye; the existence of synechiæ are demonstrated in this way, the affected pupil dilating in an irregular manner. But supposing there are no such complications, the atropine will nevertheless be useful, enabling us the better to examine the deeper structures of the eye with the ophthalmoscope.

Attention should next be directed to the functions of the retina, which may conveniently be divided into: (1) The form sense, or visual acuteness; (2) The colour sense; and (3) The light sense.

1.—*The Form Sense, or Visual Acuteness.*—It is of great advantage to be able to record the visual acuteness in a numerical manner, not only as a standard of comparison between one person and another, but also to ascertain if the patient's vision is improving or otherwise.

To find out the acuteness of vision we must first determine the smallest retinal image, the form of which can be distinguished, and it has been found out by experiment that the smallest retinal image which can be perceived at the macula, corresponds to a visual angle of one minute at the nodal point. Based upon this principle, test-types have been formed, so that every letter, when at its proper distance, will subtend an angle of five minutes, while each part of the letter is separated from the other parts by an angle of one minute. These test-types should be hung in a good light and usually about six metres away, so as to avoid calling into action the accommodation; each letter, or row of letters, is marked with the distance at which the normal eye should read it; the smallest letter which can be seen distinctly at this distance will represent the patient's acuteness of vision. The top letter should be distinct at 60 metres, the next at 36, and each succeeding row at 24, 18, 12, 9, and 6 metres respectively; thus every letter when held at the distance for which it is marked will form exactly the same sized retinal image. The patient placed at 6 metres should, without any accommodation, read the bottom line with each eye separately; this may conveniently be expressed in the shape of a fraction, in which the numerator is the distance at which the type is read, and the denominator the number of the line. Of course, if the patient is always 6 metres from the type, then the numerator will always be the same; thus, to give an example, if the top letter only is clear to the patient we put down the vision as $\frac{6}{60}$, if the first three lines then $\frac{6}{24}$, if the bottom line then $\frac{6}{6}$, or

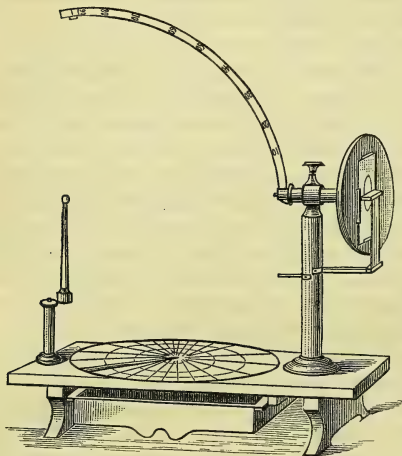
1, *i.e.*, normal vision ; though we may thus reduce the fraction it is better not to do so, as we then know at what distance the record was taken. The range of accommodation gradually diminishes from a very early period, so that the nearest point of distinct vision slowly recedes ; this change is due to alterations in the crystalline lens.

THE VISUAL FIELD.—The visual acuteness only tells us the condition of vision at the macula, which is the point of most acute vision ; this acuteness gradually decreases in all directions towards the periphery ; in some cases, such as glaucoma, hemiopia, atrophy, hemorrhages, &c., it may be necessary to accurately map out on a chart the whole visual field. The defects met with are very variable, the extent of the field may be diminished in all directions ; half of each field may be lost, as in hemiopia, or a blind patch may be found in any part of the field ; this is called a scotoma, and may be of any shape. Sometimes a complete blind ring is found between the fixing point and the periphery (ring scotoma), in others a large sector-like defect may be found to exist. The field for white is greater than that for colour, red being somewhat greater than green ; sometimes no defect is found for white, but only for colour, as in tobacco amblyopia, when the defect is usually central. The old plan of measuring the field of vision was as follows :—The patient was seated at a distance of a foot from a blackboard, or a frame in which has been placed a sheet of blue tissue or other paper. On the centre of this a small cross is marked with chalk or pencil, and the patient is directed to fix his eye upon this point, the other eye being closed. The crayon is now moved over the paper, being carried successively upwards, downwards, and to the right and left horizontally, marking in each direction the extreme limits at which the patient perceives it. The same plan is followed for all intermediate points, and the outline thus drawn upon the board or paper shows the limit of the field of visual perception. The other eye may then be tested in the same way.

A much more scientific plan is to map out on a chart the field of vision with one of the numerous perimeters now in use. It will be sufficient to describe that of Mr. Priestley Smith which is one of the simplest and most inexpensive. It consists of a wooden stand, having, at one end, an iron upright, and at the other, a boxwood support, against which the cheek of the patient is to rest : at the top of the upright

is the quadrant carrying a clip; the quadrant is rotated by a wooden hand-wheel attached to its axis, and is balanced by a weight upon the wheel, which enables it to stand in any place at which it is placed without being fixed.

FIG. 1.



The charts slide into clips at the back of the hand-wheel, and immediately behind this is fixed a horizontal scale, the divisions of which correspond with the markings on the chart. As the quadrant rotates the chart on the back of the wheel moves with it, so that in whatever position the quadrant stands, the corresponding meridian lies against the scale.

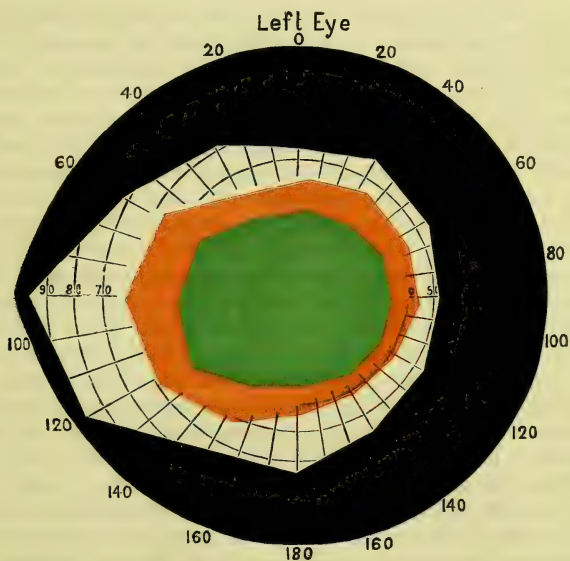
The patient being conveniently seated, and the cheek resting against the support, he is directed to look at a small white ivory point at the axis of the instrument; the observer stands behind the hand-wheel, so that the patient and the chart are both under observation. The test object is a square of paper placed in a vulcanite pointer, which the surgeon holds in his left hand, while he rotates the hand-wheel with his right, and pricks the readings on the chart with a suitable pin.

There are two sorts of charts, marked respectively A and B, A corresponding to the whole visual field, B only to the central area on a large scale. To correspond with these two kinds of charts, the scale of the perimeter is marked out on either side to correspond, and also marked A and B; the side A is used with A charts, the side B with B charts. The great practical advantage of this instrument, in addition to its exceeding simplicity, is that besides being used in the ordinary way in which each meridian is tested and the result marked on the chart, the test object may, if we wish, be

placed in the clip on the quadrant, and so made to sweep the field in a circular manner, every point where it first becomes visible or disappears being pricked upon the chart. This plan will be found exceedingly valuable in some cases, such as hemianopsia, or where a scotoma is present. It is also an advantage to have two kinds of charts, the B charts being convenient where any defects in the field exist and we wish to make out the defects carefully.

The following diagram represents Chart A, showing the field of vision for white, red, and green.

FIG. 2.



A rough idea of the extent of the visual field may be obtained by directing the patient to close one eye, and with the other to look steadily at one of the observer's eyes. While the patient keeps his eye fixed in this way, the observer moves one of his fingers in various directions over the patient's field of vision, ascertaining how far the finger can be seen from the optic axis of the eye under observation.

It is evident that under these circumstances, if the function of any part of the retina external to the macula is impaired, that the patient will be unable to see the observer's fingers when situated at the corresponding part of the visual field.

2.—*The Colour Sense*.—Colour perception is most acute at the macula; the field for colours is somewhat smaller than that for white, the red field being slightly greater than the green, but much depends on the degree of light, the size and brightness of the coloured object used for the test, as well as upon the care taken in the examination. Defects of the colour sense may arise from disease, or may be congenital.

DEFECTS IN COLOUR-SIGHT.—The most reliable method for detecting defects in colour-sight is by means of Holmgren's worsted test, which consists of bundles of coloured skeins of various shades, red, orange, yellow, blue, green violet, pink, brown, and grey. Test 1, the patient is first supplied with a skein of light but pure green, and told to match it with other shades of the same colour; should he do this correctly without taking up any of the confusion colours, brown or stone, he may be assumed to have a normal colour sense: should he, however, hesitate and show a tendency to take one or more of the confusion colours, though eventually rejecting them, he may have a weak chromatic sense; this test separates the colour-blind from the normal, but does not tell us the nature of the defect. Test 2 is necessary to enable us to decide the kind of colour defect. This consists of a purple skein of medium shade; should the examinee place with the test colour blue and violet, or one of these, he may be assumed to be red blind; should he select green or grey with it, then he is green blind. For a confirmatory test, Test 3, a bright red skein is taken, the red blind may select with it green and brown skeins which appear to the normal eye darker than the test colour; while the green blind will select red and brown of lighter shade than the test colour. It is best to make no mention of the names of the colours to the patient, the examination being limited to finding out whether the test colours are properly matched. Colour blindness is a congenital defect present in about 2 or 3 per cent. of the population, but it also occurs sometimes in disease.

Colour vision is more fully discussed in Chapter 14.

3.—*The Light Sense* is more or less connected with the *Form* sense, and varies much according to the amount of light exposure to which the eye under examination has been previously exposed; everyone is familiar with the difficulty of seeing when passing from a strong light into a dark room; a few seconds are necessary before one becomes accustomed to the darkness, objects which were at first not to be seen come gradually into view; this is spoken of as the adaptability of the retina; probably the visual purple plays an important part in this adaptability. It is owing to these variations of the light sense that no test can be relied upon to give absolutely accurate results. The most reliable means of estimating this sense is with Foerster's photometer, which consists of a square box blackened on the inside; at one end are two tubes through which the patient looks, while at the opposite end are two white lines which serve as the test objects; a standard candle is employed and the degree of illumination regulated by a window, whose size can be altered at will; when the window is 2mm. square and the lines can be perceived at the regulation distance, the light sense may be assumed to be normal.

Another method is that of Bjerrum, and consists of the ordinary Snellen types printed grey on a grey background, the contrast between the letters and the background being much less than is the case with black letters on a white ground, which must be taken as our unit; in this test the *Form* and *Light* sense are not separated. In many cases where the visual acuteness is much diminished, so that fingers cannot be counted, the light sense may be roughly tested by passing the hand in front of the eye so as to shade it momentarily, the shadow should be recognised by the patient; or one eye being closed, light may be thrown into the other eye by means of the ophthalmoscope mirror; by varying the position of the mirror we can give to the light all directions, and the patient should be able to indicate from which direction the light proceeds; this gives us the light sense over the whole field, and is spoken of as the patient's projection; had the retina been detached or its function destroyed in any part, the projection corresponding to this part would be defective.

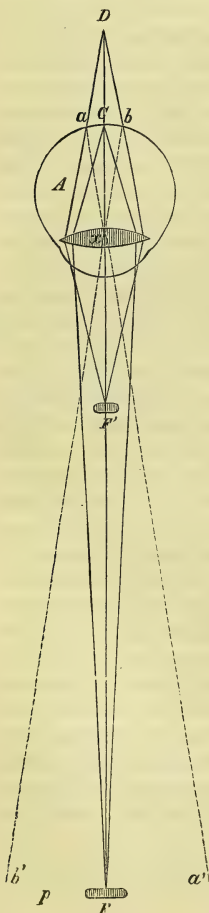
THE OPHTHALMOSCOPE.

Illumination of the Eye.—The reason why we cannot ordinarily see the interior of the eye without the aid of an ophthalmoscope, as well as the principle of its action, will

become intelligible by reference to the following figure (Fig. 3), in which A represents the eye under examination, accommodated to the distant point F, where the flame of a lamp is supposed to be situated. It is evident that some of the divergent rays, proceeding from the luminous body at F, will fall upon A's cornea, and being refracted by its dioptric media, will meet at C on A's retina. Some of these rays are absorbed, others are reflected by the structures of the fundus, and these, before emerging from the eye, must pass through precisely the same media as they did on entering it; and in consequence of their pursuing this path, they will be brought to a focus at the point from which they started—namely at F. Unless an observer's eye, therefore, can be made to take the place of the luminous body at F, it is evident that none of the reflected light from A's retina can possibly reach the observer's. A's pupil, therefore, appears black to a person in the position p , or, in fact, at any other point than at F. If, however, a mirror with a hole in its centre, through which light can pass, be substituted for the lamp, and the rays reflected from its surface be directed into the eye A, the light returning from A's retina can now enter the observer's eye, which, under these circumstances, may be made to occupy the position of the lamp, as represented in Fig. 3.

Again, suppose the luminous body is removed from the point F to F' (the

FIG. 3.



patient's eye being still accommodated for the distance $A F$), the divergent rays proceeding from it, and being refracted by the dioptric media of A , would intersect at D , were they not intercepted by the fundus of the eye; as it is, they form a circle of light extending from a to b . But since the eye A is adjusted for the far point F , and not for F^1 , it follows, that the rays reflected from any point in the circle $a b$, after emerging again from A , will be brought to a focus at the distance $A F$; and those from the extreme points a and b will converge respectively to a' and b' in lines prolonged from a and b through x , the optical centre of A . Under these circumstances, an observer's eye at any point p will receive a few of the rays from A 's retina, which will thus appear illuminated, without the aid of a mirror.

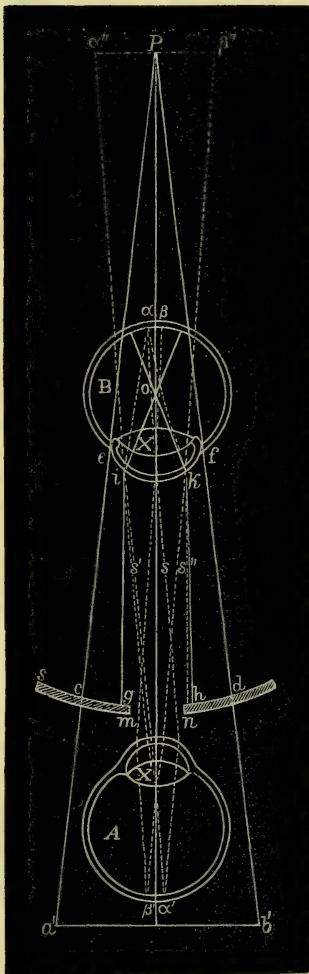
If these considerations be applied to the ophthalmoscope, the principles upon which this instrument depends as a means of illumination may be readily comprehended, it being essentially a mirror, constructed so as to allow the observer's eye to take the place of the flame of the lamp, as represented in Fig. 3. As, however, the deeper parts of the eye are only seen through its refracting media, we have still to explain the formation of images of those parts, which may be distinctly visible to the observer.

Formation of Images.—There are two modes of examining an eye with the ophthalmoscope, known as the direct and the indirect methods. By the former an erect real image is perceived by the observer, and by the latter an inverted aerial image is produced.

1. By referring to Fig. 4 the *direct method of examination* may be readily understood. A represents the eye of the observer and B that of the patient, $c d$ the concave mirror of the ophthalmoscope S . Rays after reflection from its surface proceed as if they came from $a' b'$ situated behind it, and converge towards some point P . A portion, however, of the rays included between $g i$ and $h k$ is intercepted by the dioptric media of B , and these, after refraction, intersect at O within the eye, from whence they again diverge to form a circle of light upon B 's retina. If in this circle any two points α, β , be taken, the reflected rays from which pass through the sight-hole $m n$ of the ophthalmoscope, they will be brought to a focus at $a' \beta'$ on A 's retina, and a virtual, erect, and magnified image $a'' \beta''$ of $\alpha \beta$ will be seen by the observer, apparently projected beyond the patient's eye.

In the *indirect* method of ophthalmoscopic examination, it is necessary to place a convex lens in front of the patient's eye,

FIG. 4.



the strength of the lens used should be about 14D. In Fig. 5, A represents the observer's eye, B that of the patient, S the concave mirror of the ophthalmoscope. Rays reflected from its surface, $c d$, would find a focus at some point o ; but by the interposition of a convex lens, L'' (object lens), the rays are brought to an earlier focus at P , whence, after intersection, they diverge until intercepted by $g h$, the cornea of B. A portion of this light, corresponding to the aperture of the pupil $i k$, enters the eye, and rendered slightly convergent by its dioptric media, proceeds to form a circle of light $m n$ on the retina. The rays, returning from any two points a and β in this circle will emerge parallel, or slightly convergent from B (according to its accommodation), and after refraction by the object lens L'' will be united at a' and β' respectively, at the distance, approximately, from L'' of q its principal focus. A real, inverted, and magnified image $a' \beta'$ of $a \beta$ will thus be formed; and this will be distinctly visible by A at a distance of twelve or fourteen inches, the rays diverging from a' being brought to a focus on the retina at a'' , and those from β at β'' .


In places where gas is available, a round full flame from a gas lamp will probably afford

the best source from which to obtain light to throw into the eye for ophthalmoscopic purposes; but a kerosene lamp may be used with equal advantage.

It is not always necessary to dilate the pupil with atropine before making an ophthalmoscopic examination; a general idea of the fundus of the eye may be gained without the use of any mydriatic; in fact, after some practice it matters little what the position of the patient, the source of illumination, or the instrument we use—there is no difficulty in seeing the fundus of the eye; but with beginners it is different, and the following directions must be attended to. The patient should be desired to look attentively at a mark on the opposite wall of the room, so that his eye may be accommodated for a distant point; if now he close one eye, the pupil of the other will dilate sufficiently to allow of an ophthalmoscopic examination. Should it be found necessary to make a more perfect observation, a gelatine disc or a solution of homatropin may be applied to the eye.

It may be well to remind the reader that except in cases where one eye only is diseased, and the abnormal conditions are clearly and unmistakably apparent, a prognosis should not be ventured on until both

FIG. 5.



eyes have been examined, the state of the one being carefully compared with that of the other. Nothing is so likely to damage one's reputation, or to shake the confidence of our patients in our judgment and skill as giving a hasty or ill-considered opinion, which on a subsequent examination it may be found necessary to alter; for this reason, also, it is advisable to write down the appearances presented by the eye in a notebook with which to refresh our memory, and enable us to form an idea of the progress of the disease, if at any subsequent period the patient present himself for inspection.

Examination of the Actual Inverted Image.—The eye of the surgeon, that of the patient, and the source of light should be upon the same level, the lamp being placed close to, and a little behind the ear of the latter. The patient is directed to fix the eye under observation so that it is inclined slightly inwards, when the rays of light from the ophthalmoscope will fall directly upon the optic disc.

In using the ophthalmoscope, the sight-hole of the instrument should be applied to whichever of the observer's eyes is most convenient to himself, its rim being made to rest against his eyebrow, and as he turns his head, the instrument will move with it. The object lens in front of the patient's eye should be held a little obliquely between the thumb and forefinger of the other hand, the ring and middle fingers resting against the patient's forehead, which thus acts as a fixed point, enabling the observer to approximate or withdraw the object lens to or from the patient's eye, so as to bring the retina into focus with the greatest precision, and also to follow the movements of the eye under examination.

The beginner may be troubled by the reflection of the ophthalmoscope from the cornea of the patient. It appears as a brilliant image of the mirror on the surface of the cornea, hiding that part of the retina which is behind it. To get rid of this reflection we must slightly incline the mirror in such a manner that the reflections shall fall to the side of the parts to be examined.

THE INDIRECT METHOD of examination enables us to obtain an inverted image of the details of the fundus, magnified about five or six diameters, according to the strength of the objective used, and the refractive condition of the observed

eye. If the pupil is dilated, as it should be when a thorough and minute examination is required, we can at a glance see the optic disc and the surrounding parts; this method of examination is very useful, in that it enables us readily to scan over every part of the fundus within range of the ophthalmoscope, and without the necessity of correcting the patient's refraction.

THE DIRECT METHOD OF EXAMINATION.—In this mode of examination no object glass is required, but the observer has to go close to the patient's eye. The lamp must be placed on the side corresponding to the eye under examination. If the right eye be the one under examination, the observer should sit on the right side of the patient so that his right eye corresponds with the patient's right, and *vice versâ* for the left eye. The direct method of examination, though it only allows of a much smaller portion of the fundus being seen at one time, gives us a much larger image, being magnified about fifteen diameters; at the same time everything is seen in its true position; many minute changes can thus be detected which would escape recognition by the indirect method. The great difficulty that every beginner finds with this method is to keep the accommodation in abeyance. When the observed eye is hypermetropic or myopic, it will be necessary to correct this by means of the proper lens behind the sight-hole of the ophthalmoscope. The emmetropic observer will see clearly, without accommodation, the details of the emmetropic eyeball whose accommodation is suspended; should the observer be in doubt about his own accommodation, then he should turn on convex glasses with the wheel of his ophthalmoscope; should a weak plus glass blur the image, the case would be one of emmetropia; if, however, the image remain clear, then the strongest convex glass, with which the details can be clearly seen, will be a measure of the hypermetropia, if the fundus looks indistinct without any correcting lens and still more so when convex glasses are turned on, then we try concave glasses; the weakest concave glass which gives a distinct view of the disc will be a measure of the patient's myopia; this subject will be further considered in the chapters on refraction. The erect method is also useful in detecting vitreous opacities, a convex 8D behind the ophthalmoscope will facilitate their detection. For lens and corneal opacities convex 20D should be employed.

THE FOCAL METHOD OF ILLUMINATION, OR THE EXAMINATION OF THE EYE BY TRANSMITTED LIGHT.—For this purpose the observer and patient are seated opposite one another, and the lamp is placed in advance, and to one side of the latter, in order that its rays may be concentrated upon the eye under examination by a convex lens. The eye being illuminated in this way the observer can magnify any part of the lens, iris, or cornea, with a convex glass held in front of the eye. By this means valuable aid is afforded the surgeon, especially in detecting foreign bodies in the anterior chamber, or in cases of synechiæ and occlusion of the pupil from false membranes. *Nebulæ* also, which are difficult to appreciate with the unaided eye, may thus be distinctly defined. In fact, abnormal changes going on in the lens and the structures anterior to it are frequently best appreciated by the focal method of illumination.

SYSTEMATIC EXAMINATION.—In all cases submitted to an ophthalmoscopic examination, it is best to proceed in a systematic manner; first use the focal illumination, noticing the cornea, iris, and lens; then take up the ophthalmoscope and notice if any part of the fundus come into view at a distance, should a vessel or part of the disc be seen, the patient is hypermetropic or myopic; if the former, the vessel will move with the head of the observer on moving to one side, if the latter then the movement will be against the movements of the observer, showing it to be an inverted image; this having been noted, the patient should be requested to look quickly up and down, then straight in front of him, thus we may detect vitreous opacities floating about. Next proceed to the indirect examination, following it up by the direct; of late we have noticed a tendency on the part of many observers to use the direct examination only, leaving out the indirect; we cannot but think this is a mistake: much is gained by a comparison of the two methods.

RETINOSCOPY is best explained by placing a convex lens at such a distance from a screen that rays of light passing through the lens from a concave mirror are focussed on the screen. In these circumstances a small and bright image of the lamp is formed, with a sharply defined and dense surrounding shadow. If the lens is now brought nearer to, or removed from the screen, the image of the lamp becomes feebler, and the line of demarcation between it and the surrounding

shadow is fainter. As the lens is moved to different distances from the screen, the variations between the brightness of the image and the surrounding shadow will be evident. At the same time, supposing the concave mirror from which the light is reflected is rotated, the direction of the image and shadow will be seen to move on the screen in a direction opposite to that in which the mirror is rotated. If this principle is applied to the human eye, and light reflected from the surface of a concave mirror (ophthalmoscope) is directed into the eye, on looking through the sight-hole of the instrument we perceive an illuminated area surrounded by a deep shade on the retina. But since the image is seen through the media of the eye, the direction in which the image moves as the mirror is rotated will depend upon the refraction of the eye under examination. In examining an eye in this way it is advisable, though not absolutely necessary, to apply atropine so as to dilate the pupil. The patient's eye should be about four feet from that of the surgeon; the room should be darkened, and the patient's eye shaded by a screen. The mirror of the ophthalmoscope used should be concave with a focal length of about 25cm., and the light thrown from it on to the patient's eye at an angle of about 10° or 15° .

Under these conditions we see a clearly illuminated area with a surrounding shadow on the retina of the patient's eye. As the mirror is rotated the image and shadow move in the opposite direction if the eye is hypermetropic, emmetropic, or slightly myopic. But if the image and shadow move in the same direction as the mirror the eye is certainly myopic, to the extent of 1D. The higher the ametropia, the worse is the illumination, and the slower the movements of the shadow. The whole subject of Retinoscopy will be more fully considered in Chapter 21.

OPHTHALMOSCOPIC APPEARANCES OF THE HEALTHY EYE.

Colour of the Fundus.—The whole of the interior of the retinal sphere which can be brought into view through the pupil, or the fundus oculi, as it is usually termed, is among all dark races different in colour from that which is present among Europeans. This difference arises from the deep brown or black pigment, filling the hexagonal cells of the

retina in dark races, obscuring the vascular structure which is situated behind it. The fundus of the eye therefore appears of a *brownish-grey* colour among these people; whereas in fair Europeans it is of a *crimson orange* hue, the incident light being reflected from the vascular network of the choroid, which is seen through the transparent retina.

The *optic disc*, or *papilla*, which is the termination of the optic nerve, or the spot at which it expands into the retina, will be found about one-tenth of an inch internal to the axis of the eye; it is the first point which attracts the observer's attention in making an examination with the ophthalmoscope. The shape of the healthy papilla is generally circular, but it frequently appears oval, because the optic nerve and papilla are inserted sideways into the eye, and we see it more or less obliquely, and consequently, it is shortened in its horizontal diameter. In other cases this oval form is due to a real irregularity of the optic nerve, or to an irregularity in the dioptric media, notably in astigmatism. The size of the optic disc is by no means the same in all cases, and will appear to be augmented or lessened according to the power used to magnify it.

The colour of the disc is not uniform, its outer part being greyish and mottled. This appearance is caused by the difference in the light reflected from the nerve tubules, which is greyish, and that from the white glistening bands forming the lamina cribrosa. At the point of exit of the retinal vessels the white appearance is very marked, and often presents a depression; when this is well marked, it may be spoken of as a physiological cup. The inner half of the disc is of a decidedly redder tint than the outer half, because it is more thickly covered by vessels and nerve fibres, and hence there is no reflection from the fibres of the lamina cribrosa in this situation. It is absolutely necessary to become acquainted with the different appearances which may be presented by the healthy optic disc, or these varying conditions may be mistaken for indications of disease; the outer greyish-white tint, the central depressed appearance and whitish hue, together with the inner pinkish half of the disc, are conditions which vary considerably, but are more or less distinctly recognizable in all healthy eyes.

At the point where the lamina cribrosa ceases, the optic nerve is contracted, and the opening in the choroid being

narrow, in a certain measure compresses the nerve trunk ; for this reason, a sort of double border is often seen around the margin of the optic papilla. Under the choroidal margin is the line, more or less dark, that indicates the border of the opening in the choroid ; under the sclerotic margin is a bright crescent or circle, formed by the curving round of the sclerotic fibres, and appearing between the choroidal margin and the fine greyish line that indicates the narrowest part of the nerve itself, and is therefore called the proper nerve-boundary. The latter under normal circumstances is not usually sharply defined. The choroidal rim is always strongly marked, especially at the outer border of the disc where there is frequently a slight deposit of pigment.

The point at which the *central artery and vein* of the retina enter the eye through the optic disc is subject to considerable variation. Generally, the artery passes through the whitish and depressed centre of the papilla, and, after emerging from the disc, divides dichotomously, its branches ramifying in all directions towards the periphery of the retina ; but the central artery may perforate the disc at any other point ; not unfrequently one or two larger branches are noticed in the centre of the papilla, while others pass through its circumference, perhaps close up to the scleral margin of the disc.

The apparent calibre of the vessels will vary with the magnifying power employed in observing them ; practice alone will thus enable us to appreciate abnormal changes in the calibre of these vessels. One frequently reads accounts in which the retinal vessels are said to be over-full or empty, as the case may be ; but in truth it is most difficult to determine this point.

The arteries, as well as their branches, are thinner, lighter in colour, and straighter than the veins, which are darker in colour and more sinuous in their course. The arteries seem to be transparent in their centres ; this arises from the difference in the degree of illumination of the prominent centres of the arteries, as contrasted with their sides : from their conformation, it is evident that the sides of a vessel would receive and reflect relatively less light, and therefore appear in shade.

If in the normal eye the central vein be carefully examined, a pulsation may often be noticed in it, which will be rendered more evident on gentle pressure being made on the eyeball.

If the compressing force be increased beyond a certain point, the pulsation at once stops, and the veins become almost invisible from the cessation of the flow of blood through them. In the healthy eye no arterial pulse can be seen, but if pressure be made on the eyeball it will become apparent. We noticed this in a marked manner in cases accompanied with considerable intraocular pressure, as, for instance, in glaucoma.

The Retina.—The retina is so transparent a structure, that when examined by the ophthalmoscope, the small amount of light reflected from it is lost in the abundant reflection from the bright scarlet background of the choroid; but in the case of the natives of India and other dark races, the retina may be distinctly recognized as a grey, striated layer, lying over the black hexagonal cells of the retina, and extending from the circumference of the optic disc as far outwards as the ora serrata.

The Macula Lutea will not be recognised until the student has had some practice with the ophthalmoscope. It is situated in the axis of vision, and its position may be found from the fact of the retinal vessels passing above and below it, but not crossing the macula, which appears as a slight depression in the retina, of a reddish-brown tint with oval borders, or as a minute red spot occasionally surrounded by a yellowish ring. In healthy eyes the macula can only be clearly made out in about 40 per cent. of the cases which present themselves at the hospitals. The sensitiveness to light of this spot, its dazzling reflex, and its similarity in appearance to the surrounding fundus, are the chief reasons which prevent its being clearly seen.

Sometimes a sort of halo may be seen surrounding the macula, which shifts its position with every movement of the mirror; this is probably a reflex from the edge of the depression of the macula; occasionally a reflex takes place from the fovea centralis having somewhat the appearance of light coming from a miniature bull's-eye lantern; another appearance, with which it is necessary to be familiar, is what is called a shot silk appearance of the retina, frequently very plainly to be seen in young hypermetropes; this reflex shifts its position with every movement of the mirror, and is due to some of the light being reflected from the retina instead of passing through it.

The Choroid.—A layer of fine capillary vessels extends immediately behind the lamina vitrea of the choroid, and between these vessels and the sclerotic, the venæ vorticosæ and large branching pigmented cells of the choroid are situated. It follows, in consequence of this arrangement of the vessels, that when examining the eye with the ophthalmoscope, light passing through the transparent media falls on the capillary layer behind the retina (provided the hexagonal cells of the choroid are transparent), and the light which is reflected back to the eye of the observer from this layer of vessels, gives the uniform red colour of the background of the eye in the healthy fair-skinned European. In albinos, or in persons in which there is very little pigment in the choroid, the larger vessels of the tunica vasculosa may be seen. Evidently, as the vascular and pigmented layers of the choroid line the inner surface of the sclerotic, it is impossible to see this latter structure with the ophthalmoscope, unless, in consequence of atrophy of the choroid, a portion of its vascular and cellular structures is destroyed, and then the white glistening sclerotic may be seen.

The cornea, aqueous, lens, and vitreous, being in the healthy eye perfectly transparent, no light is reflected from them when under examination by the ophthalmoscope, and consequently they are invisible.

TENSION OF THE EYEBALL.—The estimation of the tension of the eyeball may conveniently conclude our systematic examination. It is determined by palpation thus: the patient is directed to close the lids and look downwards, the surgeon places the tip of one forefinger on the outer part of the eyeball so as to steady it, while with the index finger of the other hand, he makes gentle pressure on the other side of the globe, so as to feel the amount of resistance and estimate the amount of dimpling that takes place. In the healthy eye a certain amount of dimpling of the coats of the eyeball can be produced, but in glaucoma it may become very hard, while in cases of degenerative changes the tension may be much below the normal. For convenience we may divide the degree of tension into "normal tension" (T_n); tension slightly increased ($T + 1$); tension very decided, but still allowing slight indentation with the finger ($T + 2$); tension stony hardness, admitting of no dimpling ($T + 3$); tension diminished ($T - 1$); further diminished ($T - 2$); very soft

(T — 3). The normal tension of the eyeball, however, has a certain range or variety in persons of different ages, build, and temperament, and according to varying temporary states of the system, as regards emptiness and repletion; hence it is important that the tension of one eye should always be compared with that of the other, as it is uncommon to find differences in the tension of the two eyes except as a result of disease. This subject will be more fully considered in the chapter on glaucoma.

CHAPTER II.

DISEASES OF EYELIDS.

Anatomy—Wounds—Œdema—Blepharitis—Pediculi—Erysipelas—Syphilitic ulceration—Epithelioma—Rodent ulcer—Lupus—Herpes zoster—Chromhydrosis—Xanthelasma—Horny excrescences—Milium—Tumor Tarsi—Nævi—Ptosis—Paralysis of orbicularis palpebrarum.

THE EYELIDS.

ANATOMY.—The eyelids afford protection to the eyes from injury and excessive light, they also keep the surface moist and lubricated by means of the glands which open on their surface. The movements of the lids are associated with those of the eyeball, so that when the eye is turned upwards, the palpebral opening is increased; on looking down the upper lid descends and decreases the opening.

The lids are composed of delicate skin, having but few sweat glands and very fine hairs; immediately below the skin is the orbicularis muscle, with a little connective tissue and no fat, next is a plate of dense fibrous tissue, which is usually called the tarsal cartilage, and gives to the lid its necessary shape and firmness; to this cartilage the levator palpebræ is attached; on the inner side of the tarsal cartilage, which is grooved for their reception, are the meibomian glands, about twenty-five in number, which run vertically and open at the margin of the lids immediately behind the row of cilia; the secretion from these glands lubricates the edges of the lids, the cilia are a strong row of hairs at the margin of each lid, they are furnished with sebaceous glands, which are sometimes called the glands of Moll. The inner surface of the lids are lined with the conjunctiva, which is a delicate vas-

cular mucous membrane containing a few glands, the glands of Henlé; the conjunctiva, after lining the lids, is reflected on to the eyeball, but in such a manner that a deep cul-de-sac is formed at the point of reflection beneath the upper lid, and a lesser one beneath the lower.

CONTUSIONS OF THE EYELIDS.—A blow on the edge of the orbit or eyelids is apt to be followed by considerable swelling and ecchymosis of the part, a “black eye” being the result. We are frequently consulted in such cases, in order, if possible, to prevent the disfigurement caused by a bruise in this conspicuous part of the face. If the patient applies to us soon after the injury has been inflicted, and before any considerable amount of blood has become effused into the loose cellular tissue of the part, we may generally prevent any further ecchymosis by the application of a piece of lint soaked in a mixture of tincture of arnica and water (one part of the former to eight of the latter), which should be kept constantly applied to the eye; it promotes the absorption of effused blood, prevents discoloration, and relieves pain and stiffness; or a solution of muriate of ammonia, acetate of lead, or ice may be used in the same way. Ecchymosis of the eyelids may be the effect of a far more serious injury, and becomes an important indication in cases of blows on the head, where one or more of the bones of the orbit have been fractured.

WOUNDS OF THE EYELIDS.—In simple incised wounds of the lids, the edges of the wound must be brought into apposition with one or more horse-hair or fine silk sutures, and dressed with a solution of boracic acid or wool; the sutures may be removed after two or three days. If the wound has been inflicted some days, it is advisable to freshen its edges so as to enable them to unite without suppuration. Incised wounds of the eyelids, by dividing the fibres of the levator palpebræ, may interfere with the action of the muscle. In some few cases injury to the lids or supra-orbital region, either from a contused or incised wound, has been followed by paralysis of the levator palpebræ; in other cases, not only has ptosis followed an injury of this kind, the result of peripheral neuritis, but gradual loss of sight has supervened. Instances of this kind are not to be confounded with those depending upon detachment of the retina, consequent on a blow or fall on the eye; in these cases the loss of sight occurs immediately after the accident, and the ophthalmoscope will enable us to detect the nature of the injury.

In the case of lacerated wounds of the eyelids; having washed the wound with some antiseptic fluid, the edges should be brought together and retained there by means of sutures. Occasionally, from inattention to these apparently trivial matters, the wound does not completely close, and a slit, or a button-hole opening through the lid remains.

BURNS.—The eyelids are sometimes damaged by scalding water, by fire, the explosion of gunpowder, or other combustible material. Our efforts in these circumstances must be to prevent the formation and contraction of a cicatrix, which is certain to occur unless care be taken in dressing the wound. Having been carefully washed with an antiseptic fluid, a pad of absorbent gauze should be applied, the surface of which may be smeared with vaseline. Over this dressing antiseptic wool should be secured with a bandage, so as to keep the lids well stretched over the globe of the eye until the wound has healed, the dressing being changed once a day.

Should the edges of the lids be excoriated, they are apt to grow together, particularly at their inner and outer angles; in these conditions the eye must be opened frequently, and the lids separated from one another as far as possible, so as to break down any adhesions that may have formed; the margins of the eyelids must be smeared with vaseline, or any similar substance, not likely to excite irritation, but which will prevent the raw edges of the lids from remaining in contact. Supposing that a portion of the skin and subcutaneous tissue has been destroyed, the wound will heal by granulation. In such a case skin-grafting should be practised; in this way we may prevent the formation of a cicatrix, or lessen its size and the ectropion it will cause.

ŒDEMA OF THE LIDS is incidental to the progress of various diseases—as, for instance, abscesses, and inflammatory affections of the skin of the face; or more remote ones—such as diseases of the kidneys or heart. But we sometimes meet with cases of œdema in the following circumstances:—The patient probably states that he had been perfectly well prior to going to sleep. In the morning he was unable to open his eye on account of the lids being stiff and swollen; there may have been some pain in the part, but this is not always the case. The eyelids are œdematous, shining, and swollen, but not discoloured; and on forcing them open, the orbital conjunctiva will also be found œdematous, but not inflamed.

This state of things usually arises from one of two causes : either from the sting of an insect, or from the effect of the damp night air blowing over the patient's face. As a general rule, if occurring from the poison of an insect, the point of the sting or bite will be marked by a spot, which is more painful and inflamed than the rest of the swelling ; moreover, both eyes are rarely affected in this way. Whereas, when the œdema arises from cold, there is seldom any pain in the part, except that caused by the tension and swelling of the cellular tissue of the lid, and both eyes are generally equally affected ; nor are the eyelids red and inflamed. In these cases no special treatment is required ; the part may be fomented with a solution of boracic acid. The œdema rapidly disappears.

HORDEOLUM, or, as it is commonly called, *a stye*, is an acute inflammation of the cellular tissue of the lid, leading to the formation of pus which points at the margin of the lid. It often commences at the root of one of the cilia. The abscess is seated, therefore, in the thickness of the lid, it varies in size from that of a millet seed to that of a bean ; and is hard to the touch. Abscesses of this description generally occur among debilitated people, and they are more common among children than adults. Styes commence with an itching sensation in the part, which soon becomes red and swollen, the lid often being œdematous and very painful ; it may undergo absorption, but more often bursts and discharges its contents externally.

In the early stages of the disease, the inflammatory action may be arrested by means of iced compresses, but if suppuration has occurred, it is better to apply warm boracic fomentations to the eye. Tonics are frequently called for, and, unless prescribed, successive styes are apt to appear one after the other, to the great annoyance and discomfort of the patient.

BLEPHARITIS, OR TINEA TARSII, consists of an eczematous inflammation affecting the margin of the eyelids, and is most frequently met with among the children of the poor, living in the crowded parts of our large towns. Under any circumstances it too frequently runs a subacute course, unless attention is paid to the case in the first instance. Tinea tarsi may be conveniently divided into two stages ; in the first, active changes are still going on at the margin of the eyelids ; and in the second, the cilia have been destroyed,

and the margins of the lids are thickened and indurated, presenting the condition known as *lippitudo* or *blear-eye*. There can be no question as to the fact that in no inconsiderable number of cases of blepharitis, that astigmatism, or some other error of refraction directly excites or keeps up the irritation and inflammation of the margins of the lids. This point should always be attended to in cases of this description.

Symptoms.—The patient complains of what he usually terms weak eyes; they itch a good deal, particularly after work, and on rising in the morning they are glued together. Symptoms of this kind may have been going on for a long time, inconveniencing the patient a good deal, but not being sufficiently severe to prevent his performing his usual work. On examining the eyelids of a person suffering from tinea in its early stages, we notice a crust, or scab attached to a part or the whole of the free margin of the patient's eyelids; beneath these crusts are a number of little pustules at the roots of the cilia; the skin is slightly red and inflamed. A succession of these pimples form and burst, leaving a scab clinging to the skin with considerable tenacity. The conjunctiva is always somewhat injected. This state of things having lasted for a longer or shorter period, the sebaceous and Meibomian glands become irritable, and their secretion is augmented in quantity and altered in quality, so that the lids stick together during sleep. The skin beneath the scabs at length becomes ulcerated and swollen; the crusts are no longer furfuraceous, but hard and thick, and the eye is very irritable; the patient cannot read or work for even a short time, without his eyes becoming red and painful. In consequence of the swollen condition of the margins of the lids, the puncta are thrust away from the eyeball, and the tears accumulating in the lacus lachrymalis, not only flow over the side of the cheek, but by remaining in contact with the eye induce chronic conjunctivitis; this, in its turn, by presenting a rough surface to the cornea, induces changes in its epithelial layers, not amounting to any perceptible opacity, but sufficient to interfere slightly with the perfection of vision.

If the disease should advance to its second stage, destruction of the eyelashes and hypertrophy of the free margins of the lids take place, in consequence of the long-continued irritation that has been going on there. It by no means follows, however, that the cilia are completely destroyed; but they frequently drop out, the bulbs of the hairs remain-

ing. and from them distorted misdirected cilia spring, some of which, turning inwards, produce trichiasis. The surface of the skin beneath the scabs being ulcerated, and discharging, thick crusts form on the edges of the red and hypertrophied eyelids; at the same time the Meibomian glands become inflamed, and in too many cases the ducts leading from them ultimately close, the disease is then incurable. The margins of the lids are thickened, and the puncta being thus everted, and often closed, the tears stream over the inner corner of the eye; the cornea becomes hazy.

Treatment.—The treatment of tinea tarsi is complicated by two unfavourable circumstances: the first is, that it most often occurs among children, who are impatient of treatment; and secondly, they generally live in neglected, dirty habitations, being the offspring of unhealthy parents. In conjunction with constitutional treatment, comprising the preparations of arsenic and iron combined, as a rule, with cod-liver oil, local remedies are useful. In the first instance, the scabs on the margins of the lids must be removed by hot alkaline fomentations; after the scabs have been softened they may be detached with a rag and hot water. Having removed the scabs, an ointment composed of half a drachm of hyd. oxid. flav. to an ounce of vaseline, should be carefully applied along the margins of the eyelids, or the ung. hyd. nitrico-oxidi dil., one drachm, vaseline, three drachms, may be employed in the same way. The chief point, however, to attend to is, that the ointment is brought into contact with the diseased surface; if simply smeared over the scabs, the medications will be useless.

In more confirmed cases, where the margins of the lids have ulcerated, the lashes should, in the first instance, be cut off close to their roots, and the scabs removed with a pair of forceps; after which, a pencil of mitigated nitrate of silver should be drawn along the outer edge of the ulcerated surface, or we may paint the part over with the tincture of iodine; or a solution of nitrate of silver. Subsequently the dilute oxide of mercury ointment may be used by the patient; but the lids will probably have to be painted over with the tincture of iodine twice a week for some time. Great care will be required to keep the parts clean, bathing them several times a day in a solution of boracic acid. Any errors of refraction in the patient's eyes should be carefully corrected by means of proper glasses.

PEDICULI.—Lice occasionally take up their abode among the cilia, their ova covering the eyelashes, and the cilia looking as if they had been dusted over with a black powder. These parasites give rise to the most intolerable itching of the part; beyond the irritation, the eye appears to be healthy. The treatment to be adopted is to wash the parts well with warm solution of boracic acid, and then smear the palpebral margin and cilia with staphisagria, and if this fails, with mercurial ointment.

ERYSIPELAS.—The skin of the eyelids is liable to be attacked by phlegmonous or erysipelatous inflammation, the latter usually extending from the parts around, and not uncommonly following exposure to cold, or suppuration of the lachrymal sac. In these cases the lids become red, swollen, and tense; vesicles form on the inflamed surface of the skin, and bursting, give exit to a sero-purulent fluid. The patient complains of a tingling, burning feeling in the part, but seldom of deep pain, unless the cellular tissue of the orbit is affected; he is feverish, his tongue is foul, and the pulse usually feeble. In the majority of instances, the inflammatory action soon subsides and the parts return to their normal condition; but in severe cases the disease extends backwards to the orbit, and may involve the optic nerve; in any circumstances, in bad or neglected cases of erysipelas, the cellular tissue of the lids slough and is likely to lead to ectropion.

Treatment.—In the early stages of erysipelatous inflammation of the lids, it is advisable to paint over the skin with a solution of nitrate of silver (ʒj to an ounce of water). This application should extend beyond the limit of the inflamed skin, cold compresses may subsequently be employed. If suppuration has occurred, the skin and cellular tissue of the lids must be freely incised, and dressed with antiseptic gauze, the surface to be applied to the skin being smeared with vaseline and iodoform. The tincture of muriate of iron may with advantage be administered internally, together with stimulants and beef tea.

SYPHILITIC ULCERATION of the eyelids may be the effect of acquired or of hereditary syphilis. The diseased action in the former class of cases usually commences on the conjunctiva or margin of the eyelid, the virus having been directly applied to the part; from this point the chancre gradually invades the skin and the whole thickness of the

lids. Syphilitic ulceration of the eyelids is, however, more commonly a secondary affection. We have seen instances of the kind especially of gumma, which had not been recognized as syphilitic until a considerable portion of the lid had been destroyed. In these circumstances the ulceration usually commences at the margin of the lids: at first the skin only is involved, but in the course of time the tarsal cartilage and other structures are affected, so that the whole thickness of the lid is implicated in the ulcerative process; the edges of the wound become everted and thickened, and there is a constant discharge of bloody matter from its surface. The patient seldom complains of much pain in the part, the progress of the affection being generally slow; but should the individual be in a weak state of health on the invasion of the disease, it may then make rapid strides, speedily involving the entire eyelid, and causing great suffering. In some cases the ulceration is comparatively superficial, the skin alone being affected; in these instances, the course which the disease takes is generally protracted, and often almost painless.

Treatment.—Whether depending upon primary or secondary syphilis, the only method of treating these cases which can be relied upon is by mercury, judiciously and cautiously administered. Hydrarg. c. creta, combined with soda and quinine, ought to be prescribed; its action being watched, and the mercury discontinued on the first indication that the system has become affected. In many respects mercurial vapour baths afford a preferable method of administering the drug; but as they sometimes tend to exhaust the system, by the increased action of the skin which they occasion, this is an objection to their use where the patient has been previously in a feeble state of health. In these circumstances we may order the mercurial ointment to be rubbed into the patient's arm-pits and thighs night and morning, until the ulcer on the eyelids assumes a healthy appearance, which will usually be the case before the constitutional effects of the drug are apparent. Probably one of the most suitable local applications we can employ for these ulcers is iodoform. Blackwash is often useful, or an ointment composed of ten grains of sulphate of copper to an ounce of simple ointment.

EPITHELIOMA.—The lower lid is not unfrequently affected with epithelioma; it seldom appears before an individual has

reached the age of forty, and may commence as a small hard flattened lump on the edge of the eyelid near the caruncle, gradually extending to the lower lid. This thickened tissue is due to an abnormal growth of the epithelial cells; these cells are generally flat and packed closely together. At first the affection appears so insignificant, and so closely resembles an ordinary wart, that probably little notice is taken of it. After a time, however, the pimple or wart-like growth ulcerates, and a small indolent sore, with raised edges and a glassy-looking surface, appears. The disease advances slowly, and the original sore may appear for a time to have healed, a thin cicatrix forming over it, which is soon broken through by the exudation of a serous fluid from the ulcerated surface beneath. The diseased action extends deep into the corium, gradually involving the skin of the cheek in a mass of ulceration, from the surface of which there is a constant sanious discharge, and at the same time the lymphatic glands in the parotid space become enlarged.

It is important to make a correct diagnosis in cases of this description, for epithelial cancer, situated in any accessible part of the body, may possibly be effectually extirpated in its early stages. In the more advanced stages of the disease, it may still be advisable to remove the abnormal growth, applying a strong solution of chloride of zinc to the surface of the wound. Apparently hopeless cases are recorded, in which this practice has been followed by satisfactory results. If the disease is allowed to run its course, the patient must inevitably sink under it.

Rodent Ulcer more frequently commences in the skin of the lower lids than along the edge of the eyelid; the disease begins as a dry wart, and after the excrescence has been shed several times the skin ulcerates. The ulcer has a hard base and edge; it spreads with remarkable and characteristic slowness, eroding the neighbouring structures year by year, the surface of the sore is devoid of granulations, and glazed. There is very little discharge from the ulcer unless it happens to become inflamed. Rodent ulcer seldom appears until after an individual is forty-five years of age. The disease must be entirely removed by means of the knife, and the surface of the wound subsequently smeared over with the chloride of zinc paste, so as, if possible, to destroy the whole of the morbid growth.

Lupus as a rule occurs earlier in life than rodent ulcer ; it is attended with more inflammation and less hardness, and may be accompanied by lupus elsewhere on the cutaneous or mucous surfaces. The tuberculous character of the disease is marked from an early stage of the affection. It is probably best treated by scraping, together with the injection of Koch's lymph.

HERPES ZOSTER.—The skin of the lids, like that of other parts of the body, is sometimes affected with impetigo, leprosy, vitiligo, eczema, and herpes. These require no special notice, except perhaps the last, in which the deeper structures of the eye itself are sometimes affected. Herpes zoster is not uncommonly mistaken for erysipelas of the eyelids. Herpes frontalis, however, is always confined to one side of the median line, and the eruption appearing over only that portion of the skin which is supplied by the ophthalmic division of the fifth nerve. The pustules are small and numerous ; they often, however, become confluent, and their contents dry up into a scab, which subsequently falls off, leaving a scar very much like that seen after small-pox. There is less constitutional disturbance in herpes than in erysipelas. On the other hand, the patient is affected with a peculiar numbness, mingled with pain which is often very severe, and precedes the eruption, the heightened sensibility continuing long after the inflammatory outburst, and not passing beyond the median line. The nerves of sensation appear to play an important part in herpes zoster ; the peripheral distribution of the fifth, from cold or some such cause, becomes inflamed, and the eruption succeeds as the result of an extension of the vascular excitement of the cutaneous tissues anatomically related to this network.

The intolerable pain in these cases is perhaps best relieved by a subcutaneous injection of atropine or morphia. The extract of belladonna and sulphate of quinine may be administered internally, and the acetate of lead lotion applied over the inflamed portion of the skin. If the forehead only is affected, although there may be an eruption on the upper eyelid, yet the eye will not suffer. If the eruption appears on the upper part of the nose, there will be slight iritis ; while if the tip of the nose is affected, the eye will suffer severely. These differences are explained by reference to the anatomical distribution of the ophthalmic division of the fifth nerve, by which the disease is localized. The branch

which supplies the tip of the nose is the one which supplies also the ophthalmic ganglion, and through it the structures of the eye. After the acute symptoms of the disease have passed away, dark brownish scars frequently remain to mark the site of the eruption; their colour subsequently fades into that of the skin around them, but the scars themselves remain like those of small-pox, during the remainder of the patient's life.

CHROMHYDROSIS consists in the supposed excretion of an indigo-blue material from the surface of the eyelids. The colouring matter is easily removed by oil or glycerine, but not by water. The disease mostly occurs among women whose menstruation happens to be disordered, and their health more or less impaired. A remarkable case of this kind is related by Warlomont, which was made the subject of most careful investigation, and every means taken to prevent the practice of any deception on the part of the patient; still, the case is hardly satisfactory, and cannot be regarded as affording unequivocal evidence of the existence of this most singular disease, and doubts still exist on the matter. Most surgeons are of opinion, and we agree with them, that chromhydrosis is generally the result of a trick, or the invention of an hysterical patient, the colouring matter having been applied by her own hands.

XANTHELASMA PALPEBRARUM.—These buff or yellow patches, not very unfrequently seen near the inner angles of the eyelids, give the patient considerable uneasiness on account of their appearance. The subject has for some time past engaged the attention of Mr. Hutchinson; he has arrived at the conclusion:—That xanthelasma never occurs in children; whilst it is fairly common in middle and senile periods of life. In a small proportion of very severe cases, jaundice, with great enlargement of the liver, is met with. The form of jaundice is peculiar, the skin becoming of an olive-brown, or almost black tint, rather than yellow, and the colour being remarkable for its long persistence. In many cases in which there has been no jaundice, there is yet the history of frequent and severe attacks of functional disturbance of the liver. Xanthelasma occurs more frequently in females than in males, the proportion being two to one. In all cases the xanthelasmic patches appear in the eyelids first; and not in more than about 8 per cent. do they ever extend to other

parts. The patches invariably begin near the *inner* canthus on the *left* side. It is probable that of the causes mentioned, under which the pigmentation of the eyelids may be disturbed, disorder of the liver is the most powerful; hence the fact that the more extensive cases are usually associated with hepatic disease.

Warts not unfrequently grow from the skin of the eyelids, and if near its free margin, they may press upon, and bend some of the cilia inwards against the eyeball. The sooner, therefore, a wart so situated is removed the better; it is useless to waste time in applying caustic, it should be snipped off with a pair of scissors.

HORNY EXCRESCENCES are now and then met with springing from the skin of the lids; they seem to depend upon the secretion from a sebaceous gland becoming hardened, and fresh exudations taking place over it; layer after layer of the sebaceous matter thus drying over the original deposit, the horn-like projection at length becomes of such a size as to disfigure and inconvenience the patient considerably. The same plan of treatment is to be adopted as in the case of a wart; the excrescence, and the skin from which it appears to grow, being snipped off with a pair of curved scissors.

MILIUM.—Accumulations of sebaceous matter occasionally occur in the ducts of the subcutaneous glands, forming little tumours on the edge of the eyelids, resembling minute pearls, situated beneath the epidermis. They seldom exceed a pin's-head in size, and frequently form in groups of irregular shapes and dimensions. It is seldom necessary to interfere with minute tumours of this kind; but if it is deemed advisable to do so, the epidermis covering them may be scratched with the point of a knife, and the contents of the cyst squeezed out.

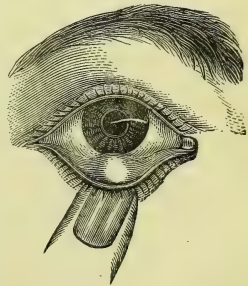
SEBACEOUS TUMOURS, only slightly larger than those last described, but which may grow to the size of a split pea, and contain sebaceous matter, are occasionally met with in the skin of the lids. They may be readily removed by carefully incising the skin over them, and then squeezing the cyst and its contents out of its nidus. The walls of these cysts, however, are by no means thick, and are almost sure to burst in our efforts to remove them, in which case the remains of the cyst should be torn away from its attachments. If this is not done, the tumour is apt to appear again; in fact, if left to nature, the course they usually take is, after growing to a

certain size, to burst and give exit to their contents, which speedily re-form so long as the cyst remains intact.

Large sebaceous tumours, similar to those noticed in other parts of the body, sometimes form in the eyelids, most commonly springing from the periosteum of the frontal bone. They generally contain a glairy, fatty matter, and frequently also a number of hairs. Like the other forms of cystic tumours, they give the patient no pain or inconvenience, beyond such as arises, in this particular situation, from their bulk, which is often considerable. In excising a tumour it is well to make the incision from without inwards, or in a direction parallel to the fibres of the orbicularis, as the morbid growth is usually situated beneath this muscle. The entire cyst must as far as practicable be removed, and it will much facilitate the operation if this is accomplished without opening it. Under antiseptic precautions there is every chance of the wound healing by the first intention, a slight scar only remaining to indicate the position of the incision.

MEIBOMIAN CYST, CHALAZION, OR TUMOR TARSI.—These tumours arise in the follicles of the Meibomian glands, and are therefore embedded in the substance of the tarsal cartilage. As they increase in size, they form painless swellings beneath the skin of the lid, varying in size from a split-pea to a horse-bean; they are unsightly, and induce a disagreeable stiffness of the lids, but beyond this are harmless. On everting the lid from which they spring, the position of the tumour is marked by a circumscribed, yellowish-white projection (Fig. 6). These tumours sometimes become inflamed, and suppurate; the abscess, having discharged its contents through the conjunctiva, leaves a minute fistulous opening, round the mouth of which a bunch of granulation tissue grows, looking very like a patch of hypertrophied villous tissue, so commonly seen in cases of granular conjunctivitis. In cases of tumor tarsi, evert the lid, and the conjunctiva being put on the stretch, so as to render the tumour prominent, a crucial incision must be made into it through the conjunctiva, so that the cyst may be laid open, and its contents scraped out with a miniature Volkmann's spoon.

FIG. 6.



Immediately after the operation the wound fills with blood, and the size of the tumour may not perhaps appear to have diminished; but in the course of a few days the blood is re-absorbed, and all traces of the cyst disappears. There is no necessity for any after-treatment in a case of this kind. Cold-water dressing may be applied over the lids for twenty-four hours, the eyes being closed with a pad and bandage.

CALCAREOUS CONCRETIONS among old and gouty subjects are apt to form in the ducts of Meibomian glands, and may then be felt as small nodules beneath the conjunctiva. On evert- ing the lid, the white deposits in the duct may generally be seen; they give rise to irritation by rubbing against the surface of the cornea, inducing hyperæmia of the conjunctiva, which cannot be cured till the foreign substance in the duct is removed. The plan of treatment in these cases is to evert the lid and slit open the duct, and then with a spatula or some such instrument to scrape out its calcareous contents.

FIBROMA of the eyelids is occasionally met with as a small hard tumour, of very slow growth; sometimes being exquisitely painful. A growth of this kind should be removed as soon as possible.

NÆVI (*Teleangiectata*).—A nævus must necessarily be of comparatively small size if confined to the eyelids. For the most part they are of congenital origin, the muscular fibres covering them gradually become absorbed, and the nævus then appears as a soft and compressible tumour, situated under the skin, its colour depending upon the preponderance in it of the arterial or venous elements. The blood may readily be squeezed out of the nævus if slight pressure be exerted over its surface; but the sponge-like mass refills and swells up again, as soon as the compressing force is withdrawn. In like manner, a nævus becomes swollen and congested, if the patient strains to any extent, as in the act of coughing or crying.

Treatment.—Our object is to obliterate the vascular network, of which the nævus is constituted; but at the same time, if possible, to prevent the skin covering it from being destroyed. If this is not provided against, a cicatrix may form, which, in contracting, may evert the eyelid. A small nævus may often be destroyed by applying over its surface some strong nitric acid. In larger nævi two or three worsted

threads soaked in perchloride of iron may be passed through the base of the tumour, and left there for a day or two—in fact, till they have excited some amount of inflammation, when they should be withdrawn. The inflammatory action thus set up is often sufficient to obliterate the vessels forming the nævus. Electrolysis may be employed with advantage in cases of this description. This method of treatment should be used in the first instance in larger nævi occupying the eye-lids, and should it not succeed we may pass two fine pins at right angles through the skin under the nævus. Beneath these pins a few turns of silk ligature should be twisted so as to strangle the nævus. As soon as the part begins to slough the needles may be removed.

Angiomata of the eyelids have been described; they may be pedunculated, but are more apt to have a broad base, though movable beneath the skin. Dr. C. S. Bull has shown that most of these vascular tumours of the lids are venous, and contained in a cyst wall. Tumours of this kind should be incised. Lid-clamp forceps must be applied, and the tumour may then be removed without loss of blood. If loss of skin results from the operation it may better be replaced by skin-grafting than by any form of plastic operation.

ENTROPION, or an incurving of the margin of the eyelids, may be partial or complete, and may be conveniently divided into two classes—the spasmodic, and permanent.

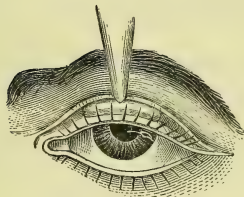
The first is seldom met with except amongst old people, whose skin has become lax and wrinkled. We occasionally see cases of the kind resulting from the application of a compress and bandage, as after the operation of extraction of the lens. The lower lid is generally affected in instances of spasmodic entropion; its ciliary margin being curved inwards on itself, carries the cilia with it, so that the latter cannot be seen unless the skin of the lid be retracted, when the cilia assume their normal position; the irregular contraction however, of the fibres of the orbicularis soon causes the margin of the eyelid to become again incurved. There is not only a lax condition of the cutis in these cases, but the outer fibres of the orbicularis lose their contractile power; whereas those near the margin of the lid, acting with unusual force, turn the cilia inwards in the way described. The eye-lashes, being thus brought into contact with the cornea, cause such an amount of irritation that pathological changes

gradually take place in its structure, ending in vascular opacity, or, it may be, destructive ulceration.

Treatment.—Should the entropion have arisen from mechanical causes, as, for instance, from the pressure of a bandage over the eyelids after the extraction of a cataract, it is only necessary to remove the cause, and after a time the orbicularis will regain its functions, and the lid be restored to its normal position. This result may be hastened by first retracting the lid, and then applying a strip or two of rubber plaster along its cutaneous surface, so as to keep the lid in its natural position. In the more inveterate cases, whether depending on mechanical or other causes, it will be necessary to excise an elliptical portion of the skin and subcutaneous tissues, parallel to the free margin of the lid; when the contraction of the tissues as they cicatrize will, by shortening the external covering of the lid, retain the ciliary border in its normal position.

A pair of entropion forceps should be used to pinch up a fold of the skin, running parallel to the ciliary margin of the lid, which may then be excised with curved scissors (Fig. 7). The amount of skin to be removed will depend upon the extent of the entropion, and may be judged of by noticing if the fold seized between the blades of the forceps is sufficient to restore the cilia to their normal position. Care must be taken to avoid wounding the puncta; in

FIG. 7.



fact, it is seldom advisable to remove the skin towards the inner angle of the eye, for although the punctum may not be wounded, it may be everted by the contraction of the cicatrix, and will thus inconvenience the patient, the tears not being able to escape through the puncta, a watery eye results.

Permanent entropion differs from the spasmodic form, in that the incurving of the lids depends upon changes in their structure, often caused by granular conjunctivitis. This form of conjunctivitis leads to the formation of cicatrices of the mucous and submucous tissues; these cicatrices, in contracting, shorten the tarsal cartilage from side to side, as well as from above downwards, so that the ciliary margin of the affected lid is turned inwards, in conse-

quence of the increase in the natural curvature of the cartilage. The lid affected in this way becomes shortened from side to side, and its mucous membrane is generally hypertrophied; it is evidently impossible, in the presence of so much structural change, to restore the cilia to their normal position by retracting the skin of the lid. Entropion may occur, among old people, from the eyeball sinking into the socket; the palpebral border of the orbicularis is then apt to become inverted. The upper and lower lids are equally subject to this form of malposition, and one or both eyes may be affected. In permanent entropion the eyelashes are often destroyed, a few irregular and distorted cilia alone remaining. These stumps, however, by constantly rubbing against the surface of the cornea, produce such an amount of irritation, that the transparency of the cornea is gradually lost.

The Treatment of Permanent Entropion consists in either removing the cilia, together with their bulbs, so as to prevent their rubbing against the cornea, or else excising a portion of the skin, and grooving the tarsal cartilage, so as to restore the margin of the lid to its normal position.

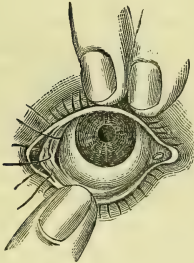
The excision of the cilia and their bulbs is to be managed as follows:—A pair of Desmarre's forceps having been applied to the lid, an incision is made through the skin and subcutaneous tissues, down to the tarsal cartilage, parallel to and about one-eighth of an inch from the margin of the lid. The extremities of this cut are to be carried down to the free edge of the lid, and the small flap of skin, enclosed within the incisions thus made, is to be dissected away from the tarsal cartilage, together with the subcutaneous tissue and bulbs of the cilia. The wound must be carefully cleaned and examined for any remaining bulbs of the cilia, which should be removed. Boracic acid dressing may then be applied till the wound has healed.

If it is not thought advisable to destroy the cilia, the following operation may be resorted to:—Desmarre's forceps having been adjusted to the lid, an incision is to be made through the skin and subcutaneous tissues, down to the tarsal cartilage, parallel to and about the sixth of an inch from its ciliary border, taking care to keep clear of the bulbs of the eyelashes. A second incision is to be made, of the same depth, parallel to the first, and about a quarter of an inch from it, and joining it at either extremity. These

incisions are then to be deepened by cutting obliquely downwards into the tarsal cartilage, so as to form a groove in its substance, and the skin, subcutaneous tissue, and cartilage, contained within the above incisions, are to be dissected away. The object of this operation is, in fact, to cut an elongated, wedge-shaped piece out of the skin and tarsal cartilage, so that when the edges of the wound have united, the incurved palpebral margin of the lid will be everted, and resume its normal position. In this operation care must be taken not to wound the puncta, or cause them to become everted by removing the integument about them.

As entropion is frequently complicated and augmented by a shortening of the tarsal cartilage from side to side, it necessarily follows that the longitudinal diameter of the palpebral fissure becomes lessened in these cases. It may be necessary to elongate the contracted fissure, by slitting up the outer commissure of the eye, as far as the orbital process of the malar bone.

FIG. 8.



After dividing the external commissure, the edges of the wound must be fixed by means of sutures or strips of adhesive plaster applied to the integument of the forehead, and the lower to the cheek, so as to keep the lips of the incision apart, converting, in fact, the primary horizontal wound into a vertical one. So long as these sutures can be retained, the edges of the incision evidently cannot unite; in practice, however, we find it very difficult to get our patients to submit to this treatment; the pain and inconvenience they endure is great, and though, undoubtedly, the proceeding is

most beneficial if it can be carried out, still it is desirable that some simpler means should be devised for attaining the same end. This may be very imperfectly accomplished by slitting up the commissure, and then uniting the conjunctival and cutaneous edges of the wound by means of a continuous suture of fine silk or catgut.

Pagenstecher, after dividing the external commissure, takes up a horizontal fold of skin and orbicularis muscle with a pair of forceps, and then passes several ligatures through the base of the fold, allowing them to ulcerate their way out through the skin: the cicatrices thus formed produce permanent

eversion of the incurved lid. In passing the ligatures through the fold of skin, the point of the needle is to be entered close to the external surface of the tarsal cartilage, and brought out at the edge of the lid; the ligature is to be firmly tied and allowed to suppurate out, which it generally does in six or eight days. Water-dressing may be applied subsequent to the operation.

ECTROPION, OR EVERSION OF THE EYELIDS, may be divided into three classes. 1st. Temporary eversion of the lids, depending usually on purulent conjunctivitis. 2nd. Ectropion arising from hypertrophy of the conjunctiva. 3rd. Ectropion from the contraction of a cicatrix, the skin of the lid having been destroyed either by an injury, or from disease.

1. The first form of ectropion generally arises under the following circumstances:—In cases of purulent conjunctivitis, the mucous membrane may be so much swollen, that the free margin of the lid is forced away from the eye to such an extent as to become doubled back upon itself, in precisely the same way as if we had everted it for the purpose of examining the palpebral conjunctiva. In these circumstances the fibres of the orbicularis, at the line of eversion of the lid from a constricting band, by pressing on the vessels impedes the circulation of blood through them, and the everted conjunctiva may in consequence slough, irreparable injury being done to the eye. Among young children suffering from purulent conjunctivitis this form of ectropion is especially likely to occur, the lids having been everted, perhaps, in dropping some lotion into the eye and no trouble taken to restore them at once to their natural position.

The Treatment of this form of eversion of the lids, consists in scarifying the swollen and everted conjunctiva, so as to empty its vessels of blood, after which a little gentle pressure on the swollen lid will reduce the œdema, and the lid may then generally be returned to its natural position with ease, but in some cases may have to be retained there with a pad and bandage applied over the eye for twenty-four hours. The dressing should be removed from time to time, to enable us to clean the eye, and apply the necessary remedies for the cure of the conjunctivitis.

2. The second form of ectropion, arising from hypertrophy of the conjunctiva, is often thus produced:—Among aged people the skin of the lids becomes lax, and the puncta no longer fit

closely against the globe, and so the tears are retained in contact with the eye. The lacus lachrymalis being always full of tears, considerable irritation of the mucous membrane is excited, and chronic inflammation and hypertrophy of the conjunctiva are ultimately induced; the thickened mucous membrane then forces the lids away from the eye and ectropion results. The eversion of the lid is usually augmented under these circumstances by inflammation, and ulceration of the skin at the inner angle of the eye, caused by the irritation of the tears constantly flowing over it, and the efforts of the patient to keep the part dry. Another cause of this form of ectropion—brought about, however, in precisely the same way—is a partial paralysis of the fibres of the orbicularis muscle: the lower lid droops away from the eye, the puncta are everted and hypertrophy of the conjunctiva and ectropion follow.

Eversion of the lid occasioned by chronic irritation and thickening of the mucous membrane, whether arising from the causes now mentioned or any other—as, for instance, tinea ciliaris—in course of time not only induces a permanent eversion of the tarsal cartilage, but also a lengthening of the lid from side to side. The exposed mucous membrane becomes converted into a thickened reddish mass, or may become dry and assume the characters of skin. The disease is, therefore, not only unsightly, but since the patient is unable to close his eye, dust and dirt get lodged on the cornea, and these, together with the contact of the air produce vascular opacity, and it may be destructive ulceration in the cornea, or even changes in the deeper structures of the eye.

Treatment.—In the first instance, in slight cases, we may try the effects of the red precipitate ointment, applied twice a day over the ectropion and along the margin of the lids. If this does not succeed, cocaine having been applied several times to the eye, the ectropion should be everted by traction on the neighbouring skin, and the conjunctiva having been completely dried, a glass rod, wetted with nitric acid should be drawn carefully along the surface of a limited portion of the mucous membrane, parallel to and about the eighth of an inch distant from the margin of the lid. Great care is necessary merely to damp the rod with the acid, otherwise it will spread over the conjunctiva and do no end of harm. Immediately after this application, a stream of water must

be syringed over the part, so as to wash away the excess of nitric acid remaining on the conjunctiva; and sweet oil having been smeared over the surface, the lid is to be kept closed with a pad and bandage. It will generally be necessary to repeat this application once a week for a month, before the desired result will be attained. Sufficient contraction gradually takes place in the hypertrophied tissues to overcome the ectropion, and restore the lid to its normal position; it may be necessary subsequently to slit open the canaliculus.

In old-standing cases, caustics fail, and it then becomes necessary to excise an elliptical portion of the everted conjunctiva, extending along the breadth of the lid, and parallel to its ciliary margin. The amount of conjunctiva to be removed must depend upon the extent of the displacement; in fact, we excise a fold of the mucous membrane in ectropion in precisely the same manner as we remove a portion of skin in certain cases of entropion; all that is required is, when the wound heals and contracts, that the everted lid shall be drawn back into apposition with the eyeball. After the operation, the eye must be closed with a pad and bandage. But in these cases of ectropion, the tarsal cartilage is apt to become elongated from side to side. In this condition of the parts, it would be useless simply to excise a portion of the conjunctiva; to correct this malposition one of the following operations may be resorted to:—

Excise with a bistoury, or strong scissors, an elliptical piece of the conjunctiva, proportionate to the degree of hypertrophy of the mucous membrane, parallel to the inferior (become superior) margin of the tarsal cartilage, and one line distant from it. Then pass three ligatures through the lips of the resulting wound, using a curved needle with a large eye; both ends of each thread are passed together through the eye of the needle, which is guided along the nail of the left index finger, between the eyeball and the eyelid, made to penetrate the conjunctiva at its angle of reflection from the globe, and brought out as high up as possible through the skin. The two ends of each ligature are then crossed over a bit of plaster, and tied close under the arch of the orbit, as shown in the annexed figure (9). Boracic acid compresses must subsequently be employed, and the ligatures removed at the end of three days.

If the ectropion be accompanied by no great shortening of the integument, and if the margin of the lid is in other respects normal, the excision of a triangular flap, from the outer portion of the lid, and closing the wound by sutures, is generally sufficient. For this purpose the edges of the lids in the outer commissure are slit up with a scalpel. Then a triangular flap of integument is dissected away, and the edges of the wound are united by suture, and a protective bandage applied until adhesion has occurred. In order to lessen the stretching, it is well, before closing the wound, to separate the inner edge of the skin from the tissue beneath for a little distance, particularly if the subcutaneous tissue

FIG. 10.

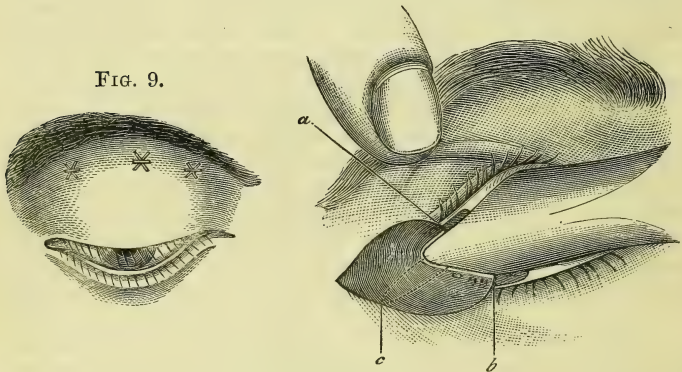


FIG. 9.

is somewhat thickened from previous irritation. It is also advisable to diminish the tension of the parts by keeping them drawn together by strips of plaster.

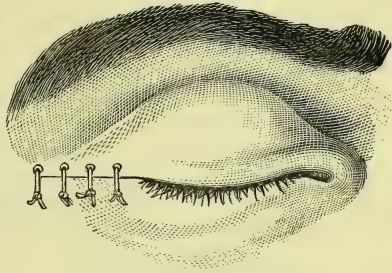
If we wish to secure great elevation of the lid and of the commissure the following proceeding may be adopted:--

The operator (Fig. 10) pushes a small horn spatula under the outer commissure, lifts it up from the globe, and splits it into two layers, first thrusting in a broad, lance-shaped knife immediately in front of the fascia tarso-orbitalis, and then enlarging the wound with a scalpel on both lids, up to the vertical boundary lines *a* and *b*.

When this intra-marginal splitting is done sufficiently, the lower and then the upper margin of the lid are pared in a

direction inward from the vertical boundary line, for about one-half to three-quarters of a line by a horizontal incision. The whole breadth of this incision falls behind the lashes (Fig. 11). The horizontal incision is to be made at a greater or less distance from the edge of the lid, according as the outer commissure is to be more or less elevated; but it should always be so made that the two run together at an acute angle. The integument is dissected up, and the wound closed by three or four sutures. The first suture is placed close to the vertical boundary line (Fig. 11).

FIG. 11.



In order to lessen the tension, strips of adhesive plaster as well as the protective bandage may be used. These are fastened on the cheeks and forehead, drawing up the integument lying between them.

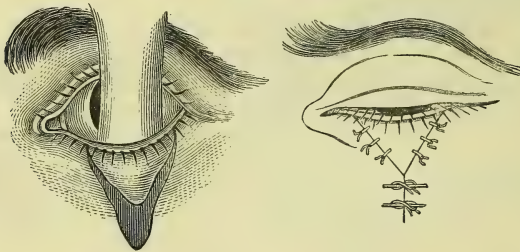
Ectropion, arising from the contraction of a cicatrix of the skin, is often a most troublesome deformity to overcome. It matters not if the cicatrix has been formed by a wound or a burn, if it involves the skin of the lid it is almost sure to be followed by ectropion and its consequences. The treatment to be pursued in these cases consists in freeing the lid from the contracting bands of the cicatrix. In slight cases it may only be necessary to make an incision through the integument, parallel to the ciliary margin of the lid, and of such an extent as will enable us, by dissecting the subcutaneous tissue from the cartilage, to separate it from the adhering cicatrix. The lid, being freed in this way from the cicatricial tissue, may be closed, and should be kept in this constrained position by passing a suture through its edge, and tying it down to a fold of the skin of the cheek, or forehead, according as the upper or lower lid has been operated on; or in some cases, a well applied pad and bandage will answer the same purpose.

In more severe cases, supposing the upper lid to be everted and bound down to the supra-orbital ridge, two converging incisions should be made through the skin, from over the

angles of the eye upwards to a point where they meet (Fig. 12), somewhat more than an inch from the adherent ciliary margin of the eyelid. By pressing down the triangular flap thus made, and cutting all opposing bridles of cellular tissue, but without separating the flap from the subjacent parts, we should be able to bring down the eyelid nearly into its natural situation, by the mere stretching of the subjacent cellular tissue. A piece of the everted conjunctiva is to be snipped off; the edges of the gap left by drawing down the flap are now to be brought together by sutures, and the eyelid retained in its proper place by plasters, and a compress and bandage.

A cicatrix may be separated from the lid, and a piece of healthy integument, from the cheek or forehead, transplanted into its place. Of the operation proposed, that known as Dieffenbach's is generally to be preferred, though it is almost

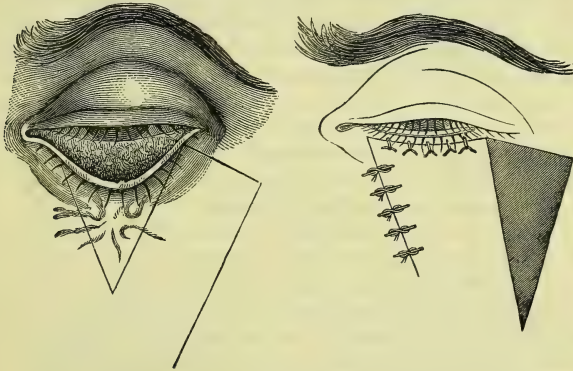
FIG. 12.



impossible to lay down any rules strictly applicable to all instances; each case requiring some special modification, which the skill and ingenuity of the surgeon must supply at the time of the operation. Dieffenbach's operation is performed as follows:—The cicatrix is first to be dissected away, so as to leave a triangular wound having its base towards the margin of the lid, the line of the ciliary border of the lid and tarsal cartilage being, if possible, preserved. But if these have been destroyed, the conjunctiva alone remaining, it is to be dissected out and laid over the eyeball. The surgeon then makes an incision (Fig. 13), through the sound skin and subcutaneous tissues, extending from one or other of the angles of the base of the triangular wound already made, according to the situation of the cicatrix. From the outer extremity of this incision, a second one is to be carried parallel

to the edge of the triangular wound; the enclosed flap is then to be dissected from off the subcutaneous tissue, and being transposed, is to be fitted into the gap left by the cicatrix; the margin of the transplanted skin is then to be carefully united to the edges of this wound by fine sutures. Boracic dressing should be subsequently applied, and the part kept at rest. The flap may be formed, half from one side of the cicatrix, and half from the other side, but under any circumstances it must be considerably larger than the gap it is intended to fill; in fact, one is hardly likely to err in making too large a flap, but mistakes are often made in transplanting too small a portion of skin.

FIG. 13.



TRICHIASIS, OR INVERSION OF THE CILIA, sometimes follows neglected cases of conjunctivitis, or tinea tarsi. Occasionally only a few isolated eyelashes are incurved, the remainder retaining their normal position; at other times the whole of the cilia, or all of those growing from one part of the eyelid are affected; but under any circumstances the result is the same, the irritation caused by the cilia rubbing against the surface of the eyeball induces conjunctivitis and keratitis, and, in time, opacity of the cornea and loss of sight. Entropion differs from trichiasis, therefore, in that the ciliary margin of the lid in the former affection is curved inwards, and with it the cilia, whereas in trichiasis the lid may be healthy, but the cilia are inverted against the surface of the eyeball.

The Symptoms to which trichiasis gives rise will depend upon the extent of the disease, and the situation of the inverted cilia; a few of the eyelashes rubbing against the eyeball, at the outer angle of the eye, will not cause so much inconvenience to the patient as a single hair, if inverted against the cornea. Cases of trichiasis, if left to themselves, will, in the first instance, give rise to persistent conjunctivitis, followed by haziness, and ultimately vascular opacity of the cornea. If only a few of the cilia are incurved, they are apt to be overlooked, chronic conjunctivitis being the prominent symptom which first attracts our attention. Immediately, however, that the lid is everted, so as to expose its ciliary margin, the ingrowing eyelashes will be detected; it is advisable for this reason, in all cases of persistent conjunctivitis, to examine the margin of the lids, and notice the condition of the cilia. In ordinary chronic conjunctivitis the eye is irritable, and the patient, by constantly rubbing it, sometimes causes one or more of the eyelashes to become inverted, and this contributes to keep up the inflammation. In a case of this kind, astringent lotions will be useless unless the offending cilia be removed. It occasionally happens that people are born with a double row of eyelashes; the inner ones, under these circumstances are often inverted.

The Treatment to be adopted in cases of trichiasis depends much upon the extent of the disease; if only a few of the cilia are incurved, the offending hairs should be seized one by one with a pair of forceps, and pulled out from their follicles. It is necessary to be careful not to break off the cilia, or the stiff ends left in the eyelid will, by rubbing against the cornea, do more harm than the entire hair would have done. Each cilium must therefore be seized close to the margin of the lid, and slowly and cautiously pulled out, root and all. Unfortunately we cannot extract the hair bulbs in this way, and the consequence is, that another eyelash speedily springs up in place of the one we have removed, and usually takes the direction of its predecessor,—so that if extraction be alone resorted to, it is constantly necessary to watch for the production of new eyelashes in the track of the old ones.

The most effective way of dealing with inverted eyelashes when they are few in number, and of considerable size, is to adopt the method advocated by Celsus, and described as follows by Dr. Argyll Robertson:—

The principle of the operation consists essentially in causing

the offending eyelashes to be mechanically turned away from the eye, and made to grow more or less in the proper direction by making them pass under a narrow bridge of skin. The following is the method of performing the operation:—A fine curved needle has the two extremities of a waxed silk ligature (or hair, as Celsus directs) passed through its eye. The needle, being firmly grasped by suitable forceps, is then passed through a narrow fold of skin at the very margin of

FIG. 14.

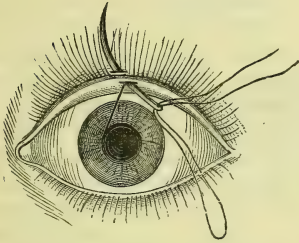


FIG. 15.

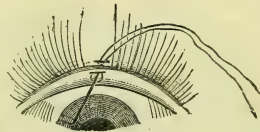
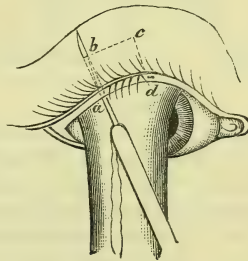
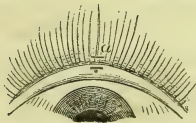


FIG. 17.

FIG. 16.



the lid, close to one of the inverted eyelashes. The point of introduction should be external to the point of emergence of the eyelash, but as close to it as possible: and the needle should be brought out after passing about $\frac{3}{4}$ " or 1" under the skin (Fig. 14). The needle and ligature should be drawn through until a small loop alone remains, when, by means of a fine pair of forceps, the eyelash is passed through the loop (Fig. 15). Traction is then made on the ligature, and the loop with the entangled eyelash is drawn through the tunnel

in the skin (Fig. 16). The other misdirected eyelashes are similarly treated.

Very little irritation follows this operation, and no special after-treatment is necessary. The patient, however, must be warned against touching or rubbing the eyelashes for twenty-four hours after the operation, as he might thus force the eyelashes back out of their new channel. Three or four cilia may be treated in this way with success; but in old-standing cases, in which, perhaps, the whole of the eyelashes are incurved, or those of the outer or inner half of the lid are affected, it will be necessary to resort to other means.

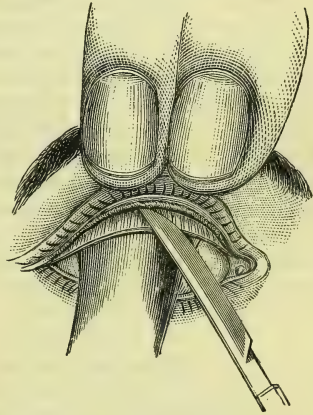
The whole of the cilia may have to be removed, together with their bulbs, as described in cases of Entropion, page 41, or a portion or the whole of the tarsal cartilage may have to be grooved above the position of the inverted cilia, in order that they may be restored to their normal position. This operation we have found to be particularly useful when the outer half of the cilia are diseased. Occasionally the excision of a portion of the skin of the lid will evert the palpebral margin sufficiently to prevent the incurved eyelashes from rubbing against the eye; but there can be no doubt, in severe cases, that any proceeding which actually destroys the eyelash and its bulb is to be preferred to an operation which merely everts the palpebral margin of the lid,—trichiasis, as before remarked, not being a disease simply of the eyelid, but of the eyelashes.

Of the operative proceedings intended to accomplish this object, the following is the best (Fig. 17):—A needle is to be threaded with fine silk, and entered between the inner and outer margins of the border of the lid, *a*, and made to pierce the skin a little above the ciliary margin, *b*. The thread is drawn through, and the needle caused to re-enter at the last orifice, *b*, and made to run parallel with the border of the lid, for the space in which the cilia maintain the wrong direction (to *c*). The thread is again to be pulled through, and the needle again entered at the last point of emergence, and directed vertically till the point reappears between the edges of the border of the lid, *d*. The two ends are then to be tied, and the thread allowed to cut its way out. The suppuration excited thoroughly destroys the bulbs of the offending cilia, and no further trouble is experienced.

In the more inveterate cases of trichiasis, a kind of trans-

plantation of the outer lip of the lid, and the hair follicles beneath, is of value. It is better to perform most of these operations while the patient is under the influence of an anæsthetic, on account of the great pain, and because of their tediousness. An assistant, who at the same time holds the head, places a horn spatula under the lid, raises it up from the globe, and causes the edge of the lid to be somewhat everted from the spatula. Then the edge of the lid is divided into layers, for the depth of two lines, with a delicate scalpel (Fig. 18), the incision not being continued inwards as far as the lachrymal punctum. The posterior layer contains the conjunctiva, with the cartilage and canals of the tarsal glands, and the anterior includes the remaining structures, with all the hair follicles.

FIG. 18.



The incision should, therefore be made close to the surface of the cartilage. Then a second incision is made, one and a half to two lines above, and parallel to the outer lip, completely through the anterior layer, down to the cartilage, and in such a manner that the two ends of the wound extend beyond the ends of the first incision. This layer is thus changed into a kind of bridge, to whose posterior surface the hair follicles are attached, and which is only connected to the lids by the two extremities. When this bridge has been formed, a crescentic incision is made, beginning at the ends of the last incision, through the integument. This is seized with the forceps, and carefully dissected up, without injury to the orbicularis muscle. The size of this flap should be the larger, and have a greater vertical diameter, in proportion as the hairs are turned inward, and the more the skin is relaxed and wrinkled. The edge of the crescentic incision, and the bridge of skin containing the cilia, are now to be brought together by means of sutures; under the traction of these sutures the direction of the hairs becomes horizontal or is even turned

toward the orbital border. The sutures should be removed on the third day.

ADHESIONS OF THE EYELIDS.—The ciliary margins of the eyelids sometimes become united either wholly or in part; this may arise from a congenital defect, or from any cause which gives rise to abrasion of the skin along the free margin of the lids, their raw surfaces growing together, and rendering the eye useless for all practical purposes. This is, however, a rare consequence of disease: it far more commonly follows chemical or mechanical injuries of the parts.

Treatment.—When the margins of the lids grow together, whether from congenital defect or from injury, a director should be passed behind the adhesions, and they should be slit through with a knife or pair of scissors. It will be necessary to keep the lids separated from one another until the edges of the wound have cicatrized. Unfortunately, the majority of these cases are complicated with adhesions between the palpebral and orbital portions of the conjunctiva, which it is most difficult to cure. Adhesions of this kind are called *symblepharon*, and are described under the head of diseases of the conjunctiva.

PARALYSIS AND SPASM OF THE EYELIDS.

PTOSIS, OR FALLING OF THE EYELID.—An inability to raise the upper eyelid may occur in one or both eyes from any of the following causes: first, it may be a congenital defect; secondly, it may depend upon a relaxed state of the skin and tissues of the lids; thirdly, ptosis may arise from an injury to the levator palpebræ muscle; fourthly, it may occur from a defect in the nervous apparatus supplying that muscle.

From whatever cause arising, a patient suffering from ptosis is unable, by a voluntary effort, to raise the upper lid of the affected eye, but in other respects his vision, and in fact the ocular apparatus, may be perfect. If the ptosis is complete, the upper lid, by hanging over the cornea, obstructs the passage of light to the eye; and hence, for all practical purposes, the sight is destroyed till the obstruction is removed.

In congenital ptosis both eyelids are usually equally affected. For its relief, an elliptical portion of the skin of

the lid may be removed, the edges of the wound being brought together with sutures, and the shortening of the lid thus produced may enable the patient to raise it sufficiently to admit the rays of light to enter the eye; but the muscular fibres of the levator palpebræ are almost entirely wanting, and in spite of the above described operation, the lid usually droops over the pupil, interfering very much with the perfection of vision. In a case of this description it may be necessary to elongate the pupil downwards.

Ptosis, arising from elongation of the skin and connective tissue of the lids, is a more manageable affection; it seldom occurs except among old people, or those who have suffered from long continued conjunctivitis. In these cases the connective tissue and skin have been stretched to cover the hypertrophied mucous membrane, while the fibres of the levator palpebræ are atrophied from senile degeneration. The contractile power of the levator is seldom, however, completely destroyed; and considerable benefit, therefore, frequently arises from excising an elliptical portion of the skin, allowing the wound to cicatrize, and in contracting, to shorten the lid. The state of the conjunctiva must also be attended to, for in the majority of these cases it is hypertrophied, and, in all probability, will be improved by the application of the dilute red mercurial ointment to its surface twice a day.

Wounds and injuries of the levator palpebræ, by dividing or destroying the contractile power of the muscle, are likely to induce ptosis; we may endeavour to rectify this by excising a portion of the skin of the lid; but the loss of power in the muscle will prove a serious obstacle to any permanent amendment. If, as is most probable in cases of this kind, only one eye is affected, it is advisable to elongate the pupil downwards, endeavouring by this means to restore binocular vision.

Ptosis, arising from paralysis of the levator palpebræ, appears occasionally to be the result of an injury to one or more branches of the fifth nerve, probably affecting the motor nerve by reflex action from the quadrigeminal bodies. The same result may follow malarious peripheral neuritis of the supra-orbital nerve. In these cases the optic nerve and recti muscles are more or less affected, and their functions impaired. In those more complicated cases, however, where the ptosis seems to depend on a primary affection of the third pair of nerves or nervous centre, we

may have to exert all our skill in referring the malady to its true cause, and adapting our remedies to the special requirements of the case. We shall do well to bear in mind that syphilis in its various phases is a prolific source of disease of this kind, both in the sheaths of the nerves and in the brain itself; nor must we forget that this form of ptosis may be due to tumours, to limited apoplexy, and many other obscure affections to which the nervous centres are liable.

In some instances, paralysis of the levator palpebræ is developed suddenly, apparently from the effects of cold. The patient has probably been exposed to a bleak wind, or slept in a damp bed, and the next morning on rising, finds that he cannot raise one or other of his eyelids. Many of these cases undoubtedly recover, and if the patient is otherwise in good health, our prognosis is generally favourable, but it may take several months before the muscle regains its power. In some instances progressive atrophy of the optic nerve supervenes; under these circumstances it is more than probable that the disease, though attributed to cold or rheumatism, has been in progress for a considerable time, and depends either upon embolism of some of the smaller vessels, or fatty changes in the central axis of the nerve, or nervous centre.

In the earlier stages of ptosis, if of malarious origin, we must try the effect of arsenic combined with iron and strychnine, and other reputed remedies for the relief of malaria. We may also employ counter-irritation by an issue, or blisters to the temples, as well as administer nervine tonics, iodide of potassium, and so forth, according to circumstances, not neglecting due attention to the condition of the alimentary canal and its secretions. In other cases of ptosis, depending for instance on cerebral disease, the wasted muscle may be best excited by means of Faradization.

In employing electro-magnetism for the relief of ptosis, the positive pole may be applied below the ear, and a small piece of moist sponge, connected with the negative pole, over the skin of the closed eyelid. The excitation should be weak, and never continued for more than a few minutes at each sitting. If this mode of treatment is likely to prove beneficial, the amendment generally becomes apparent very speedily. Unfortunately, this form of paralysis is often

slow in its development, and being attended by no urgent symptoms, the patient may fail to apply for relief until irreparable damage has been done to the muscles.

Should the ptosis be sufficient to interfere with vision and no improvement takes place with the above treatment, an attempt may be made to unite the tissue of the lid with the occipito-frontalis muscle, many different operations have been suggested to produce this result; that of Snellen consists in entering a strong needle with one end of a good thick suture attached, about 4mm. from the edge of the lid, the needle must be passed deeply as nearly as possible down to the tarsal cartilage; it should then be directed upwards and brought out about one inch above the eyebrow, keeping as near as one can to the bone over the brow; the needle is next to be threaded to the other end of the suture, passed in at the same opening in the skin of the lid, and carried up subcutaneously to the opening above the brow, and the two ends tied over a piece of drainage tube; usually three of these sutures are necessary: one in the centre of the lid, and one at either end; each suture contains a layer of tissue which is gradually cut through, leaving a subcutaneous cicatrix which involves the muscular tissue of the lid with the aponeurosis of the occipito-frontalis, this, besides giving some power over the lid by means of the last-mentioned muscle, also shortens the tissue by the cicatricial contraction that takes place.

In our hands the best results have been obtained, by first removing an elliptical piece of skin from the upper eyelid with T forceps, then attaching the occipito-frontalis directly to the lid insertion of the levator palpebræ by means of cat-gut sutures, finally closing the wound in the lid.

Of course no operation can place the patient in the normal condition if the loss of the power in the levator palpebræ is complete; we must be satisfied if the cornea can be completely uncovered, and the drooping appearance improved.

PARALYSIS OF THE ORBICULARIS PALPEBRARUM is less frequently met with than ptosis. When it exists, the patient may be able to open the affected eyelid, but is unable to close it completely; and the cornea, being more or less constantly exposed, particles of dust settle upon it, it becomes irritated, and ulceration is apt to occur. The orbicularis is seldom paralyzed alone; in almost all cases the other

muscles of the same side of the face, supplied by the seventh nerve, are also affected, the sensation of the part remaining perfect.

The most common causes of this "Bell's palsy," as it is called, are exposure to cold, mental emotions of various kinds, and traumatic lesions of the nerve; the paralysis occurs suddenly. In other cases the affection depends on some syphilitic affection of the facial nerve, or of the bony wall of the aqueductus Fallopii; it may be due to otitis, terminating in necrosis of the petrous portion of the temporal bone. In some few instances the paralysis is of central origin. M. Trousseau, in referring to such cases, remarks, that the "orbicularis palpebrarum is never paralyzed to the same extent in lesions of the hemispheres of the brain, as it is in disease of the facial nerve; hence, if a hemiplegic patient is asked to shut his eyes, he does it completely enough to hide the globe of the eye, whilst the eyeball remains uncovered in cases of paralysis of the seventh pair." Consecutive ulceration of the cornea is apt to occur, and the eye may thus be destroyed; consequently it is advisable, under these circumstances, to keep the eye closed with a pad and bandage until the orbicularis has regained its power. Troublesome lachrymation is present from an early stage of the affection, the lower lid no longer forms a canal for the tears; the puncta, moreover, in consequence of the paralysis of the orbicularis, cannot assume their normal position, but drop away from the eyeball, leaving the tears to trickle down over the corner of the eye. Some few cases of facial paralysis recover of themselves; perhaps one of the best tests we possess as to the probable result of a case, is to ascertain how far the affected muscle responds to the electro-magnetic current. If no contraction of the palsied muscle takes place on being thus stimulated, it is almost a certain sign of the incurable nature of the disease.

Although facial paralysis may get well of itself, the cure may be sometimes hastened by counter-irritation, and exhibition of strychnine, veratrum, and the use of Faradization. In instances of a syphilitic, or apparently malarious origin, while employing electricity to excite the muscle into action, we should never fail to administer iodide of potassium, quinine, and other drugs, which appear sometimes to exercise a direct influence on these affections.

BLEPHAROSPASMUS, or spasmodic closure of the eyelids, is an

affection of the orbicularis. This muscle is especially liable to spasmodic disorders, the levator palpebræ being but rarely affected. In certain cases of spasm of the eyelids, the contractions are of a clonic kind, so that the patient is constantly winking; or if a portion only of the muscle is involved, a limited twitching is produced. This affection is most common among weak and irritable subjects, and, though unpleasant enough, is generally of no great moment, being readily overcome by a tonic plan of treatment, and the use of a stimulating liniment. There are cases, however, in which such clonic contractions of the lids become a permanent disorder, and these are more troublesome to friends than to the patient himself, who becomes unconscious of, or indifferent, to them.

A far more serious form of blepharospasm is that in which the contractions are of a tonic kind, and either intermittent or continuous. Even when intermittent, the disease is frequently most distressing, and attended with absolute danger to the patient; for he may be seized with a violent spasm of the lids at any moment, entirely destroying his sight for the time; and supposing that he happens to be crossing a crowded street at this particular moment, he runs a risk of being thrown down and run over. Moreover, the affection is in other respects a most painful one, interfering as it does with work, and rendering the patient unfit for all useful employment.

Causes.—Blepharospasm depends upon irritation reflected from the sensitive to the motor nerve. M. Wecker describes this affection under three heads, according to the source of the irritation:—Firstly, the traumatic; secondly, that depending on disease of the cornea or conjunctiva; and thirdly, upon an affection involving all the branches of the facial nerve.

In the first class of cases, the spasm is generally determined by the presence of a foreign body on the cornea or conjunctiva, the irritation of the branches of the fifth nerve, which is thus produced, being reflected through the seventh or motor nerve to the muscle it supplies. At first the spasm is intermittent, and confined to the orbicularis; but eventually it becomes continuous, and may spread to all the muscles of the face, especially if an attempt be made to open the eyelids by force. At first, perhaps, one eye only is affected, but the other may subsequently become involved.

In the second class of cases, the blepharospasm may be caused by the irritation arising from pustular conjunctivitis, or an ulcer of the cornea. The abnormal reflex action thus established may persist even after the cause of it is removed. To this class we must refer the spasmodic closure of the eyelids in so-called strumous ophthalmia.

The third class includes cases of neuralgic tic of the face, in which the morbid condition of the fifth nerve, especially its supra-orbital branch, is propagated by reflex action to the seventh pair, causing spasm of the orbicularis. Malaria, rheumatism, sudden exposure to cold, irritation of the nerve by bony growths in its passage through the skull, or faulty digestion, may be mentioned as some of the most common causes of this form of blepharospasm.

The Treatment will depend upon the nature of the disease. If the spasm is caused by the presence of a foreign body in the eye, the offending particle must be removed as soon as possible; and so with affections of the conjunctiva, we must endeavour to cure the local disease. But in the third class of cases, we should try to ascertain which of the branches of the fifth nerve is principally involved, and, as a guide to its discovery, we may exert pressure at different points of the surface—for example, over the exit of the supra-orbital nerve, and notice if it influences the spasm of the lid; or, again, we may examine in the same way the inferior dental nerve at the dental foramen. If we can thus discover the point of departure of the irritation among the branches of the fifth, we may by division of the nerve, interrupt the chain of nervous actions on which the spasm of the orbicularis depends. It may be necessary to divide the nerves on both sides of the face; and at first the beneficial effect of the operation may not be very apparent, but gradually the spasm passes off, to the great relief of the patient. Unfortunately, after an apparent cure has been effected in this way, the disease may return. Among other remedies which may be usefully employed for the relief of blepharospasm, are electricity, the continuous current being used; and also the subcutaneous injection of morphia. These should always be tried before we have recourse to surgical interference. The injection should be made, in the first instance, over the branches of the supra-orbital nerve.

We should never omit to make a careful inspection of the teeth in this form of disease; for the extraction of a carious

tooth may remove the blepharospasm. In like manner, the cicatricial tissue of a wound, involving branches of the fifth nerve, may have to be dissected out to relieve the irritation it occasions in the sentient fibres. In fact, careful consideration and a judicious adaptation of remedies will be called for, to enable us to comprehend and successfully meet the various forms of this very troublesome complaint. Some cases of blepharospasm are due simply to a bad habit acquired unconsciously by the patient; such cases are relieved, and we have seen them cured, by keeping the eye which is not affected closed, obliging the patient in this way to exercise the eye surrounded by the spasmodically affected muscles; these, after a time, discover the comfort of rest, and learn to behave themselves in an orderly manner.

CHAPTER III.

DISEASES OF THE LACHRYMAL APPARATUS.

The Lachrymal Gland—Acute and Chronic Inflammation—Hypertrophy—Sarcoma and Carcinoma—Lachrymal Cysts—Displacement and obstruction of the puncta and canaliculi—Epiphora—Inflammation of the sac—Obstruction of the nasal duct—Lachrymal cysts and fistula.

THE LACHRYMAL APPARATUS consists of the lachrymal gland and its ducts; and the puncta, canaliculi, lachrymal sac, and nasal duct.

The lachrymal gland secretes the tears; it is situated in the hollow on the inner side of the external angular process of the frontal bone, and is somewhat similar in shape and size to an almond; its ducts are very small, some six or eight in number, and open on the inner surface of the upper eyelid near the external canthus.

The lachrymal gland is occasionally the seat of inflammation, which may be either acute or chronic; the acute variety is very rare; when it does occur it is accompanied with pain, heat, swelling and œdema of the lids; sometimes there is displacement of the eyeball. The chronic form is occasionally seen among people affected with scrofula. The secluded position of this gland preserves it from injuries by direct violence; on the other hand, it favours the propagation of inflammatory action from the gland to the connective tissue around; and it is thus sometimes impossible to distinguish a case of inflammation of the gland from one of general inflammation of the cellular tissue of the orbit.

SYMPTOMS.—In cases of acute inflammation of the gland the patient complains of a severe darting or shooting pain in the orbit, extending over the forehead and side of the head;

the conjunctiva and eyelids become intensely congested and much swollen, the globe of the eye being pressed downwards and forwards, or inwards and backwards. These symptoms are usually accompanied with fever. If the inflammatory action advances, fluctuation will soon be felt, generally at the upper and outer part of the orbit, and after a time matter bursts through one or more openings in the upper eyelid, and the abscess having discharged its contents, the swelling and inflammation gradually subside. It sometimes happens, however, that the periosteum, and subsequently the bone in the immediate vicinity of the gland, becomes involved, in which case a fistula forms, and remains open so long as the diseased action in the bone continues.

Treatment.—In acute inflammation, we may endeavour, in the early stages of the disease, to prevent suppuration by leeches and the application of iced belladonna compresses to the part; subsequently, if suppuration appears inevitable, hot poultices should be applied and changed every two hours. The earlier an abscess in this situation is opened antiseptically the better: a free incision must therefore be made in the gland, as soon as fluctuation can be detected, and a drainage tube introduced.

HYPERTROPHY OF THE LACHRYMAL GLAND is an affection almost peculiar to young people. Probably one of the first symptoms of which the patient complains is a certain amount of double vision caused by the enlarged gland displacing the eyeball. On examination, the hypertrophied gland, which may grow to a considerable size, will be felt behind the outer part of the upper eyelid, and might be mistaken for a node or a sarcoma growing from the periosteum of the orbit, but it is painless, nodular, and increases in bulk with remarkable slowness. In the course of time the glandular swelling may gradually disappear, or it may suppurate, and a chronic abscess result, the discharge from which frequently lasts for months, causing the patient much annoyance, but little or no pain.

In treating cases of hypertrophy of the lachrymal gland we must depend chiefly upon good food, fresh air, cod liver oil, and the iodide of iron, in the hope of promoting the absorption of the tumour. Cases arise in which it may seem advisable to excise the gland. If suppuration should occur, we must open the abscess as soon as possible.

CANCEROUS GROWTHS.—This gland is occasionally affected by sarcomatous or carcinomatous growths. The former is characterised by more or less displacement of the eyeball downwards and backwards, and after a time the enlarged gland may be distinctly felt behind the outer part of the upper lid; its growth is painless and usually slow. Should carcinomatous disease become developed in this situation, we shall, in addition to the above symptoms, have those super-added which are common to malignant disease in other parts of the body.

LACHRYMAL CYSTS (Dacryops) commence as small tumours in the upper and outer part of the eyelid, extending backwards, beneath the border of the orbit, towards the lachrymal gland. If the lid be drawn upwards, and pressure be simultaneously applied in a downward and inward direction, a tense, elastic, fluctuating swelling instantly starts out between the eyeball and the inner surface of the eyelid. As the tumour increases in size, the movements of the eye become restricted, and it may even cause exophthalmos. If the patient strains, such as by crying, the tumour suddenly enlarges; this is a characteristic feature of the affection. This rare form of disease depends for the most part upon obstruction of one or more of the lachrymal ducts, in consequence of a neglected abscess or wound of the eyelid. The tears, being prevented from escaping, collect behind the point of stricture and cause the dilatation of the duct above described.

Treatment.—A permanent opening must be made into the cyst from the inner surface of the eyelid, the tears can then pass away over the eye. If the opening is made externally through the skin of the eyelid, a troublesome fistula may result.

FISTULÆ OF THE LACHRYMAL GLAND occasionally form as the result of an abscess or injury. A fistulous opening leading to the lachrymal gland having formed, it may be in the skin of the upper eyelid, a clear fluid constantly drains away through it over the skin, and a probe may be passed through the fistula in the direction of the lachrymal gland. In a case of this kind it is advisable to pass a probe along the course of the fistula, and then, having everted the eyelid, to cut down through the conjunctiva on to the probe, and in this way create another fistulous opening on the palpebral conjunctiva, so as to conduct the lachrymal secretion to its proper desti-

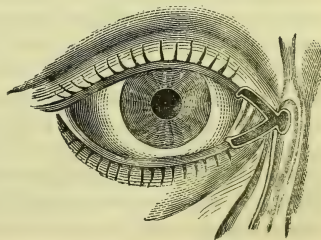
nation. The galvanic cautery should then be applied to the mouth of the fistulous opening on the outer surface of the eyelid, in the hope that the inflammatory action thus excited may, on the separation of the slough caused by the cautery, close the external fistula. All other means of treatment having failed, it may be necessary to excise the lachrymal gland in order to cure the fistula.

Excision of the Lachrymal Gland is thus performed:—A transverse incision of three-fourths of an inch in length should be made into the orbit, over the upper and outer third of the orbital ridge; the external commissure of the lids may then be divided; and by connecting the outer ends of the two incisions a triangular flap is formed, which is thrown up. The lachrymal gland is thus exposed, secured by a sharp hook, drawn forwards, and removed. The edges of the wound are then united by sutures. The linear scar of the incision is subsequently inappreciable, being lost in the folds of the upper eyelid. If the eyeball has been forced outwards by the morbid growth, a pad should be applied over the lids subsequently to the operation, so as to retain the globe in its natural position till the tissues around it have retracted to their normal condition. It is somewhat curious that when the gland is removed, the eye does not appear to be inconvenienced by a lack of moisture, as might be expected.

The lachrymal secretion passes through the puncta, the canaliculi, the lachrymal sac, and the nasal duct into the nose. Derangement of one of these parts is exceedingly common.

DISPLACEMENT AND OBSTRUCTION OF THE PUNCTA.—In the healthy eye, the lachrymal puncta are in contact with the eyeball, and cannot therefore be seen unless the eyelids are everted. When the eye is closed, the puncta are situated in the lacus lachrymalis, so that the secretion from the surface of the conjunctiva, whether the person is sleeping or waking, can always drain away through the puncta into the canaliculi, lachrymal sac, nasal duct, and so down into the nose (Fig. 19). Any cause which displaces the

FIG. 19.



puncta, such as facial paralysis, or which obstructs the passage of the tears into the nares, gives rise to an accumulation of the lachrymal secretion in the lacus lachrymalis, which in time overflows, and running down the cheek, causes the patient considerable inconvenience.

Epiphora, or a watery eye, is thus induced, and a tear is left constantly in front of the cornea, which, by interfering with the rays of light in their passage to the eye, renders it necessary for the patient to be perpetually wiping his eye before he can see clearly; and lastly, the prolonged contact of the tears with the surface of the eye gives rise to chronic conjunctivitis and its consequences.

Obstruction of the lachrymal puncta may be either partial or complete—that is, one or both the puncta may be closed, giving rise to symptoms such as we have above described. If in the healthy eye, pressure is made over the lachrymal sac, a drop of fluid may be seen to ooze out through the lachrymal puncta. Should one or both puncta be occluded, fluid cannot be made to regurgitate through the obstructed orifice. Under these circumstances we may find it difficult to pass a probe into the canaliculus.

Treatment.—In cases of congenital deficiency of the puncta, or when it has been completely closed from the effects of a burn or other causes, its position may generally be detected as a small depression near the inner extremity of the palpebral margin. It by no means follows that because the puncta are closed, the canaliculi are also occluded; so that, in some instances of this kind, all that is necessary is to evert the lid; a sharp-pointed probe or other instrument is then to be run through the obstruction in the direction of the canaliculus, the punctum being laid open. If a full-sized lachrymal probe can be passed through the canaliculus into the lachrymal sac, there will be no necessity for any further treatment, beyond the insertion of the instrument through the incision every day, for four or five days, to prevent its edges from uniting. The puncta may not be completely occluded; but they may be so contracted that it is difficult for the lachrymal secretion to find its way through them in sufficient quantities to keep the corner of the eye free from an accumulation of fluid. Under these circumstances, a narrow beak-shaped knife, made for the purpose, may be passed through the punctum, and its inner and upper wall incised, and subsequently kept open as above described.

OBSTRUCTION OF THE CANALICULUS may be permanent or spasmodic. A permanent stricture, whether partial or complete, will give rise to the same symptoms as occlusion of the puncta, and for the most part it arises from a similar cause—namely, chronic inflammation of the mucous membrane. A foreign body, as, for instance, a cilium or calcareous concretion, occasionally closes the canal. Spasmodic stricture of the canaliculus occurs either at the inner or outer opening of the canal, and the watery eye accompanying it may be of an intermittent character, depending on relaxation at one time and spasm at another of the constrictor muscle. There is never the same resistance to the passage of an instrument in cases of this kind through the canaliculus as in instances of permanent stricture.

Treatment.—Unless the obstruction is of some standing, attempts should hardly be made to pass an instrument, as the stricture may arise simply from congestion of the lining membrane of the canal, and astringents will cure it; whereas the injudicious use of a probe, by wounding the mucous membrane, may cause a permanent obstruction. On the other hand, if the patient has complained of symptoms of occlusion of the lachrymal passage for some two or three months, it is better, under any circumstances, to operate at once. Old standing cases of obstruction, from whatever cause they arise, seldom improve under local applications, and the sooner the puncta are enlarged the better.

The eye having been cocanised, an assistant or the surgeon, with the thumb of one hand should evert and draw the lids outward; a beak or probe-pointed knife must be run through the punctum and a short distance along the canaliculus, so as to lay the punctum freely open. The edges of the incision should subsequently be prevented from uniting by passing a probe through the wound every day for a week, after which the channel will remain permanently open, and the lachrymal secretion pass through it into the sac. The line of the incision should be directed inwards, or towards the eye, so that it will be in apposition, otherwise the tears will not be able to find their way into the canal from the surface of the lacus lachrymalis. It is seldom necessary to do more than divide the punctum and the commencement of the canal leading from it.

Supposing, however, we should meet with a case in which stricture of the canaliculus is both complete and permanent,

so that we cannot pass even the finest director along the canaliculus into the sac, it is evident that we must endeavour to effect another passage for the tears, either through the upper canaliculus or from the lacus lachrymalis into the sac, behind the tendo-palpebrarum. The sac having been punctured from this latter direction, the opening must be maintained by passing a probe through it every day, so as to form a fistula between the inner angle of the eye and the lachrymal sac.

ABSCESS OF THE LACHRYMAL SAC is attended with great pain, and often gives rise to fever and considerable constitutional disturbance. ABSCESS of the sac commences as a small, hard, and painful tumour, situated at the inner angle of the eye; as the inflammation advances, the skin covering the sac becomes tense and shining, the swelling extending to the cheek and eyelids, which often become so œdematous that it is impossible to open them. Such a case may resemble one of purulent conjunctivitis, the absence, however, of a purulent discharge from the eye, and the excessively painful spot at its inner angle, sufficiently indicate the nature of the disease. If the inflammatory action runs on unchecked, suppuration takes place, and fluctuation may be felt over the region of the sac; the matter points outwards, and ultimately discharges itself through an opening in the skin. The inflammation then subsides, and the parts may return to their normal condition. But it too often happens, if the disease is allowed to take its course, that it terminates in fistula lachrymalis. This perhaps closes, and an abscess again forms, so that gradually the mucous membrane lining the sac and nasal duct is destroyed, and the passage of tears into the nose is permanently closed. Occasionally caries or necrosis of the lachrymal bone follows as a consequence of an abscess of the lachrymal sac. More frequently, however, complications of the kind are only met with among scrofulous and syphilitic patients.

Treatment.—In the early stages of this affection, it is advisable to paint the skin over the inflamed sac with a strong solution of nitrate of silver, and ice or cold compresses may be constantly applied to the part. If suppuration has commenced, we should at once run a probe-pointed knife through the punctum and canaliculus into the sac. If the abscess cannot be opened in this way, the lids should be separated as far as their swollen state will permit; and a

knife should be thrust into the tear sac, the point of the instrument being entered in the depression existing between the commissure of the lids and the caruncle. In some few instances the swelling of the parts is so great that it is almost impossible to open the abscess by either of the methods above described, and under these circumstances it is necessary to make an incision through the skin directly into the most prominent point of the abscess. In spite, however, of all our care, a fistula may form between the sac and the surface of the skin, through which there is a constant discharge of tears: the skin around the opening becomes thickened and excoriated, and from contraction of the integument ectropion may supervene, adding very much to the patient's discomfort.

FISTULA LACHRYMALIS.—Fistula of the lachrymal sac generally arises from inflammation of the sac and subsequent stricture of the duct. It may occur from injury or other causes, by which a communication is established between the skin and the sac; it is often kept open by obstruction of the nasal duct, the lachrymal secretion passing through the puncta and out through the fistula, instead of into the nose.

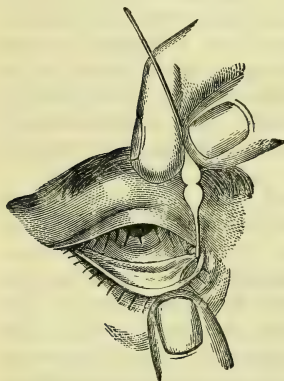
Treatment.—The first and most obvious aim in the treatment is to open the normal passage for the tears into the nose, by dilating the nasal duct. This was formerly done by passing a *style** through the fistula into the duct, and retaining it there; the passage after a time becomes dilated, and the fistula heals. But the difficulty in this method is to retain the style in the duct; and although various ingenious contrivances have been invented for the purpose, they do not appear to answer, and the style has now been almost abandoned. In place of it, the lachrymal sac is opened by slitting up the punctum und canaliculus and gently passing the blade of the knife through the sac along the nasal duct down into the nares.

If the surgeon is thoroughly acquainted with the anatomical relations of these parts, he will have but little difficulty in passing a lachrymal probe through the sac into the nasal duct. The lid should be everted, and by stretching the canal, as before indicated in the operation for stricture, we

* A style is a small piece of silver wire, about one-twentieth of an inch thick, and one and a half inches long, having a neck bent at an obtuse angle with the shaft of the instrument, and terminating in a head.

avoid the risk of forcing a fold of the mucous membrane before the point of the probe, which would prevent the instrument from entering the nasal sac. The probe is then passed horizontally along the opened canaliculus until its extremity reaches the inner bony wall of the sac. The direction of the

FIG. 20.



instrument is then turned vertically, as shown in Fig. 20, and gently passed down through the sac, its point being then directed a little outwards and forwards, it passes into the nasal duct and so reaches the nose. If the probe is arrested at the point where the canals coalesce, and join the sac, the fact may be known by noticing that the skin near the tendo-oculi is moved when the probe is moved, and an elastic resistance is experienced; whereas, if the probe has entered the sac, it reaches the inner bony wall, and the skin is motionless. If we find an obstruction

of this kind preventing the probe from entering the duct, the instrument must be withdrawn, or its point turned in different directions until the probe enters the duct; but this is hardly likely to be the case if the blade of the knife has previously passed along the canal.

The size of the probe to be employed will vary with the nature and extent of the obstruction it has to overcome. As soon as the end of the probe touches the mucous membrane of the nose, the patient feels it there, so that there can be no mistake as to the passage of the instrument. We need hardly remark that it is necessary to handle the instrument lightly when endeavouring to pass it through a stricture in the nasal canal, otherwise we are likely to lacerate the mucous membrane, or, it may be, run the probe through the bony wall of the canal. In the case of stricture of the sac or nasal duct, complicated with a lachrymal fistula, the probe should, if possible, be passed for a time through the duct about twice a week. The natural passage of the tears being thus restored, the fistula will probably heal of itself.

It often happens, however, that our efforts to restore the natural channel for the tears are ineffectual, and consequently

the fistula remains open, to the great annoyance of the patient. To remedy this state of things, three methods of procedure are open to the surgeon—1st, the introduction of a style; 2nd, the obliteration of the lachrymal sac; and 3rd, removal of the lachrymal gland.

1. We have already spoken of *the style*; if the surgeon determines to employ it, the following is the method of doing so. Should the fistula not be in such a position as to enable us to pass a probe through it into the nasal duct, the duct must be slit up so as to allow of this being done; we may then pass an ordinary lachrymal probe through the duct into the nares. The style may subsequently be introduced, and allowed to remain in the duct for two or three days, when it must be withdrawn, cleansed, and returned into the duct. In the course of time the canal becomes enlarged, and in the interim the tears find their way down into the nose along the sides of the style. The cure, however, is a tedious one; and after all, when the style is permanently removed, the duct is very apt to contract again. But independently of the chances of a relapse, the irritation caused by the style is often so great, that people cannot possibly wear it; and lastly, it is apt to slip from its position, and the patient cannot return it into the nasal duct. Consequently, the method of treating a fistula by means of a style is not a promising one.

2. Obliteration of the lachrymal sac, in cases of fistula, has been advocated by Dr. Manfridi of Turin. The sac must be laid completely open, and, if necessary, the tendon of the orbicularis cut through to expose the superior end of the sac. Manfridi then introduces a speculum into the wound, and the sac is to be carefully cleansed of blood and matter; after which its entire surface is to be smeared over with chloride of antimony. A piece of dry lint is to be placed in the cavity, over which poultices may be applied, our objects being "the total destruction and extrusion of the sac, without which we cannot hope for a complete and permanent result." After the destruction and enucleation of the sac in this way, "a channel of communication sometimes still exists between the lachrymal conduits and the nasal canal."

Mr. Windsor, of Manchester, prefers, after completely laying open the lachrymal sac, to fill it with dry lint, allowing the lint to remain in the sac for two days. It is then removed, and the walls of the sac having been thoroughly cleansed, the cavity is to be filled with lint soaked in the chloride of zinc

paste, which should be allowed to remain in the sac for two hours; the lint may then be removed, and water dressing applied. The sac sloughs, and comes away in the course of a few days, and the wound rapidly heals.

3. Lastly, removal of the lachrymal gland, for the cure of a fistula of the lachrymal sac, has been practised.

CHRONIC INFLAMMATION OF THE LACHRYMAL SAC is a common form of disease. It usually commences with subacute inflammation of the lining membrane; but the irritation extending to the mucous membrane of the canaliculus and nasal duct these passages become swollen and obstructed, and the sac is slightly distended in consequence of the accumulation of mucus within it. Under these circumstances, if pressure be made over the sac, a whitish glairy fluid may generally be forced through the puncta. The lachrymal secretion cannot pass through its natural channel, and accumulating in the inner corner of the eye, it runs down over the cheek, giving the patient constant annoyance; he seldom complains of pain in the part, but is occasionally troubled with an itching sensation in the region of the sac. Chronic inflammation of this kind may exist for months, without either increasing or receding; but at any time acute inflammation may supervene, and an abscess of the sac and fistula result.

Treatment.—It is advisable in these cases to open the sac by slitting up the lower punctum and canaliculus, and to run the knife down through the nasal duct; subsequently the edges of the wound should be kept apart till they have healed, so as to establish a permanent opening into the sac, and a lachrymal probe will have to be passed, to keep up a free communication into the nares. The patient should make pressure with his finger over the inner corner of the eye three or four times a day, so as to empty the sac. The recovery is expedited by syringing out the sac once a day with an astringent lotion (two grains of alum to an ounce of water), after having pressed out the contents of the sac; the lotion may be injected with an Anel's syringe. It is advisable to continue this application for some time after all symptoms of the inflammatory action have disappeared.

MUCOCELE consists in an accumulation in the lachrymal sac of its normal secretion, the nasal duct being almost always occluded, and in the majority of cases there is also more or less obstruction in the canaliculi, a watery eye results, and

the sac becoming distended, a small tumour forms at the inner angle of the eye, its size varying from that of a split pea to a pigeon's egg. The patient complains of little or no pain in the part, and the skin over the sac is not inflamed. During the early stages of the disease fluctuation may be felt in the sac, but as it becomes more distended and tense, it might be mistaken for a fibrous growth: the canaliculi and nasal duct being occluded to a greater or less extent, it generally requires firm pressure to be made over the mucocele before its glairy contents can be forced out through the puncta.

Treatment.—The sac having been opened through the canaliculus, it will then be necessary to dilate the obstruction in the nasal duct as we have already described; for it must be remembered that both the upper and lower openings into the sac are for the most part closed in cases of mucocele. These obstructions having both been overcome, we may hope to restore the passage of the tears into the nose, and thus effectually cure the disease.

POLYPI AND CONCRETIONS IN THE SAC.—A polypus has been known to grow from the lining membrane of the lachrymal sac. Calcareous concretions also may form in it, obstructing the passage of the tears into the nose. A polypus in this situation is a very rare form of disease; it induces symptoms similar to those of mucocele, but the tumour feels less elastic to the touch, and no fluctuation can be felt in it. If there is any doubt on the subject, a grooved needle may be run into the tumour and its character ascertained with certainty. The nature of the obstruction, if arising from calcareous matter, may be at once ascertained by passing a probe into the sac; the contact of the instrument with the sandy particles, accumulated either there or in the canaliculus, cannot be mistaken for any other condition of the parts. In cases of this kind the canaliculus and sac must be laid open, and the calcareous matter turned out of them. The same remark applies to the treatment of a polypus; but in this case the tissues covering the sac must be divided, and the polypus carefully removed, together with its peduncle, otherwise it will certainly grow again.

OBSTRUCTION OF THE NASAL DUCT.—The nasal duct sometimes becomes partially, or it may be wholly obliterated, most commonly from chronic inflammation and thickening of the lining membrane; but it may be from periostitis, or disease of the bones forming the walls of the lachrymal duct.

The symptoms caused by obstruction of the duct are, dryness of the corresponding nostril, the formation of a slight painless and elastic swelling in the position of the lachrymal sac, and a constant overflow of tears from the eye. By pressure over the region of the sac, we may determine whether the obstruction is in the nasal duct, or between the puncta and the sac; if the latter, there will be no regurgitation of muco-purulent fluid through the puncta; but if the stricture be in the nasal duct, though the symptoms above enumerated exist, the lachrymal secretion will find its way into the sac, and on pressure being made over it, a drop of fluid will ooze through the puncta. If the stricture is not complete, some of the secretion may find its way down into the nose.

The Treatment of stricture of the nasal duct has already been described. Should the obstruction be a bony one, which is very rare indeed, compared with the number of cases that occur from thickening of the mucous membrane, we are not likely to cure it with the probe; it might then possibly be necessary to destroy the lachrymal sac, and perhaps to remove the lachrymal gland, though we have never had to perform an operation of the kind for cases of this description.

INFLAMMATION OF THE INTERNAL ANGLE OF THE EYE.—An abscess in this situation may lead to the erroneous supposition that the sac itself is involved in the mischief. That such cases occur is certain, for we see abscesses form and burst in this situation without the lachrymal apparatus being in any way compromised. In instances of this description, the abscess comes on without any symptoms of previous disease of the lachrymal sac; the inflammation sets in suddenly, and is not uncommonly attended with erysipelas, especially if the patient is in a weak state of health. The eyelids become much swollen, and lachrymation may exist from pressure of the abscess on the lachrymal sac. After a few days suppuration occurs, and the abscess points; a small quantity of pus escapes, and in a short time all traces of the disease disappear.

Treatment.—In the early stages of the disease we may paint the skin over the sac with a strong solution of nitrate of silver. Subsequently, if suppuration has taken place, the abscess must be opened and poultices or water-dressing applied. The wound heals, and the parts speedily return to their normal condition.

CHAPTER IV.

DISEASES OF THE CONJUNCTIVA.

Anatomy—Hyperæmia—Muco - purulent—Purulent—Diphtheritic—Granular—Pustular Conjunctivitis—Injuries of the Conjunctiva—Hypertrophy and Atrophy—Pterygium—Serous and Bloody Effusions into the Conjunctiva—Tumours of the Conjunctiva—Disease of the Caruncle.

ANATOMY.

THE conjunctiva is the mucous membrane lining the lids and the anterior part of the eyeball. It consists of three parts:—The palpebral portion; the ocular portion; and that forming the superior and inferior cul-de-sacs.

The palpebral portion is closely attached to the tarsus, has a pink yellowish appearance, and allows the Meibomian follicles to be seen through it; its surface is smooth to the naked eye, but when viewed through a magnifying glass is seen to be covered with small papillæ: it consists of fibrous tissue and several layers of cylindrical epithelium. The ocular portion of the conjunctiva is loosely attached to the sclerotic at its point of reflection; it becomes thinner and the sub-conjunctival tissue less as the membrane passes forward; at the margin of the cornea it is closely united to the structures below. The part immediately around the cornea is sometimes spoken of as the *Limbus Corneæ*; this part of the conjunctiva consists of a fibrous membrane with a good deal of elastic tissue, and several layers of squamous epithelium. The epithelium is continuous with that of the cornea.

The conjunctiva of the cul-de-sacs is loose, movable, and thrown into several folds, and is the most vascular part of the membrane. The upper cul-de-sac is much larger than

the lower, but varies a good deal in different cases; in some it is possible to expose the whole of it by inverting the lid while the patient is made to look down.

At the inner canthus is a small elevation, the *Caruncle*, which is a collection of follicles and sweat glands with connective tissue and a little fat; sometimes a few minute hairs may be seen on its surface. Immediately internal to the caruncle is a semi-lunar fold called the *plica semilunaris*; this is the analogue of the *membrana nictitans* found in birds.

CONJUNCTIVITIS.

The various forms of conjunctivitis (ophthalmia) may be described under the following heads:—Hyperæmia, Mucopurulent, Purulent, Diphtheritic, Granular, and Pustular Conjunctivitis.

It is difficult, in the first three of these affections, to draw a line of demarcation between the commencement of one form of disease and the termination of that preceding it; thus, mucopurulent conjunctivitis is always preceded by hyperæmia, and purulent conjunctivitis by both hyperæmia and mucopurulent conjunctivitis; yet, practically, the distinction will be found both natural and useful. The symptoms of diphtheritic, granular, and pustular conjunctivitis are sufficiently well marked to distinguish them from one another, and also from the first-named affection of the conjunctiva.

HYPERÆMIA OF THE CONJUNCTIVA.—The healthy ocular conjunctiva is a transparent tissue, through which the white and glistening sclerotic may be seen; on everting either the upper or lower lid, a number of small reddish streaks may be traced beneath the conjunctiva, extending backwards from the margin of the lids; they mark the position of the Meibomian glands, and as they are situated beneath the mucous membrane, it follows that if the conjunctiva is congested, these reddish streaks will be more or less concealed.

In hyperæmia we may notice, on everting the lids, that the palpebral conjunctiva is not only injected, but that its surface is no longer smooth. This arises from two causes,—first, its villi become prominent from the turgid state of the vessels which they contain; and secondly, its glands are thrown into increased activity, and become enlarged; these,

together with the swollen villi, give the mucous membrane a rough appearance, particularly on the tarso-orbital fold, which is also somewhat swollen from the serous effusion poured out into its loose cellular tissue. The eyelids, caruncle, and semi-lunar folds are also somewhat swollen. The orbital conjunctiva is only slightly affected in simple hyperæmia; it may be that its superficial vessels are congested, in which case they are seen coursing over the sclerotic in a reticulate manner towards the cornea.

Symptoms.—The amount of uneasiness to which hyperæmia of the conjunctiva gives rise, seldom amounts to anything more than a sensation as if dust had fallen into the eye, caused by the rubbing of the congested vessels against the surface of the cornea. This symptom is apt to vary with the age of the patient, being less marked in old persons than in the young, on account of the muscular fibres of the orbicularis losing their contractile power, and pressing the lids less firmly against the eyeball in the case of elderly people. In these circumstances, considerable hyperæmia of the conjunctiva may exist, without the patient feeling any inconvenience whatever from it, because the lax state of the parts admits of considerable vascular engorgement, without any equivalent increase of the natural pressure between the lids and the globe.

In cases of hyperæmia, if the patient is exposed to the glare of the sun or lamplight, or is overworked, it causes a feeling of weariness and irritation in the eye. The secretions from the lachrymal and conjunctival glands are increased in quantity, but are not altered in character; the disease is consequently non-contagious, but the patient complains of his eyes watering a good deal. This symptom is due to the congested state of the mucous membrane of the lids, which extends to the puncta and canaliculi, and the natural passage of the tears into the nose being plugged, they collect in the inner corner of the eye, and overflowing, induce the lachrymation complained of.

The Causes of Hyperæmia of the Conjunctiva are numerous. Among persons suffering from various errors of refraction, especially in low degrees of hypermetropia and astigmatism, the accommodating power of the eye is overstrained, and hyperæmia of the conjunctiva frequently results. In the tropics the glare of the sun combined with the state of the atmosphere, which is often loaded with dust, and among the

lower order of natives, with the smoke from the wood-fires, over which they cook their food, together with miasmatic influences, the fumes of ammoniacal gases, exhalations from open cesspools, and all manner of putrescent filth—all these are constant sources of irritation and hyperæmia. In colder climates no more common cause for simple conjunctivitis exists than sudden changes in the temperature of the atmosphere inducing a “cold.” The presence of a foreign body on the conjunctiva may also give rise to congestion of the mucous membrane. Under this head we should place those cases in which an inverted eyelash, by brushing against the eye, keeps up persistent irritation and hyperæmia. Lastly, congestion of this membrane may arise from a faulty state of the digestive and secreting organs; and not unfrequently from gout.

The treatment of this affection should be directed towards the removal of the cause of the disease; for instance, the eye may be protected from the glare of the sun, or from dust, by neutral tint glasses. Astringent lotions, composed of one to two grains of sulphate of alum to an ounce of water, should be applied to the surface of the everted lower lid, two or three times during the day. In chronic cases, at night the patient should be directed to smear an ointment along the free edges of the affected eyelids:—Ung. hydr. ox. rubri dil. ʒj; vaseline, ʒij.

Astringent lotions in some cases excite irritation and pain in the eye; in these circumstances a weak solution of sulphate of atropine, gr. $\frac{1}{60}$ to an ʒj of solution of boracic acid (4 grs. to the ʒj), should be dropped into the eye twice a day. We may order the patient to use the cold water douche to the closed eyelids, for ten minutes, night and morning.

When the hyperæmia depends on overstraining the eye, our first care must be to protect the organ by rest, and ordinarily fair usage. If the affection is associated with gout or visceral disorder, alteratives, abstinence, as regards tobacco and alcohol, must be enjoined, and a dose or two of blue pill administered. These means are as often required in one class of cases as tonics are in another. It is almost superfluous to remark, that, if hyperæmia depends on the presence of a foreign body in the eye, the offending substance must be removed; if an inverted eyelash, for instance, it must be carefully extracted. In examining an eye, never forget to glance at the cilia, particularly at those growing near the

inner or outer angle of the eye: a single hair may be sufficient to keep up such an amount of hyperæmia, as to render a patient unfit for ordinary work, and unless the offending object is removed, the disease will certainly persist.

If, as is so often the case, hyperæmia of the conjunctiva and margins of the eyelids depend on an error of refraction, we must correct this error by means of proper glasses, otherwise the irritation and redness of the eyes cannot be relieved.

MUCO-PURULENT (CATARRHAL) CONJUNCTIVITIS may be considered as an aggravated form of hyperæmia, with this difference, however, that the discharge from the conjunctiva, though consisting chiefly of watery fluid, contains albumen and shreds of muco-purulent matter; and this matter possesses *contagious* properties.

Symptoms.—In the early stages of muco-purulent conjunctivitis, we find that the vessels of the palpebral conjunctiva are principally affected, so that the position of the Meibomian glands is speedily concealed by the congested mucous membrane covering them; the inner surface of the lids appears of a uniformly red colour, the conjunctiva being slightly swollen, especially at the tarso-orbital fold and caruncle. As a general rule, both eyes are affected. The vessels of the orbital conjunctiva are occasionally involved to such an extent that the sclerotic is hidden by the uniformly red and swollen mucous membrane covering it. In these circumstances, there is generally a good deal of *chemosis*—a term employed, to indicate an œdematous condition, depending on serous infiltration of the sub-mucous connective tissue of the conjunctiva. In the majority of instances, however, the vessels of the orbital conjunctiva are not so deeply injected as above described, but many large and separate vessels may be seen coursing over the sclerotic in a reticulate manner, from the palpebral conjunctiva towards the cornea. The amount of chemosis present varies in different cases; in some it bulges the conjunctiva forwards, and causes it slightly to overlap the margin of the cornea. To the same cause—viz., over-distension of the vessels, we must attribute the patches of ecchymosis seen on both the palpebral, and orbital conjunctiva, in severe cases of muco-purulent conjunctivitis.

The secretion from the lachrymal and conjunctival glands

varies in character during the different stages of the disease; at the commencement it is augmented in quantity, but is normal in quality. As the congestion increases, the circulation through the vessels is impeded, and the first effect of this, observed in the secretion, is the presence in it of albumen; afterwards, as increased cell-formation is established in the epithelial layers of the conjunctival, and conglomerate glands; we find a vast number of epithelial, together with lymph cells mixed up with the serous fluid which escapes from the eyelids. This muco-purulent matter usually collects in whitish flakes, which may generally be seen floating about in the tears, not mixing with them; and when the lower lid is everted, the latter escape, and the flakes of mucus become deposited on the surface of the conjunctiva, especially on the tarso-orbital fold. The diseased action is not confined to the conjunctiva and lachrymal apparatus; after a time the lining membrane of the Meibomian glands, also participates in the irritation going on in their immediate vicinity; their secretion becomes altered in character, as well as increased in quantity, and accumulating on the margin of the lids during sleep, it dries and gums them together; so that, on waking, the patient has often considerable difficulty in opening his eyes, until they have been washed and the concretions removed. The patient complains of a sensation as if grit or sand had fallen into his eye, and it is often difficult to persuade him that this symptom does not depend upon a foreign body, lodged beneath the lids; the affected eye itches a good deal, and the upper lid feels to the patient as if it were stiff and heavy, especially after work or exposure to the glare of the sun or candle-light. An attack of conjunctivitis of this kind usually disappears in the course of a few days, unless its exciting cause should continue in operation, under which circumstances it may pass on into the purulent, or other forms of inflammation, or it may degenerate into a state of chronic hyperæmia.

The Causes which induce muco-purulent conjunctivitis are numerous, but in the majority of cases it may be traced to atmospheric influences, such as cold or damp, or sudden changes of temperature. These are, however, not sufficient to account for the sudden outbreaks of this complaint, which often has an epidemic prevalence; doubtless contagion plays an important part in the propagation of the disease, and it often spreads in this way through a school, a regiment, or a

community. Miasma, foul air from overcrowding, putrescent and irritating exhalations from drains and cesspools, are also sources of this form of conjunctivitis, and greatly aggravate its progress. Foreign bodies lodged on the conjunctiva may give rise to muco-purulent conjunctivitis; for instance, an insect finds its way into the eye, and becoming impacted in the folds of the conjunctiva, induces muco-purulent inflammation. Lastly, a muco-purulent conjunctivitis is apt to occur in the course of the various exanthemata.

Treatment.—The first object to be kept in view in the treatment of muco-purulent conjunctivitis is to remove, if possible, the cause of the disease. As a general rule there can be no difficulty in accomplishing this, should the inflammatory action depend on the presence of a foreign body; but if it be induced, as it too frequently is, from the prolonged action of dust, foul air, over-exposure to the sun, or other irritating causes, it may be difficult, especially among the lower classes, to protect them from these deleterious influences.

In treating these cases, we should never overlook the fact that the affection is a contagious one, and therefore it is our duty to guard against the spread of the disease, which may take place by means of linen, water, or any article which has been soiled with the discharge from the eyes of a person suffering from this form of conjunctivitis. Isolate, therefore, as far as possible, a person suffering from a muco-purulent discharge from his eyes; a few days' treatment will destroy the contagious property of the discharges. The state of the patient's general health must be taken into consideration; the secreting organs will frequently be found at fault, and a little judicious starving, in some cases, together with a bluepill, black draught, and colchicum, will do wonders, particularly if the individual is the subject of a rheumatic or gouty diathesis. If the patient suffers from ciliary pains and irritability of the eye, apply a weak solution of sulphate of atropine to the eyes, and iced compresses in some cases; in others, hot poppy-head fomentations are most grateful to the patient, and may be employed three or four times a day. The eyes should be constantly bathed with a solution of boracic acid, or with corrosive sublimate, one part to four thousand of water.

So soon as the irritation has subsided, and the muco-purulent nature of the discharge has passed off, astringents

may be employed. A lotion composed of two grains of sulphate of alum to ʒj of water, should be applied to the surface of the conjunctiva twice a day. Should the discharge from the eye be copious when we first see the patient, or become so after treatment such as above indicated, we may drop a solution of nitrate of silver, containing two grains to ʒj of water, into the eye every six hours for about forty-eight hours; we may then as a rule order the atropine and mercurial solution to bathe, and drop into the eyes. Iced compresses should be kept constantly applied over the closed eyelids. It is advisable, in any circumstances, to order the patient vaseline to smear along the margin of the lids at bedtime, so as to prevent them from sticking together during sleep. To ensure a complete recovery the patient should abstain from work, and keep away from bright sunshine; neutral tint glasses, or a gauze shade, should be worn when he is exposed to glare or dust, until the inflamed conjunctiva has resumed its healthy appearance.

PURULENT CONJUNCTIVITIS.—This formidable disease varies much in intensity in different individuals, and in different places; it is most destructive among the poor and ill-fed, and those whose constitutions have been impaired by disease; but in any circumstances it too frequently ends in sloughing of the cornea, and partial, if not total, destruction of sight.

It is impossible, as we have before remarked, to draw a line of demarcation between the termination of muco-purulent and the commencement of suppurative conjunctivitis, the latter being a more intense form of disease than the former; but in its first stage it would be impossible, in any given case, to say positively if the inflammation would advance to suppuration or not, although in the majority of instances all doubts on the subject will be cleared away in the course of a few hours. In fact, in cases arising from the inoculation of the gonococcus or other specific contagious matter into the eye, symptoms of intense inflammation declare themselves very rapidly, and leave no room for doubt as to the formidable nature of the disease with which we have to cope.

Intimately connected with the stagnation of blood in the conjunctival vessels, of an eye affected with purulent inflammation, are certain active changes set up in the part, resulting in increased cell-formation; the congestion, moreover, occasions

a considerable amount of serious infiltration into the loose connective tissue of the lids, and from these combined causes the swelling and œdema of the parts arise. The extent to which the eyelids are swollen in cases of this kind is not a safe criterion of the intensity of the disease. We have met with instances in which the eyelids were only slightly swollen, and yet sloughing of the cornea supervened rapidly.

In cases where the serous effusion into the connective tissue of the conjunctiva is excessive, this membrane becomes so much swollen that the lids are thrust away from the eyeball; but the fibres of the orbicularis, contracting firmly, prevent the lids from being easily everted. The distending force from within may, however, ultimately gain the ascendancy, and the lid will then be turned backwards on itself, ectropion resulting. This accident is most liable to occur in young children; their attendants are apt to evert the swollen lids, in the attempt to apply drops or lotion to the eye. The accident may not be noticed till some hours afterwards, and in the meantime the fibres of the orbicularis at the line of eversion form a constricting band, which presses firmly on the part, and impedes the circulation of blood through the vessels of the everted portion of the lid; and unless the ectropion is speedily reduced, and the parts returned to their normal position, the conjunctiva is likely to slough.

Corneal Complications.—In severe cases of purulent conjunctivitis, the circulation in the part is impeded; in addition to this, the swollen conjunctiva overlaps the margin of the cornea, and in many instances the chemosis is so great, that the cornea appears buried in the crimson folds of the mucous membrane. This effusion into the conjunctiva tends to augment the impediments to the circulation through its deeper layer of vessels; and these combined causes materially interfere with the passage of blood to the margin of the cornea, and so lead to ulceration of that important structure.

The commencement of this disorganizing process is sometimes seen in a general haze of the cornea, but more commonly as a patch or patches of grey infiltration, usually situated at the periphery. The ulceration usually commences and follows the margin of the cornea beneath the chemosed conjunctiva, and unless the swollen mucous membrane be pressed backwards, the destruction progressing beneath it may not be recognized; the diseased action, however, ad-

vances, the cornea is perforated, and prolapse of the iris occurs, the centre of the cornea, it may be, looking clear to the last.

In other cases, the ulcer spreads completely round the margin of the cornea, the nutrition of its central portion is cut off; it becomes hazy, necrosis occurs, followed by a rupture of the cornea, and probably the evacuation of the greater part of the contents of the eyeball. These changes sometimes run a rapid course, so that a cornea, which in the morning looked clear, in the evening is hazy, and on the following day may have sloughed; not that the process absolutely occupies so short a time, for in all probability, had the chemosed conjunctiva been pressed backwards, and the margin of the cornea examined, we should have found its circumference deeply ulcerated as above described.

Lastly, in a few instances the cornea appears as though it had been stained with a solution of carbonate of lead, being of a pinkish-white colour and semi-transparent. These changes depend on suppurative keratitis, the cornea is unable to resist the intra-ocular pressure and it bulges forward, particularly towards the centre, which may ultimately burst, and through the rent thus made, a hernia of the iris occurs. This class of cases is seldom marked by very acute symptoms, the chemosis is not a prominent feature of the disease, nor is there much purulent discharge from the eye; but these degenerative changes advance in the fibrous structure of the cornea, indicating a most serious state of things when occurring as a complication of suppurative conjunctivitis.

No sooner has the cornea been destroyed by any one of the processes above noticed, than the patient experiences relief; the intra-ocular pressure being removed, the pain at once abates, the discharge becomes less, but the surgeon knows too surely that his patient's sight is probably lost. Nevertheless, as long as any portion of the cornea retains its vitality, the case must not be abandoned in despair; for if only a small portion, less than a quarter of one cornea, can be saved from destruction, and its transparency retained, some sight may be eventually gained by the operation of artificial pupil.

The Causes of Purulent Conjunctivitis.—Whether it occurs in patients suffering from gonorrhœa or in new-born infants, it is clearly traceable to the presence of gonococci brought into contact, and so planted in the deeper layers of the con-

conjunctiva. Pus, which does not contain this living micro-organism, will not cause an attack of purulent conjunctivitis, but if after cultivation of the gonococci, they are planted on the epithelium of the conjunctiva, in from thirty-six to forty-eight hours the cocci will have spread rapidly, invading the whole of the epithelial covering of the conjunctiva, and being thrown off the surface of the eye in conjunction with the remains of these cells in countless multitudes. It is evident that this micro-organism incites intense irritation in the part, and in this way engorgement of the vessels, purulent discharge, and so leads to the pathological changes which we have referred to. The coccus does not seem to spread deeper into the conjunctiva than its epithelial layers, but either in these cells or in conjunction with them it is capable of contaminating linen, water, or anything with which it is brought in contact, and then if it gains access to the sound eye of the patient, or to the eyes of another person it may establish purulent conjunctivitis. There is every reason to believe that the coccus when present on linen or other such material, in a dried condition, may retain its properties, and can after a considerable lapse of time assume a dangerously active form, if exposed to moisture and a certain degree of temperature.

Subjective Symptoms.—At the commencement of the attack the patient complains of the affected eye itching a good deal, as if sand or dust had got into it; but this symptom seldom lasts more than thirty-six hours. In the second stage the chemosis and swelling of the lids are often considerable, and the pain is frequently acute, but is by no means constant in proportion to the swelling of the parts; it depends to a great extent upon the degree to which the deeper structures of the eye are involved, and upon the temperament of the patient. The pain usually increases towards bedtime. There is always intolerance of light, and although the lids may be so much swollen that the patient cannot open them, he still prefers being in a dark room, and the moment he is brought towards the light there is a flow of pus from between the lids, and an instantaneous increase of pain in the eye. In fact the physiognomy of a person suffering from an attack of purulent conjunctivitis in its second stage, is characteristic of the disease; his countenance indicates pain and distress; he is led into your presence by a companion, being unable to see; the eyelids are more or less

red and swollen, their free margins being usually of a scarlet colour, and pus is seen oozing from between them; the patient holds a handkerchief or his hands before his eyes, so as to screen them from the light as much as possible. It by no means follows that both eyes are affected; but the sound one is usually kept closed, as exposure to light at once induces pain in the diseased organ.

Prognosis.—In endeavouring to estimate the probable issue of a case of this kind, the condition of the cornea must chiefly engage our attention; if it is bright and clear, and no ulceration is going on at its circumference, the patient's health at the time being good, our prognosis may be favourable. If, on the other hand, ulceration has commenced, our opinion must be guarded; and if sloughing of the cornea has begun, we can give the patient no reasonable hope of recovery; he may regain some amount of sight in the diseased eye, but at best it will be imperfect.

The conjunctival inflammation seldom subsides completely under six weeks; it may then gradually assume its healthy condition, or the inflammation may pass into a chronic state; in this case the membrane remains swollen for a long time; its palpebral portion assumes a uniformly thick velvety appearance, not unfrequently the eye is unworkable, but often leading to ectropion and various other complications.

In forming our prognosis, also, we must constantly bear in mind the fact that purulent conjunctivitis is apt to relapse. A patient may apparently be on the road to recovery, when suddenly a return of all the worst symptoms takes place, and his prospects of ultimate improvement become much impaired.

Treatment of Purulent Conjunctivitis.—If one eye only is affected, so soon as the patient consults us, we should at once carefully wash out the sound eye with a solution of corrosive sublimate, (1 to 5,000) as also the skin of the eyelids and eyebrows. A watch glass is then to be secured in front of the sound eye, and held in place by means of india-rubber plaster in which a round hole has been cut. The watch glass is thus securely plastered down to the nose, forehead, and cheek, and only left open below to allow of the circulation of air to the eye.

If we cannot secure the sound eye in this way, after it has been thoroughly washed with the mercurial solution, it should be padded over with antiseptic gauze, and wool, which may

be kept in place either by means of a bandage, or with strips of rubber-plaster. Our attention must next be towards the preservation, if possible, of the cornea in the diseased eye.

If the conjunctivitis were not the cause of ulceration of the cornea, we might almost leave it to itself, but as it is, unless we can reduce the inflammation going on in the mucous membrane, no amount of care and skill on our part can insure the safety of the cornea. In considering the treatment, therefore, of purulent conjunctivitis, we may divide the cases into two classes: the first to include the milder ones, in which the cornea is unaffected; the second, the more severe cases, in which ulceration of the cornea is progressing.

In the first class of cases, discarding all consideration as to the cause of the disease (unless in instances arising from the presence of a foreign body in the eye), or whether the patient be an infant or an aged person, but distinctly bearing in mind the fact, that we are now discussing those cases which are not complicated with ulceration of the cornea, we should at once order a solution of two grains of nitrate of silver to the ounce of water, to be dropped into the eye every second hour. These drops should be continued for a week or ten days; by that time the active symptoms of the disease will probably have subsided. It is seldom necessary, however, to use the nitrate of silver drops every second hour, as above directed, for more than two or three days; after that we may generally use it every six hours. In addition to the nitrate of silver, the patient's eye must be constantly bathed with a solution of corrosive sublimate (1 to 5,000), some of which should also be allowed to run between the eyelids so as to reach the conjunctiva. At bedtime an ointment containing iodoform, four grains to half an ounce of vaseline, may with advantage be smeared along the edges of the eyelids.

In cases of this kind patients do not usually suffer from much pain in the eye, and the poppy-head fomentation with extract of belladonna smeared over the temple will probably relieve pain; in some instances, however, especially if the patient complains of considerable pain in the eye, a few leeches applied about an inch from the outer canthus are beneficial, together with iced compresses. The state of the bowels should be attended to, and, as a general rule, a generous dietary allowed. Quinine and a moderate amount

of stimulants are as often called for as antiphlogistics; but the state of the pulse must be our guide in this matter.

The chief difficulty with which we have to contend, in treating the purulent conjunctivitis of infants and young children, arises from their resisting our attempts to drop the solution of nitrate of silver into the eyes. The child's head must be firmly secured, and the lids gently drawn apart, and the lotion having been dropped into the eye, the lids may be allowed to close. This proceeding should be repeated three or four times, and the eyelids then bathed with the mercurial solution, and the child allowed to rest for two or three hours, when the drops and lotion will have to be used again in precisely the same way, the application being continued night and day until the purulent discharge almost ceases. If it should be found more convenient to apply the lotion by means of an "eye-drop" or by a syringe, by all means let an instrument of the kind be employed. What we must insist on, is that the nitrate of silver lotion is brought thoroughly into contact with the inflamed surface of the conjunctiva.

A simple instrument which is very useful in many of these cases, is a hollow lid retractor, perforated at its edge by numerous small openings; the handle is connected by means of an india-rubber tube with a reservoir containing the antiseptic solution, and is supplied with a tap; with this instrument the fluid can be carried directly into the superior cul-de-sac, and so the conjunctival sac can be thoroughly flushed out with but little discomfort to the patient.

In most cases, if this plan of treatment be followed out, a considerable improvement will be quickly noticed in the state of the child's eyes. Within four or five days the little patient will begin to open them; the swelling of the lids and congestion of the conjunctiva diminish; and we may then discontinue the drops, and either go on with the mercurial solution or substitute for it a solution of boracic acid. We should bear in mind the fact, that a relapse is just as likely to occur in this, as in any other form of the disease, and not entirely discontinue the use of the lotion until the child has perfectly recovered; and should a relapse occur at any time, and the discharge become purulent, we must resume the nitrate of silver solution.

We may now proceed to consider the treatment of the second class of cases—that is, those in which the cornea has become implicated, either during or prior to the commence-

ment of our attendance on the patient. We must still rely mainly on the application of a solution of nitrate of silver to the eye (two grains to the ounce of water); the lower lid must be everted and the lotion injected into the eye by means of a small syringe, or an instrument made for the purpose, consisting of a glass tube, one end of which is drawn out into a point, and the other covered over with some flexible material. If an "eye-drop" or syringe are not at hand, the lotion may be applied to the eye by means of a feather, or camel-hair brush. The solution of nitrate of silver should be instilled into the eye every second hour throughout the day, and as frequently as possible during the night, until the purulent discharge has perceptibly diminished, when the lotion may be used every three or four hours. A constant use should be made of the solution of corrosive sublimate; and of the iodoform ointment at bedtime. It seems more than probable in these cases, that the sulphate of eserine instilled into the eye two or three times a day is of use. The strength of the solution should be two grains to an ounce of water. The application of iced compresses to the eyelids should be continued, if possible, without intermission, a pledget of lint sufficiently large to cover the eyelids should be laid on a lump of ice until frozen; it must then be placed on the lid, and changed for another pledget so soon as it becomes warm; compresses of this kind should be kept on the ice in rotation, so as to maintain a constant cold surface to the inflamed eyelid.

With regard to the management of the orbital conjunctiva, if much swollen and overlapping the cornea, it may be advisable to make four or five incisions through the mucous membrane, radiating from its chemosed portion, which overlaps the cornea, outwards as far as the eyelids. There can be no doubt that, by cutting through the swollen conjunctiva in this way, we relieve the pressure which the chemosis exerts, and thus, perhaps, give the cornea a better chance of receiving nourishment. There is one point that has to be attended to, if this treatment is adopted, and that is, to make no pressure on the globe of the eye; and we had better not attempt incisions if the patient strains at all; pressure, or an effort of straining, may burst open an ulcerated cornea, and so destroy an eye, a portion of which might otherwise have been saved.

The above may be considered as the special and necessary

treatment for cases of purulent keratitis and conjunctivitis. We may now consider one or two points bearing on the general treatment of such cases, whether complicated with ulceration or not; the pain from which many patients suffer in this disease may be relieved by the application of the extract of belladonna over the forehead, and the administration of bromide of potassium and chloral at bedtime, for it is then that the pain generally increases, and prevents the patient from sleeping. With regard to the application of leeches, it would be as absurd to deplete a weak, anxious, and anæmic patient labouring under purulent conjunctivitis, as it would be to abstain from the practice in all cases; our common sense must guide us in the matter. Stimulants are more often required than leeches; rum mixture, with quinine and morphia, being frequently called for, together with a generous diet; the state of the patient's pulse will be our best guide as to the extent to which this practice should be carried. In many cases the infusion of bark with ammonia will prove of the greatest benefit; should it seem to increase the pain in the eye, it may be discontinued, but if it has no such effect, it is more than probable that the patient will improve under its use.

We cannot too strongly insist upon the enforcement of absolute cleanliness, and, as far as possible, segregation, among patients suffering from purulent conjunctivitis. The attendants must be strictly warned as to the danger they run from contact with the purulent discharges. Cases of purulent conjunctivitis should not be admitted into a general hospital, unless they can be isolated; and the strictest orders should then be given, that the dressing or rags employed should be burnt after use. Washing utensils, and in fact everything brought in contact with the patient, should be retained for his special use.

DIPHTHERITIC CONJUNCTIVITIS.—This is a comparatively rare form of disease in this country, but in some parts of Germany it appears to be more often met with, a patient attacked with this disease has even less chances of recovering his sight than in cases of purulent conjunctivitis.

Pathology and Symptoms.—If we bear in mind the characteristic features of diphtheria in other situations, we shall readily comprehend the nature of the phenomena induced when it attacks the conjunctiva. The same tendency manifests itself

here, as in the mucous membrane of the fauces and other parts of the body, for a fibrinous formation to occur, not only on the surface, but also in the connective tissue of the mucous membrane; the eyelids become swollen, hard, and brawny, so that it is with difficulty they can be everted, or, in many cases, even separated from one another, and in attempting to drag them apart we put the patient to great pain.

For the first twenty-four, or even forty-eight hours, it may be impossible to determine the nature of the disease, the conjunctiva becomes intensely red and inflamed, the eyelids are swollen and soon become of brawny hardness; there is some pain in the eye, and a purulent or muco-purulent discharge. But before the close of the second day if the case is one of diphtheritic conjunctivitis, one or more patches of a greyish white colour, and adherent to the inner surface of the lids leave no doubt in our mind as to the nature of the disease. In the course of a few hours, on examining the conjunctiva, we shall find it of a buff tint, with reddish streaks here and there, the inner surface of the lids presenting a mottled appearance. This arises from the buff-coloured fibrinous formations which infiltrate the part, exerting pressure on the vessels and stopping the circulation through their smaller branches; some of the larger vessels remain patent, while others give way, and their altered contents, staining the fibrinous formation around them, produce the mottled appearance referred to. If we attempt to remove any of this fibrinous formation, we shall find that it adheres firmly to the conjunctiva; we may detach it, but it breaks away in shreds, and from the jagged surface of the wound which is left, a bloody, serous fluid oozes away; the formation, in fact, is by no means limited to the surface of the conjunctiva, but exists principally in the submucous connective tissue. The changes and appearance of the conjunctiva above described are not confined to the eyelids; the same condition exists in the mucous membrane covering the sclerotic, the fibrinous formation infiltrating the conjunctiva throughout the whole of its extent, and too often extending to the cornea.

The period during which the diphtheritic membrane is forming may be considered as the *first stage* of the disease; it usually lasts about six days, and is accompanied with fever and great pain in the eyes, extending to the temples and head; this pain is increased if we attempt to open the eyelids,

which are swollen and of brawny hardness. The temperature of the part is sensibly increased. The secretion at this period is scanty and serous. As a general rule both eyes are affected.

The *second stage* is one of reaction, degenerative changes taking place in the fibrinous exudations, which become softened and broken down. The detritus thus produced, together with pus cells from the connective tissue, and disintegrated blood corpuscles, are thrown off from the surface of the conjunctiva as a bloody, purulent discharge, containing shreds of fibrinous substance. The appearance of the everted lids is now completely altered, and nearly approaches that of the second stage of purulent conjunctivitis. The vessels are dilated and turgid with blood, the surface scarlet, but still presenting some patches of yellow exudation; the discharge is abundant. The patient is now almost free from pain. This stage varies in its duration, in proportion to the amount and depth of the primary infiltration: if this has been great, the suppurative stage will be prolonged, and the reverse if it is scanty or superficial.

In the *third stage* of the disease, the inflammatory action subsides, and the effects of the previous changes which have taken place in the conjunctiva become apparent. Of these, the destruction of the sub-conjunctival tissues, consequent on the fibrinous formation in the part, is most obvious; and in the reparation of the damage thus done, cicatrices are formed, which, in contracting, press upon and obstruct the few remaining vessels of the conjunctiva, so that the mucous membrane may at length be entirely destroyed, and replaced by white, cicatricial tissue, which may form bands of adhesion between the eyelids and the globe. The duration of this stage will vary with the amount of destruction already effected; it is usually prolonged.

Prognosis.—From the foregoing account, it is evident that a favourable termination can rarely be looked for. If the first stage has been severe, we cannot but be extremely anxious as to the result; disorganization of the cornea is almost sure to occur, and we must frame our opinion accordingly. Even in apparently mild cases, our prognosis must be guarded, for, like purulent conjunctivitis, the disease is subject to relapses, and a case which at first appeared favourable may be less so afterwards.

Treatment of Diphtheritic Conjunctivitis.—German prac-

tioners advocate an antiphlogistic plan of treatment proportioned to the sthenic character of the affection—namely, the energetic application of cold to the part, extensive local bleedings, and the severest antiphlogistic regimen. Others would add the administration of mercury in large and repeated doses, so as to bring the patient under the influence of this drug as speedily as possible; calomel and mercurial inunctions are, in fact, and appear to be, the means upon which they chiefly rely to stay the progress of the disease. They have been closely followed by other continental practitioners; thus, in the first stage of diphtheritic conjunctivitis, M. Wecker employs cold water compresses to the lids, and he also recommends the application of leeches to the temples; but, above all things, he insists on the administration of calomel every second hour. As soon as the patient is salivated, he affirms that the conjunctiva loses its buff-grey appearance, the second stage of the disease being speedily established. He speaks favourably, also, of the effects of tartar emetic in relieving the feverish symptoms.*

As our continental brethren have had the most experience in diphtheritic conjunctivitis, these methods of treatment demand our careful consideration, but we are disposed to adopt a different method, and one which has been very generally sanctioned both in England and America in the treatment of diphtheria,† relying more on large doses of the sesquichloride of iron, and salicylic acid, than on any other drugs, in the first stage of the disease; thirty drops of the tincture of iron may be administered every three hours, and this in spite of the fever which generally attends the outset of the

* Dr. Pagenstecher reports on fourteen cases treated “by scarifications and the energetic application of cold in the diphtheritic, caustics and atropine in the secreting, stages. Six did badly, the rest were more or less benefited.”—*Ophthalmic Review*, vol. i, p. 109.

Professor Stellwag, while fully adopting the antiphlogistic method in the active stages of the disease, rejects mercury and other reputed *antiplastics* as “absolutely and certainly inefficacious.”

See also *Ophthalmic Hospital Reports*, vol. v, p. 363, where the disease is reported to have advanced rapidly, in spite of calomel.

† The American editors of Professor Stellwag’s work observe: “The accepted general treatment in the United States for diphtheria in any form is the administration of iron and nutrients, *e.g.*, beef-tea, until the patient has rallied from the depression caused by the disease. We suppose this is as applicable in diphtheritic conjunctivitis as in any other form of this blood disease” (p. 325).

affection. At the same time, the eyes should be frequently washed out with a solution of corrosive sublimate (1 part to 5,000), in the first instance, and then 1 to 6,000. Iodoform ointment may be freely applied to the lids, and iced compresses must be constantly employed over them. The state of the bowels must be attended to; hot baths at bedtime often induce perspiration and quiet the patient. As a general rule, a lowering plan of treatment is to be avoided; on the other hand, soup and a generous, though non-stimulating, dietary are demanded. Bromide of potassium and chloral should be given in sufficient doses at bedtime to procure the patient sleep during the night.

When the purulent discharge has commenced, and the conjunctiva become red and vascular, the local treatment should be conducted upon the same principles as we have described for the treatment of purulent conjunctivitis. A solution of two grains of nitrate of silver to an ounce of water may be dropped into the eye frequently, together with boracic acid lotion or the mercurial solution; cold compresses over the lids being still constantly employed. We should further remember that the discharge is not only contagious, but appears to possess irritating properties, and consequently to keep up the diseased action, if allowed to remain in contact with the eye.

In the third stage of the disease, very little can be done to prevent the formation and contraction of the cicatrices, which are, unfortunately, the natural consequence of the loss of tissue, following the previous destructive action of the disease.

GRANULAR CONJUNCTIVITIS, or ophthalmia.* Synonyms: trachoma, follicular, Egyptian, military ophthalmia; papillary and vesicular conjunctivitis.

The fact of a disease having been described under so many different names, is strong evidence as to the existence of vague ideas regarding its nature. In the case of granular conjunctivitis, this diversity of opinion has arisen partly from the obscurity surrounding its pathology, and also from the loose way in which the term trachoma has been employed, to designate one of the prominent features of this form of

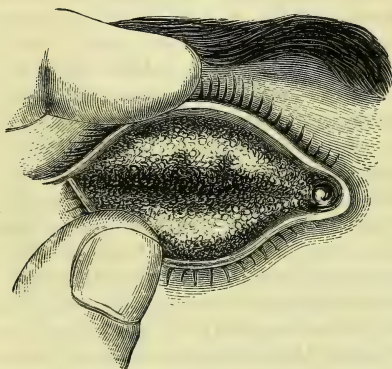
* The following observations on Granular Conjunctivitis were published in the *Westminster Hospital Reports* for 1890, vol. vii.

conjunctivitis. The word trachoma in works on ophthalmic surgery is frequently employed as synonymous with the term granular conjunctivitis; trachoma, however, simply means a rough or uneven appearance of the conjunctiva, and the surface of this mucous membrane may become rough as a result of various causes, other than that which induces granular conjunctivitis. Nevertheless, the opaque, firm, fleshy elevations seen on the conjunctivæ of patients suffering from granular ophthalmia is almost peculiar to this affection, and if we restrict the term trachoma to this state of the eyelids there can be no harm in making use of the word; but we must clearly understand that trachoma, or the hypertrophied villous tissue of the conjunctiva, is the result of irritation of the structures implicated, and that this irritation likewise leads to the accumulation of lymph cells in the sub-mucous tissues, and so to the growth of granules, the production of which have led to the term granular conjunctivitis, or ophthalmia.

In a considerable proportion of the out-patients attending our ophthalmic hospitals, we may see on everting the eyelids, after wiping away the moisture from their surface, that there are on the tarsal fold of the conjunctivæ a number of greyish pearl-like elevations, resembling a millet seed, or the eggs in the spawn of fish; their colour and transparency may be compared to that of catgut. These granules form in the sub-mucous tissue, and consist of an aggregation of round cells and a network of fine connective tissue; as the cells accumulate they press upon the surrounding structures and so produce a capsule. Granules of this description often extend over the orbital conjunctiva and into the cornea. Wherever situated, the granules sooner or later either disappear, or else undergo fatty degeneration, and in time their place becomes occupied by connective tissue, which gradually contracts, and obliterates most of the blood-vessels and lymph canals, leading to the entire destruction of the mucous membrane. Changes of this kind in the conjunctiva produce alterations in the curvature of the tarsal cartilages, and so to ectropion, entropion, and trachiasis. In by far the majority of cases the growth of these granules is accompanied with the formation of opaque excrescences on the conjunctiva, due to hypertrophy of the villous structure of the mucous membrane (Fig. 21). These fleshy projections resemble the florid granulations often noticed round a fistulous

opening connected with diseased bone. The affection, how-

FIG. 21.



ever, which we are considering, is not called granular conjunctivitis because of the granulation tissue above referred to, but on account of the granules which, as a rule, although not necessarily, precede the increased growth of the villous structure of the conjunctiva.

The question naturally arises as to the cause of these granules and hypertrophied villi. This question has now been

answered by the discovery of a specific micro-coccus in the affected tissues. From the researches of Sattler, Schmidt of St. Petersburg, and many other observers, we learn that the trachoma-coccus closely resembles the coccus of chronic gonorrhœa. When introduced after cultivation under the conjunctiva of healthy animals, but more rapidly in half-starved creatures, this coccus causes the growth of the granules and hypertrophied villi of granular conjunctivitis. Cultivations of the trachoma-coccus are characteristic on blood serum and in agar-agar; they are invariably found in the granules and villous tissues of individuals or animals affected with granular conjunctivitis. In fact, as in tubercular disease of the conjunctiva, we have distinct evidence of the presence of the tubercle bacillus in the affected tissues, so in granular conjunctivitis it has been as clearly demonstrated that the trachoma-coccus is present. We may further observe that, as in tubercle, the presence of the bacillus leads to necrosis of the tissues, in which it finds a home, so the trachoma-coccus, if planted in the mucous membrane of the conjunctiva, produces changes which terminate in cicatrization and contraction of the structures surrounding the micro-organism.

Staderini states* that if the trachoma-coccus is introduced

* "Annali di Ottalmologia," Anno xvi, Fasc. 5, E. 6.

beneath the epithelial layer of the conjunctiva, it is not until about the end of the second week that it causes any visible changes in the part. If sections of the tissues are then examined, granules, or the aggregation of white blood and lymph corpuscles, may be seen. As these cell-nests become matured they are permeated with a fine reticulum of connective tissue, and acquire an investing membrane formed in the manner above indicated. Subsequently hypertrophy of the papillary structure of the conjunctiva occurs, both the granules and overgrown papillæ being the result of irritation due to the presence of the trachoma-coccus in the tissues. It is the presence of this organism in the villi which renders them, and also the granules, so rebellious to treatment, and in this respect granular conjunctivitis differs from ordinary catarrhal affections of this mucous membrane.

The feature of granular conjunctivitis which, however, causes us the greatest anxiety is the vascular opacity of the cornea (pannus), so frequently met with among patients suffering from this form of disease, and which leads in so many cases to impairment of sight, if not to complete blindness. The first sign of pannus consists of a collection of lymph cells in the cornea beneath Bowman's membrane. Blood spaces and vessels form in this layer, and subsequently a tissue which possesses the properties of adenoid tissue. This new growth having a low degree of vitality, is apt to break down in small circumscribed areas, forming an ulcer, which as a rule, however, has a tendency to heal rather than to extend deeply into the cornea. In fact, typical nests of round cells such as those met with in the conjunctiva are also found in the cornea, and under the influence of the trachoma-coccus they give rise to very much the same changes in the structures involved.

The micro-organism so frequently referred to is obviously directly or indirectly a source of irritation to tissues in which it takes root, and the blood-vessels of the part are very apt to become hyperæmic in connection with the altered condition of nutrition thus induced. The engorged vessels lead to the formation of muco-purulent matter on the surface of the conjunctiva, and in this fluid a number of the spores, if not trachoma-cocci, are to be found. In this way we can understand how it is that the secretion from the eyes of persons suffering from granular conjunctivitis is infective, and so how it comes to pass that when once this form of

ophthalmia occurs in a school or other such community it is likely to spread from one person to another. How far hereditary tendencies modify tissues so as to render them susceptible to the attacks of certain micro-organisms we are unable to determine. But we know that persons of all ages existing in a dark, smoky atmosphere, such as that prevalent in the over-crowded parts of our large cities, are peculiarly susceptible to the inroads of micro-organisms; in addition to this, the conjunctivæ of persons living in filth and want are subjected to deleterious and irritating fumes, or to mechanically suspended particles in the air, which are apt to excite an unhealthy state of this mucous membrane, and so to produce a favourable soil for the development of certain cocci. Mr. Sydney Stephenson has lately given us a good illustration of the difficulty which exists in getting rid of granular conjunctivitis when once it has become established in a community such as that of a regiment, ship, or as in this instance, in a school (*Lancet*, April 5th, 1890). Mr. Stephenson observes that in the Central London District School at Hanwell, ophthalmia has always existed; and had become so intractable and so great a bane to the institution that in 1889, the authorities determined to carry out a complete and well-devised system of isolation, or rather strict separation of children affected with granular lids from the rest of the community. Iron buildings were erected at some distance from the school, every attention being paid to the water supply, drainage, and cleanliness of these houses, into which children were sent if suffering from symptoms of ophthalmia. Having been admitted into the isolation school, the inmates are taught, fed, and live absolutely apart from their fellow-creatures, and their conjunctivæ are carefully treated by Mr. Stephenson. The result so far has been satisfactory, and although, in consequence of the flow of children from the slums of London into the school, fresh importation of the disease occurs, nevertheless, under a system of careful medical supervision and isolation, such as that now in force in the Hanwell District School, there is every reason to believe that granular ophthalmia will disappear from among the inmates of this establishment.

Symptoms.—As we have before remarked, if we examine the conjunctivæ of a number of children, or it may be of older people, living in the poorer quarters of London, or other large cities, especially among the lower classes of our

Irish and Jewish population, we shall find, although they may not complain of having anything the matter with their eyes, that the following condition exists. On the palpebral conjunctiva, especially in the tarsal portion, a number of small, light grey or yellow, somewhat transparent, raised granules may be seen; these are sometimes so minute, that a lens and oblique illumination is necessary to enable us to perceive them. In conjunction with these granules the surface of the tarsal conjunctiva is redder than natural, unless the patient happens to be anæmic; the papillæ on its surface are swollen and greyish; the retrotarsal fold projects considerably, especially on the everted upper lid. We may notice patches of the enlarged papillæ elevated above the surrounding conjunctiva, and it is usual in such cases to find distinct traces of mucus in the conjunctival sac. It is possible to mistake the granules above referred to for the accumulation of lymph-like cells forming a row of vesicles on the retrotarsal fold of the lower lid, and which are frequently seen in cases of simple catarrh, or in persons who overwork their eyes. The chalky white deposits in follicles of the Meibomian glands of old people have been mistaken for the granules above referred to; and the patches of swollen papillæ, for those which form round a foreign body or the perforation of a chalazion.

This passive and early stage of granular conjunctivitis may continue for months or years without giving rise to any obvious symptoms or inconvenience; spontaneous recovery, however, probably never occurs; but if the individual is removed to favourable surroundings, and is well fed and properly treated for some months, the granules may entirely disappear. In exceptional cases the granules commence in the orbital conjunctiva and cornea, at any rate we find them in this situation and not on the palpebral mucous membrane.

In by far the majority of cases, the first indication of disease in the affected eye is an attack of conjunctivitis; the patient comes to us suffering from intolerance of light, lachrymation, a sensation of grit in the eyes, and it may be pain; there is also a muco-purulent discharge, and the eyelids stick together in the morning. These symptoms are aggravated by exposure to light, or by any attempt to use the eyes. On everting the lids we may see well-marked granules on the tarsal conjunctiva, especially of the upper

lid, the papillæ are engorged, often in patches, and the vessels of the conjunctiva throughout the whole of their extent are much injected; flakes of mucus may usually be observed on the tarsal-orbital fold of the conjunctiva and about the inner canthus. An attack of this kind may pass off in the course of two or three weeks if properly treated, and the patient then returns to his employment, or, if in the army or navy, to duty. Men affected with granular lids are, however, liable to an attack of severe conjunctivitis at any moment if exposed to unusual sources of irritation, such as the dust of a tropical country, excess of heat, or cold and damp. Among the civil community the same and various other atmospherical impurities start a fresh attack of inflammation of the conjunctiva; people affected with this condition of the eyelids are constantly suffering from "inflamed eyes," which render them unfit to carry on the work of their calling.

Every fresh outburst, or continued conjunctivitis, leaves the mucous membrane in a worse condition than it was previously; after the acute symptoms have passed away the granules may become indistinct, if not altogether covered over by the infiltrated sub-conjunctival structures; at the same time the hypertrophied papillæ stand out more prominently upon the surface of the mucous membrane. Subsequently, or it may be from the commencement of the disease, the granules appear on the orbital conjunctiva and in the cornea; in the latter structure they may be seen as opaque cream-coloured spots or patches, surrounded by a hazy area of corneal tissue. This condition indicates the commencement of pannus, the cornea becoming first affected in its upper portion, where it gradually assumes a rough opaque condition (aptly compared to that of ground glass), into which numerous dark red blood-vessels pass; these vessels seem to project above the surface of the cornea. The extension of pannus in the cornea is generally a slow and painless process, but in some cases it is accompanied with marked photophobia, lachrymation, and considerable pain.

It is impossible to predict how long it may take for the disease to run its course, or the cornea become so opaque as to prevent the patient from gaining his living; but it would almost seem that so long as any portion of the conjunctiva, or the anterior layers of the cornea exists, the granules continue to grow in the part, doubtless produced by the irritation caused by the trachoma-coccus in the connective tissue of

the affected structures. As the disease becomes chronic further alterations in the eyelids take place; in some of these cases there is no difficulty in everting the lids, which are nevertheless obviously much thickened, and their surface covered with hypertrophied papillæ; these may have run into one another and formed a tough vascular structure, apt to bleed if roughly handled. In this condition the lids cannot close properly over the eyeball, the puncta are everted, and ectropion frequently supervenes. In other patients we find that it is difficult to evert the upper eyelids in consequence of the growth and contraction of the connective tissue which has been formed in the part during the more acute stages of the disease. The palpebral fissure is narrow vertically, from the abundant production of cicatricial tissue in the neighbourhood of the entrance of the palpebral arteries. In these cases entropion often follows, and the incurved cilia add greatly to the distress which the patient suffers.

Changes such as those referred to necessarily displace or choke the Meibomian glands, their ducts become obliterated, and the retained secretion may become inspissated and calcified, leading to the chalk-like nodules so often seen in chronic cases, not only of granular but also in other forms of conjunctivitis. Another condition often met with in these long-standing cases is the adhesions which form between the inner surface of the lids and the eyeball. These fleshy bands of adhesion are noticed when the lower lids are everted, and the eyeball is then directed upwards; they are formed of cicatricial tissue, and connect the surfaces formerly covered by the tarsal and orbital conjunctiva, and as the secreting structure of the latter has been completely destroyed the adhesions look dry and are sometimes covered with bran-like scales. Alternately, from partial or complete destruction of the normal elements of the cornea, it may yield to the intraocular pressure, and a projection in the form of a staphyloma results. Well might some surgeons have described this affection of the eyes malignant ophthalmia, for when once established it spreads from one texture to another, involving destruction in each and all the parts implicated, and it is almost as irremediable when once it has taken root in the conjunctiva as any form of malignant disease in the tissues which it invades.

ACUTE GRANULAR CONJUNCTIVITIS.—We occasionally meet with cases of granular conjunctivitis in which the disease runs

a rapid course. In instances of this description the granules appear almost simultaneously upon the conjunctiva and cornea, producing extensive infiltration of the tissues. The eyelids, in the course of a week or so, become greatly swollen and thickened, the tarso-orbital folds being completely occupied with fleshy-looking granulations. The cornea is hazy, and a number of well-defined granules may be seen in its substance; pannus forms rapidly, and may extend in breadth several millimeters in a single night. The secretion from the surface of the conjunctiva is profuse, and the patient suffers from great pain in his eyes, and from general feverishness. The prognosis in cases of this description is unfavourable, for although it may be possible to relieve the acute symptoms the cornea seldom regains its natural transparency. In these acute cases the granules are rapidly covered in by the infiltrated conjunctiva, and it is then more from the condition of the cornea than of the eyelids, that we arrive at a diagnosis as to the nature of the affection from which the patient suffers. In the most favourable circumstances the attack rarely subsides within a month or six weeks from its commencement, and not unfrequently passes on into a chronic state, the granules reappearing on the conjunctiva as the swelling in this part diminishes, the granules in the cornea are often so numerous that they are apt to become confluent and then break down, producing rather deep ulcers, and sometimes abscesses. The acute symptoms having passed away, as I before remarked, the cornea is almost always permanently damaged to a greater or less extent; it may, however, continue to clear slowly for some months after the active disturbance has subsided.

Treatment.—From the account we have given of granular conjunctivitis, it is obvious how important it is to recognise the presence of granules in the conjunctiva at an early stage of their growth. In schools, such as the one to which I have referred, it is impossible to over-estimate the advantages to be derived from the examination and isolation of children by a skilled surgeon before admission into such an institution, so as to weed out those affected with granular lids. The treatment of cases, whether in schools, regiments, families, or any other communities, should in the early stages of the disease be conducted on the principle, that granular conjunctivitis is the work of a vegetable micro-organism planted in the affected structures, and that this coccus must be destroyed

if the disease is to be overcome; further, the trachoma-coccus may spread from one person to another, through the discharge from an eye affected with the disease. This contagious property of the discharges from the eyes of an affected person, is retained for any length of time if the matter is kept in a dry condition, as, for instance, on dry linen, and the more acute the attack the greater is the infective power of the matter formed on the surface of the conjunctiva. There seems good reason for supposing that the susceptibility of the conjunctiva to receive and form a favourable soil in which the trachoma-coccus may develop, depends on the healthiness or otherwise of the mucous membrane at the time the coccus reaches it, and also to some extent on the individual's general state of nutrition. Certain chemical substances have the property of exciting the rapid growth of this micro-organism, as, for instance, atropine, which, if frequently applied to the eyes of a person affected with granular lids, may produce an acute attack of conjunctivitis.

Supposing we detect granules and patches of hypertrophied papillæ on the conjunctiva of an individual who has perhaps consulted us on account of some slight irritation in his eyes; our first care, if possible, should be to guard those brought in contact with the patient from infection. This remark applies with equal force to the case of children on admission into a school, although they may not be aware of having anything the matter with their eyes. The basins, towels, and everything likely to be contaminated in any way by the secretion, from the conjunctiva of such a person must be carefully disinfected and guarded; at the same time the food and hygienic condition of the individual should be strictly attended to. Beyond this, in the early stages of the disease we may do much to weaken if not to destroy the organism on which it depends; the best local application for this purpose is the chloride of zinc. The patient's eyelids having been everted should be wiped dry, and then painted over with a solution of chloride of zinc (2 grains to an ounce of water); this should be repeated every morning, and a solution of perchloride of mercury (1 part to 5,000 of water) dropped into the eye three times a day, and the eyelids also bathed with this lotion. Before going to bed at night an ointment (hyd. oxyd. flav. gr. viij, iodoform gr. iij, vaseline ζ ss) should be freely applied to the margin of the eyelids. Treatment of this kind must be employed until all traces of

the granules have disappeared from the eyelids, and even then the individual's eyes should be examined once a week so as to destroy any fresh growth of the disease.

Unless, however, in the case of military or naval surgeons, or those in charge of schools and so on, it is seldom in practice that we meet with cases of granular conjunctivitis in its primary stage. As a rule, we are consulted by patients who complain of having had "weak eyes" for a considerable time, their condition varying between irritation and inability to use the eye in consequence of more severe attacks of ophthalmia. On everting the lids we find indications of granular conjunctivitis with muco-purulent discharge from the eyes, and if pannus has commenced beneath the upper eyelid with considerable photophobia, and, probably pain in the eyes. In cases of this description equal parts of solution of perchloride of mercury (1 to 4,000) and a solution of cocaine (4 per cent.) should be dropped into the eyes three times a day; iced compresses are a great relief if applied over the eyelids for a quarter of an hour at a time, three or four times a day. At bedtime an ointment may be smeared along the ciliary border of the eyelids (hyd. oxyd. flav. gr. viij, iodoform gr. v, vaseline ζ ss), and the ung. belladonna be smeared over the eyebrows and temple; it can be washed off in the morning. The eyes should be shaded with dark, neutral-tint glasses, but the patient allowed to go out as much as possible in the open air. Treatment of this description will usually alleviate the more acute symptoms; and subsequently after the use of a solution of cocaine, the everted lids may be freely dusted every morning with a fine powder, composed of equal parts of tannic acid and iodoform. In some cases, if this plan does not succeed in producing absorption of the exudation and hypertrophied papillary structure, a crystal of sulphate of copper may be applied to the lids every other day, a solution of cocaine having first been dropped into the eyes twice or three times to relieve the pain produced by the application of the sulphate of copper. The length of time such treatment is to be continued must vary with the condition of the conjunctiva. If in the more chronic cases we find that the hypertrophied papillæ form prominent patches, as they often do, surrounded by comparatively healthy conjunctiva, we may, after the application of a solution of cocaine, shave off, or still better, scrape away the enlarged papillæ, and after the bleeding has ceased, paint the raw

surface over with a three per cent. solution of chloride of zinc, subsequently using the solution of mercury and iodoform ointment as above directed. The electro-cautery may be applied with advantage to single granules or to patches of hypertrophied papillæ, doubtless containing granules; but the careful and, if possible, entire removal of the affected tissues, and then the application of the solution of chloride of zinc, or of a crystal of sulphate of copper, more effectually destroys the organisms of granular conjunctivitis than any other means of treatment. If the hypertrophied papillæ are very abundant and widely spread over the conjunctiva we may be disposed to try in the first instance the effect of scarifying the part freely, and subsequently dusting the tissue over with the tannic acid and iodoform powder. Dr. G. L. Johnson has described in the Archives of Ophthalmology a very ingenious method of incising and applying electricity for the cure of granular conjunctivitis.

With reference to the treatment of pannus of the cornea, if slight, it will clear away under treatment such as that recommended for the relief of the conjunctivitis, the mercurial and iodoform ointment being applied to the margin of the lids, and also smeared over the everted upper lid before the patient retires to rest for the night. The mercurial lotion must also be used. In the more severe cases of pannus it has been proposed to inoculate the conjunctiva with gonorrhœal matter so as to excite acute inflammation in the eye, and thereby the reabsorption of the exudation and organised tissue in the cornea. An infusion of jequirity has been used with a certain amount of success to excite inflammation in the eyes of persons suffering from severe pannus. A weak infusion of the seeds of jequirity is to be rubbed over the inverted eyelids. A single application is sufficient to cause a severe ophthalmia in most cases, but if it does not produce this effect the infusion may be applied a second and a third time. The obvious objection to the employment of means of this kind, is that you cannot by any possible treatment always control the inflammation of the eyes when once it has been excited, and in attempting to cure the pannus the cornea and the eye may be destroyed. The same objection applies to cauterisation of the pannus cornea. Our experience has not led us to form a favourable opinion, regarding the plan of excising a zone of two or three mm. in width from the circumcorneal conjunctiva in cases

of pannus; such treatment is seldom followed by any permanent relief in cases of vascular opacity of the cornea.

Operations for the cure of entropion or ectropion should seldom be resorted to for the relief of malposition of the eyelids due to granular lids, at any rate not until either the reabsorption or transformation of the exudation into the connective tissue has advanced so far, that no considerable contraction is to be apprehended after the operation.

With reference to the treatment of acute granular conjunctivitis, we should rely chiefly on the constant application of iced compresses to the eyelids, and the instillation of a solution of perchloride of mercury, 1 to 6,000, with the iodoform and belladonna ointments, to the eyelids and the skin on the temple at bedtime. If only one eye is involved the other eye should be protected by means of a watch glass properly fixed so as to preserve the sound eye from contamination with the matter formed on the diseased conjunctiva. The patient's general health must be attended to, and strict attention paid to disinfecting any articles of linen he may have used, so as to prevent the spread of the disease from one person to another.

TUBERCULAR CONJUNCTIVITIS.—We occasionally meet with cases of tubercular affection of the conjunctiva, and in such patients portions of the diseased structures have been removed, and tubercle and bacilli clearly demonstrated in the part. Tubercles develop in the eyelids as in other parts of the body either as a primary affection, but more frequently it appears to extend from the mucous membrane of the nares through the nasal duct and sac to the conjunctiva, appearing first near the puncta. Whether the disease is primary or secondary, it produces in the first instance granules of the conjunctiva and hypertrophy of the papillæ similar in appearance to those met with in cases of granular conjunctivitis. The swollen villi are perhaps more abundant in tubercular disease, and they cover the whole surface of the conjunctiva, being more vascular, or at any rate more easily made to bleed, than is usually the case in granular conjunctivitis. The bacillus of tubercle, like the trachoma-coccus, evidently finds a soil in the conjunctiva favourable for its growth, and by exciting irritation in the part, it leads to the formation of granules and hypertrophy of the papillæ similar to that described in trachoma. There is this difference, however,

between the two: tubercular affections of the conjunctiva almost always lead to ulceration, whereas the tendency of trachoma is to produce a growth of cicatricial tissue and its consequences.

In most of the recorded cases of tuberculosis of the conjunctiva, there has been enlargement of the lymphatic glands in front of the ear and below the jaw on the affected side; it is remarkable that as a rule only one eye is involved in the disease, whereas in granular conjunctivitis both eyes are generally affected at the same time. Pannus usually appears in the cornea from an early stage of tubercular conjunctivitis.

On everting the eyelids of a person suffering from tubercular disease of the conjunctiva, in its early stages, we notice prominent granules on the mucous membrane, and a number of florid swollen papillæ. The enlarged papillæ soon cover the whole of the tarsal conjunctiva, and become flattened against the surface of the eyeball; between these papillæ there are furrows often filled with muco-purulent matter. As the disease progresses, the surface of the swollen papillæ may ulcerate, and so extensive do these ulcers become that they have been mistaken for rodent ulcers, for lupus, epithelioma, and for syphilitic disease.

The treatment of tubercular disease of the conjunctiva must be based on the fact, that this affection is a constitutional one as well as local, and that hygienic precautions are as necessary in the way of pure air, water, and food, as local treatment. Regarding the latter, the diseased tissues should be completely scraped away, and when the bleeding has ceased, the part painted over with a solution of chloride of zinc, and subsequently covered with the iodoform and tannic acid powder. The solution of perchloride of mercury should be employed as described in the treatment of granular conjunctivitis. So far as our experience goes, we can speak clearly in favour of the injection of Koch's lymph in cases of tubercular conjunctivitis in combination with the treatment above described.

PUSTULAR CONJUNCTIVITIS is an affection of the conjunctiva, which is largely confined to children and young people, depending on some faulty condition of the general health, it not unfrequently manifests itself after measles or other exanthematous fever. We include the "conjunctivitis phlyctenulosa" and "pustulosa." The vesicle, or herpetic

spots of pustular conjunctivitis are in many instances confined to the orbital mucous membrane, but in some cases the vesicles invade both the cornea and conjunctiva at once, or they may surround the cornea like a row of beads; at other times they are situated partly on the cornea and partly on the conjunctiva.

With regard to that form of the disease in which the vesicles are confined to the conjunctiva. In these cases they rarely exceed two or three in number, but are apt to occur in succession one after the other, and consequently worry the patient a good deal. Each vesicle consists at first, either of a simple elevation of the epithelium by a collection of serous fluid beneath it, forming a minute vesicle not larger than a pin's head, or of an equally minute, whitish, nodular mass or pimple, on the summit of which a similar vesicle is quickly developed. These vesicles are always confined to the parts surrounding a terminal nerve. The vesicles are situated on a patch of congested conjunctiva, while the remainder of the mucous membrane may present a perfectly healthy appearance. If several vesicles co-exist on the conjunctiva of the same eye, a large portion, or even the whole membrane, may appear red and inflamed; the vesicles, however, being raised above the surface of the conjunctiva, and of a whitish-yellow colour, are always sufficiently apparent against the red ground. The vesicle may become absorbed in the course of eight or ten days, or the epithelium giving way, a superficial ulcer remains, which in the majority of instances speedily heals; the congestion of the conjunctiva then disappears, and the parts return to their normal condition.

Symptoms.—The symptoms to which this form of pustular conjunctivitis gives rise are usually unimportant, the patient complaining of a sensation of grit or sand in the eye, and of slight pain when the eyeball is turned in the opposite direction to the band of congested conjunctival vessels. After using the eye for a time, it begins to ache and water slightly. Unless the vesicles are situated on the cornea, the patient seldom suffers from much intolerance of light, but comes to us with his eyes wide open, complaining of the above symptoms; he will probably add that his eyelids stick together during sleep. On examining the eye, one or more pustules may be seen on or near the margin of the cornea, the conjunctiva surrounding them being somewhat congested; but with this exception, the eye appears perfectly healthy.

Treatment.—In this form of pustular conjunctivitis, the vesicles and congested portion of the conjunctiva may with great advantage be dusted over with calomel, once a day. The calomel may be most conveniently applied with a camel's-hair pencil, and the eyelids immediately closed and kept shut for a few minutes. This application causes the patient a little pain and momentary irritation. A small quantity of the yellow oxide of mercury ointment should be smeared along the edges of the lids and into the conjunctival sac every night. A solution of boracic acid may be dropped into the eye two or three times a day. But independently of treatment, the tendency of the disease is to get well of itself, unless the patient be in a low and weak state of health, when the pustules are apt to appear in succession, and cause him considerable inconvenience; nor will they disappear until his general health has been improved.

EXANTHEMATOUS CONJUNCTIVITIS.—With reference to conjunctivitis occurring during an attack of measles or scarlet fever, very little need be said, for in the majority of instances, the conjunctivitis disappears as the disease recedes, and no treatment is required. As a general rule, poppy-head fomentations will allay the irritation which sometimes exists, and any transient intolerance of light which may occur is a symptom of no consequence, and can only necessitate the patient's being kept in a dark room for a few days. A weak solution of atropine, one-sixtieth of a grain, to an ounce of solution of boracic acid should be dropped into the eyes three or four times a day. Should any complication occur, such as ulceration of the cornea, a reference may be made to the appropriate heading in the following chapter. In the case of variola, especially in parts of the world to which vaccination has not as yet extended, the destruction done to the organs of vision by this disease is very terrible. The pustules do not form on the cornea during the eruptive stages of the disease; but ulceration and rapid destruction of its tissue are very apt to take place during the stage of secondary fever. This is an important fact in a practical point of view, because it hence appears less necessary to attend to the state of the eyes when the lids are intensely swollen, as they usually are in the irruptive stage of the affection, than subsequently, when the swelling has gone down, and the patient is left in a weak and exhausted condition. The eyes must then be

carefully looked to, and any haziness or opacity of the cornea should be a source of anxiety to the practitioner, for it is extraordinary how rapidly destructive changes progress under these circumstances; the corneal tissue is often broken down and destroyed in the course of a few days, prolapse of the iris following, and too often the complete destruction of the eye.

Treatment.—As a general rule, we must trust more to a tonic plan of treatment than to local means. The patient's strength should be supported by every device at our command; and his eyes may be frequently washed out with a weak solution of corrosive sublimate or of boracic acid, the margin of the lids being smeared over with vaseline at bedtime, to prevent their sticking together. A strong solution of atropine should be dropped into the eye every morning, so as to keep the pupil well dilated, especially if the cornea is already ulcerated. Should the destructive process appear to be advancing, we may puncture the cornea and allow the aqueous to escape, in the hopes of diminishing the intra-ocular pressure.

XEROPHTHALMIA is a very uncommon form of disease, in which the glands of the conjunctiva fail to secrete sufficient fluid to lubricate the surface of the mucous membrane. The conjunctiva acquires a shrivelled, skin-like (cuticular) character; the cornea loses its transparency, and vision thus becomes seriously impaired. It may be relieved by the application of glycerine or castor-oil to the surface of the eye, but we know of no means by which it can be cured. So distressing, however, are the symptoms, that it may be necessary to remove the free edges of the eyelids, and to stitch them together, so as to get them to unite, and so keep the eye constantly excluded from the air.

INJURIES OF THE CONJUNCTIVA.

FOREIGN BODIES ON THE CONJUNCTIVA.—As a general rule, particles of dust, or similar substances, which happen to find their way into the eye, cause a considerable amount of irritation and a profuse flow of tears from the lachrymal gland, which may wash the offending particle out of the eye, or towards the caruncle, upon which it may be found. But this process is frequently thwarted by the patient, who, after a foreign body has found its way into his eye, should seize the cilia of

the lid, behind which it has lodged, and gently draw the lid forward from the globe of the eye, thus facilitating the action of the tears in washing away the offending particle. In place of this, the majority of people commence rubbing away at the lids, and in their frantic efforts to remove the cause of their suffering, drive it more firmly into the conjunctiva.

Should the foreign body happen to be situated on that part of the conjunctiva which is in contact with the cornea, as it rubs against the cornea during the movements of the lids, it excites the most intense pain in the eye. A small foreign body lodged in the retrotarsal portion of the conjunctiva may excite comparatively little irritation; patients now and then come under our notice, suffering from conjunctivitis depending on the presence of a foreign body, which may have been lodged in the conjunctiva for some time, although its existence has never been suspected. Insects not unfrequently find their way into the eye, and may excite the most intense inflammation by their acrid secretions.

QUICKLIME AND OTHER CAUSTIC SUBSTANCES, by their chemical action on the tissues, may destroy the vitality of the conjunctiva, the part sloughs and the wound subsequently contracts as the cicatrix grows, and so produce entropion; and perhaps union of the palpebral and orbital surfaces of the mucous membrane (symblepharon). One of the first things commonly noticed on examining the eye of a patient after lime has fallen into it, is that the cornea has become opaque in those parts which have come in contact with the lime. This haziness may subsequently clear off, but the damage done more frequently leads to necrosis of the cornea, and destruction of the eye. From time to time we meet with cases in which molten lead has run into the eye, and it is sometimes surprising to observe, how effectually the stratum of steam formed over the eye by the heated substance will protect the part from injury.

LACERATED WOUNDS of the conjunctiva are occasionally met with, the mucous membrane being torn to a greater or less extent by some sharp-pointed instrument. A considerable amount of ecchymosis generally occurs; but wounds of the kind usually heal rapidly.

Treatment of Conjunctival Injuries.—If the injury arises from the presence of a foreign body, the offending substance must be at once removed, whether it be an insect, lime, or any other matter. Having applied a four per cent. solution of

cocaine three or four times to the eye, we must, if necessary, evert the upper eyelid (p. 2) and carefully explore the surface of the mucous membrane, including the tarso-orbital and semilunar folds; the conjunctiva round the foreign body often becomes swollen, completely hiding it, unless carefully sought for. When found, there is usually no difficulty in dislodging it from the surface of the conjunctiva by the help of a needle or spud; but if firmly impacted, it may be necessary, with a pair of scissors, to snip off the little fold of conjunctiva in which the foreign body is embedded. The eye should subsequently be closed with a light pad and bandage for a day or two.

In instances where lime has fallen into the eye, the pain it causes is often so great, that it is necessary to put the patient under the influence of chloroform before a proper examination can be made. The eye having been cocanized, the particles of lime must then be carefully removed, being picked off the conjunctiva with a small spatula or needle. The eye should subsequently be syringed with a solution of boracic acid and cocaine, the stream being especially directed beneath the upper eyelid, so as to wash away every particle of lime; subsequently, a few drops of olive-oil containing ten grains to the ounce of iodoform must be frequently dropped into the eye. After accidents of this kind, severe inflammation of the conjunctiva and deeper structures of the eye may take place, and if so must be treated upon the principles laid down for such cases. Hot poppy-head fomentations, together with the instillation of cocine and atropine, will be necessary. If there is much pain in the eye, a subcutaneous injection of one-fourth of a grain of morphia will afford great relief to the patient.

When a portion of the conjunctiva has been destroyed, either from the contact of a caustic such as lime, or from a burn, our first care will be to prevent, if possible, the injured orbital and tarsal surfaces of the conjunctiva from uniting; a most difficult task to accomplish, in which too frequently our best efforts are thwarted, and an intimate union between the surfaces of the mucous membrane occurs. It has been proposed to insert metallic plates between the opposed surfaces in cases of this kind, in order to prevent their union. In slight cases we should endeavour to keep the lids separated from the globe of the eye by means of a piece of lint, soaked in oil and laid between the eyeball and eyelid; but, our best

efforts are generally inadequate to prevent union between the wounded surfaces of the conjunctiva.

SYMBLEPHARON, or adhesion between the palpebral and orbital portions of the conjunctiva, may be either complete or incomplete; in the latter, one or more bands of cicatricial tissue unite the opposed surfaces, and in complete symblepharon, either the upper or lower eyelid, in one or both eyes, is closely adherent to the orbital conjunctiva. This state of things may be caused by an accident which sets up destructive changes in the opposing surfaces of the conjunctiva—as, for instance, diphtheritic conjunctivitis, ulceration, injuries, or burns involving the mucous membrane; but the contact of quicklime with the eye is probably the most frequent cause of symblepharon. Provided the adhesions do not involve the cornea, the patient's sight is unaffected by symblepharon; but under any circumstances, he experiences more or less inconvenience from the constrained movements of the eyeball, consequent on the adhesions, and in many instances from epiphora, the puncta being more or less displaced.

Treatment.—As a general rule, partial symblepharon only should be operated on. In the complete form, unless the cornea is involved, it may be inferred from what has been already said, that we can seldom expect to improve the patient's condition by means of an operation. With regard to partial symblepharon, the bands of adhesion may be divided, and kept from uniting by everting the lid frequently until the surface of the conjunctival wound has healed. In more extensive partial symblepharon, the bands of adhesion should be divided first close to the globe of the eye, the edges of the wound in the orbital conjunctiva having then been united with fine sutures should be allowed to heal. We may afterwards proceed to treat the palpebral extremities of the fræna in the same way.

Mr. Teale recommends the following proceeding in instances of partial symblepharon:—"Having first made an incision through the adherent lid, in a line corresponding to the *margin* of the concealed cornea (*see* Fig. 22, *a*), I dissected the lid from the eyeball until the globe moved as freely as if there had been no unnatural adhesions. Thus, the apex of the symblepharon (Fig. 23, *A*), being part of the skin of the lid, was left adherent to the cornea.

"In the next place two flaps of conjunctiva were formed, one from the surface of the globe near the inner extremity of

the raw surface, the other from the surface of the globe near its outer extremity. I first marked out with a Beer's knife a flap of conjunctiva (B, Fig. 23) nearly a quarter of an inch in breadth, and two-thirds of an inch in length, with its base at the sound conjunctiva, bounding the inner extremity of the exposed raw surface, and its apex passing towards the upper surface of the eyeball. The flap was then carefully dissected from the globe until it was so far at liberty as to stretch across the chasm without great tension, care being taken to leave a sufficient thickness of tissue near its base. A second flap was then made on the outside of the eyeball in the same manner. In making the flaps, conjunctiva alone was taken, the subconjunctival fascia not being included. The two flaps thus made were then adjusted in their new situation (see Fig. 24). The inner flap, B, was made to

FIG. 22.

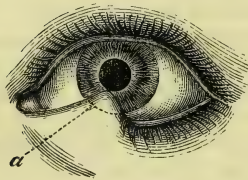
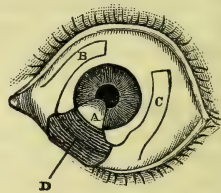


FIG. 23.



stretch across the raw surface of the eyelid, being fixed by the apex to the healthy conjunctiva at the outer edge of the wound. The outer flap, C, was fixed across the raw surface of the eyeball, its apex being stitched to the conjunctiva, near the base of the inner flap. Thus the two flaps were dovetailed into the wound. The flaps having been adjusted in their new position, their vitality was further provided for by incising the conjunctiva near their base, in any direction in which there seemed to be undue tension, and by stitching together the margins of the gap whence the transplanted conjunctiva had been taken—*e.g.*, D, E, Fig. 24. One or two other sutures were inserted, with a view to prevent doubling in of the edges of the transplanted conjunctiva.”

PTERYGIUM consists of an hypertrophy of a portion of the orbital conjunctiva and subconjunctival tissue, which is often vascular, and has usually a triangular shape, the base of the

figure being towards the semilunar fold, and the apex extending to the cornea (Fig. 25). But it by no means follows that a pterygium always spreads from the inner side of the eye; it may exist on the temporal, upper, or lower portion of the conjunctiva; its apex usually projects on to the cornea, in some cases extending over it so far as to interfere with the passage of light through the pupil. In other cases a pterygium, except that it is unsightly, gives the patient no inconvenience. This form of hypertrophy of the conjunctiva is common among the natives of India, and in the majority of cases begins in superficial ulceration of the margin of the cornea, the pterygium commencing at this spot, and gradually extending outwards. In other instances it appears to depend upon the irritation caused by small particles of sand and dust, which, finding their way into the eye, are washed by the tears along the palpebral sulcus to the lacus lachrymalis;

FIG. 24.

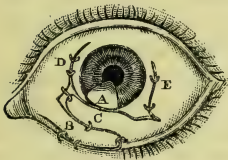
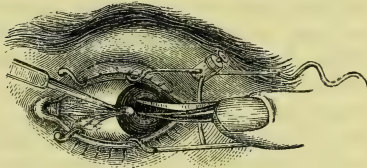


FIG. 25.



the constant irritation thus produced leads to hypertrophy of the conjunctiva at the inner corner of the eye.

Treatment.—The pterygium may be dissected away from the surface of the globe. The eye having been thoroughly cocainised, the eyelids are to be separated with a stop speculum, the thickened conjunctiva is seized with a pair of forceps, or a hook, about midway between the semilunar fold and the cornea, and (Fig. 25) removed from the sclerotic as far outwards as the semilunar fold, and also from the front of the cornea, should it have extended so far; the edges of the wound in the conjunctiva should then be brought together with one or two fine sutures. The success of the operation depends upon our removing the whole of the hypertrophied conjunctiva. After the operation cold-water dressing may be applied to the eye, until the wound of the conjunctiva has healed. We have not, however, found an operation of this

kind by any means certain or lasting in its effects. Should the pterygium grow again, it will be better to dissect up the apex and transplant it downwards, fixing it in its new position with a few sutures; generally after this operation growth ceases, or should it increase it will be in a direction which cannot interfere with vision; another plan is to dissect up the pterygium and double it on itself when shrinkage usually takes place.

SEROUS EFFUSION taking place into the connective tissue of the conjunctiva is by no means an uncommon occurrence among old and anæmic people suffering from a relaxed condition of the mucous membrane; it may be induced by an attack of simple conjunctivitis or some such cause. The effusion generally comes on suddenly, and the œdema may be so great that the conjunctiva bulges forwards over the cornea, having much the appearance of a yellowish, jelly-like mass; there is no purulent discharge from the eye. There is little or no pain in the eye, and although it often happens that the patient is much alarmed as to his condition, we may quiet his fears by assuring him that beyond the slight amount of stiffness caused by the effusion no ill effects are likely to follow. Serous effusion may, however, occur quite independently of old age, from inflammation of the conjunctiva, or of the neighbouring structures, or from remote causes—as, for instance, disease of the heart or kidneys. Excluding these cases, simple serous effusion is a matter of little or no consequence; it generally appears suddenly, and slight pressure over the lids by means of a compress and bandage causes it to disappear after a few hours. Should the œdema be very considerable, we may puncture the jelly-like mass with a needle, and allow the serum to escape, subsequently applying a pad and bandage over the eye.

EFFUSION OF BLOOD may take place into the connective tissue of the conjunctiva, either as the result of a blow or from violent straining—as, for instance, in whooping-cough. It occurs likewise from fracture of the bones of the orbit, and in fact from any cause by which the bloodvessels of the part are ruptured. The effused blood is at first of a deep red colour, usually disposed in blotches of greater or less extent beneath the conjunctiva, often encircling the cornea; as it becomes absorbed various hues of discoloration are

produced. It occasionally happens that the mucous membrane is slightly raised from its normal position by a clot of blood of this kind; under any circumstances it presents a very unsightly appearance, and we are generally applied to for the relief of the disfigurement, rather than of the pain or inconvenience which it causes. Blood effused in this situation is usually speedily absorbed, and the process may be generally hastened by applying a compress and bandage over the eye. Should the effusion depend on the straining efforts made by a person suffering from whooping-cough, it is not likely to become absorbed until the violence of the fits of coughing has lessened. We may, however, safely relieve the minds of friends from any anxiety they may feel as to the ultimate issue of the case.

LYMPHANGIECTASIS OF THE CONJUNCTIVA consists of a number of small blebs not larger than a pin's head; they contain a clear straw-coloured fluid and are situated in the superficial layers of the conjunctiva. They appear to depend on some interference with the flow of lymph and dilatation of the lymph spaces. They disappear as a rule after some weeks' time. Massage may be applied with advantage.

ENTOZOA occasionally grow in the connective tissue of the conjunctiva; hydatid cysts and filaria have been met with in this situation.

GRANULOMATA AND POLYPI.—

Granulomata are occasionally found on the tarsal conjunctiva connected with a Meibomian cyst which has opened on the surface of the conjunctiva. They are generally flat button-like projections of granulations through which a probe may be passed into the cyst. The small fleshy growth should be excised and the cyst beneath it fairly opened and scraped out. Subsequently the yellow oxide of mercury ointment should be inserted between the lids twice a day. Masses of granulation tissue growing from the surface of the conjunctiva sometimes contain a foreign body. A polypus may spring from the mucous membrane of the conjunctiva, appearing generally as a small tumour, but occasionally increasing to the size of a hazel-nut. These growths are usually pedunculated, and are of a light pinkish colour, soft, and in fact presenting precisely the same appearances as similar formations in the nostrils or other parts of the body, with which also they are identical in structure. Polypi in this situation cause the patient no pain or inconvenience unless they attain a con-

siderable bulk. They may be removed with a pair of scissors, being snipped off together with a fold of the conjunctiva from which they grow.

FATTY TUMOURS of small size sometimes spring from the connective tissue of the orbital conjunctiva. These tumours have a yellow, unctuous appearance, and seldom cause any pain or inconvenience to the patient except from their size and unsightly appearance. There is no difficulty in removing them. The tumour must be seized with a pair of forceps, and cut away with a fold of the conjunctiva from which it springs. The eye should subsequently be kept closed with a pad and bandage till the wound has healed.

WARTS OF THE CONJUNCTIVA are occasionally met with. They usually grow from the surface of the mucous membrane, near the margin of the cornea, and are of a greyish colour. Their surface is smooth, and a few fine hairs may be seen growing from them. These small tumours should be excised together with the conjunctiva from which they grow, otherwise they are almost sure to return.

CYSTS OF THE CONJUNCTIVA are rarely met with; they are seldom larger than a pea, and their semi-transparent appearance, particularly when examined by oblique light, at once indicates their nature. These cysts have been known to contain hydatids. A cyst growing in this situation should be completely removed, together with the conjunctiva from which it grows.

EPITHELIOMA of the conjunctiva rarely commences on the mucous membrane of the globe of the eye, but has in many instances been known to spring from the connective tissue of the palpebral conjunctiva. We have already described the leading symptoms of this form of disease and of rodent ulcer when discussing the affections of the eyelids.

SARCOMA growing from the conjunctiva is of rare occurrence. We lately met with an instance of this kind. The cells of the morbid growth being coloured with dark brown, almost black pigment. Growths of this description should be excised as early and completely as possible.

DISEASES OF THE CARUNCLE.—The caruncula lachrymalis is a small, reddish, conical body, situated at the inner canthus of the eye, which is apt to bleed freely; it is composed of a mass of granulating tissue, and is covered by a continuation of the conjunctiva. The caruncle participates in all the affections

to which the conjunctiva is subject; in some cases it becomes chronically enlarged, resembling a small mass of florid strawberry-like granulations springing from the inner angle of the eye. In these circumstances it may extend itself behind the upper and lower lids, and if touched is apt to bleed. After incision we may expect considerable hæmorrhage, and the growth not unfrequently disappears; should it again grow it must be excised. A polypus springing from the caruncle should be snipped off with a pair of scissors, and the surface from which it grew touched with caustic; a little bleeding is apt to occur after this operation, but a sponge pressed firmly over the corner of the eye for a few minutes will stop the hæmorrhage.

CHAPTER V.

DISEASES OF THE CORNEA.

Anatomy — Keratitis — Interstitial Keratitis — Phlyctenular Keratitis — Fascicular — Rheumatic Keratitis — Keratitis Punctata — Suppurative Keratitis — Ulcers of the Cornea — Hernia — Staphyloma — Fistula — Opacities — Pannus — Cornical Cornea — Wounds and Injuries — Senile Degeneration — Leprosy — Calcareous Film — New Growths.

THE CORNEA forms the anterior part of the external coat of the eyeball, being a continuation of the sclerotic, but with its tissue modified so as to become perfectly transparent, and destitute of blood vessels; it is the segment of an ellipsoid inserted into the larger sphere of the sclerotic, in such a manner that the sclera extends further on its anterior surface than on its posterior, and further above and below than laterally, so that the vertical diameter is slightly shorter than the horizontal. The cornea is about 1 mm. thick, being thinnest at its centre, and thickest at its margin.

The cornea consists of four layers:—

The External Epithelium Layer, continuous with the conjunctiva. This consists of eight or nine layers of cells, made up of a basement-layer of columnar cells with well-marked nuclei, several layers of oval or spherical cells, and finally, three or four strata of flattened cells on the surface. Many of the cells of the deeper layers are furnished with minute processes which dovetail into each other.

The proper tissue of the cornea consists of a modified form of connective tissue, arranged in alternating lamellæ running at right angles to each other, sixty to seventy in number. As all the fibres have the same refractive index, it is only by re-agents, or by post-mortem changes, that any

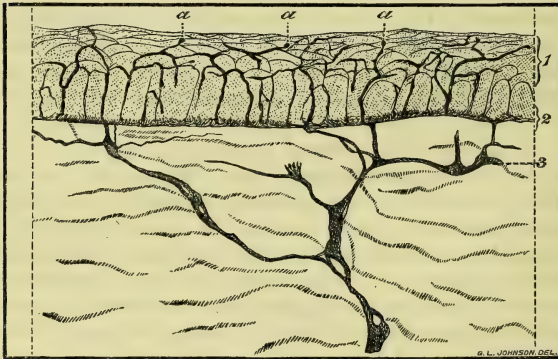
structure can be made out; these fibres are collected into bundles arranged in layers, each layer being separated from the next one by a homogeneous matrix. In this latter lie the cell-spaces; these are many branched flat lacunæ, freely anastomosing with similar lacunæ on all sides, by narrow irregular-shaped canaliculi, and called the lymph canalicular system. They are merely excavations in the matrix, having no lining membrane; each lacuna is almost entirely filled up by a flat cell, the corneal corpuscle. The substance of the cell is prolonged by fine processes, through the canaliculi anastomosing with processes of neighbouring cells. Between the corpuscle or its process and the lacunar wall, there is just room for the passage of lymph and migratory cells, so that leucocytes can pass in this way from one side of the cornea to the other, or even right round the eyeball, since this canalicular system is continued throughout the sclerotic. Moreover, as there is a network of these lacunæ between every two layers of cornea fibres, the amount of lymph circulating through the cornea and sclerotic is very great. Many of the corneal corpuscles undergo distinct amoeboid movements during life. There are no proper lymphatic vessels in the cornea, though the lymphatics of the conjunctiva anastomose at the margin of the cornea with the above-mentioned lacunar system, and the latter carries on their work. The corneal tubes of Bowman have been proved to be artificial products. A narrow layer of the corneal substance immediately beneath the epithelium is destitute of corneal corpuscles and lamellæ, and presents a more uniform appearance than the rest of the cornea.

The Posterior Elastic Lamina (Membrane of Descemet) forms a distinct structureless hyaline layer of uniform thickness throughout, lining the posterior surface of the cornea proper. It is highly elastic, and when partly detached tends to roll inwards on itself. The posterior surface of this membrane is covered with a single layer of cubical or slightly flattened endothelial cells, each having a single oval nucleus.

Nerves of the Cornea.—The cornea is supplied by the ciliary nerves; they enter the sclerotic near the cornea, and after sending branches to the ciliary muscle and iris, form a plexus round its margin. From this network an immense number of non-medullated nerve fibres pass forwards, dividing and subdividing as they approach the epithelial

surface, and finally form a dense network or plexus, distributed equally over the whole surface of the cornea, just beneath the anterior elastic lamina. This primary plexus (Fig. 27) gives off a number of slender fibres which, piercing the lamina, form a secondary plexus immediately beneath the conjunctiva. From this a set of fibres proceed upwards, between the epithelial cells to the surface, and thence curving backwards, form a network in the middle of the conjunctiva. From this plexus the ultimate fibres proceed, ending close to the surface in little bulbous expansions resembling minute Pacinian corpuscles (Fig. 27, *a, a, a*).

FIG. 27.



The proximation of these terminal nerve-bulbs to the surface may help to explain the intense pain and photophobia which exists when an abrasion of the corneal epithelium or an ulcer exposes them to the air or pressure from without.

The cornea is the most important external part of the eye; the chief pathological conditions from which it may suffer, are apt to cause alterations in its curvature or a diminution in its transparency, its prominent position renders it also very liable to accident.

KERATITIS.—Dr. A. Alt in his lectures on the human eye remarks that, from a pathological point of view, parenchymatous, pannus, phlyctenular, and some forms of traumatic keratitis, must all be classed under the type of infiltration-

keratitis. When the infiltration is confined, as is the rule, to the inner part of the cornea, the epithelium remains unaltered; when it affects the lamellæ nearer the surface, the epithelium is always found in a pathological condition. It appears irregular, and lacks its normal lustre and smoothness; microscopically, we find its cells very irregular in shape, granular and much enlarged, so that the whole of the epithelial layer covering the infiltrated portion of the parenchyma is somewhat thickened. This thickening may furthermore be due to serous inhibition, or to proliferation and new formation of cells. The corneal lamellæ surrounding the infiltrated part appear in no way altered. The infiltration may be completely absorbed, and the cornea resume its normal appearance. At times, blood-vessels form from the cells or from protoplasmic offsets (growing from the marginal vessels) which gradually become hollow, and are subsequently lined with endothelium. During the process of recovery these newly-formed vessels usually disappear to the naked eye, but their remains can generally be seen with + 20D behind the ophthalmoscope, in rare cases the vessels remain persistent.

If the infiltration involves the corneo-scleral tissue, it sometimes produces sclerosis, which is erroneously called interstitial keratitis; but is in truth the result of the growth of connective tissue between the lamellæ and into the corneal canals, causing the greyish colour of these parts.

Symptoms.—In cases of keratitis the cornea presents an opaque appearance, either throughout its whole extent, or in parts. In any circumstances, the disease is usually more advanced in one part of the cornea than another. It generally commences towards the circumference and spreads inwards, but as it advances, the part first attacked may become transparent, while another portion of the cornea grows hazy. The diseased portion of the cornea is not only opaque, but its surface resembles in appearance a piece of ground glass; this uneven condition of the anterior layer of the cornea is best seen by focal illumination, and in fact, unless examined in this way, may be overlooked. The immediate effect of these structural changes is to render the patient more or less blind, by interfering with the transmission of light to the retina.

In the active stages of the disease, a part, if not the whole circumference of the cornea, is surrounded by a zone of injected subconjunctival vessels; in addition to these,

numerous minute vessels appear in the cornea, forming a semicircle at the circumference of its upper or lower section, or it may be an entire circle round the cornea. The vessels run from the margin, for about the eighth of an inch inwards, towards the centre of the cornea. By the unaided eye these small vessels cannot be distinguished from one another, and the affected margin of the cornea appears as if it had been stained with a narrow band of vermilion.

The amount of vascularity of the subconjunctival tissue and cornea varies with the intensity and progress of the keratitis. In subacute and chronic cases these symptoms may be wholly wanting; nevertheless, the cornea presents the peculiar ground-glass appearance of keratitis. In the more acute cases the orbital conjunctiva is congested.

The patient may complain of lachrymation, and some intolerance of light, but he is most solicitous about the haziness of vision, of which he becomes painfully conscious if the opacity extend to the centre of the cornea. Intolerance of light and lachrymation are not prominent features in keratitis, so long as the epithelial layer of the cornea is but slightly affected; if these cells become destroyed, and the peripheral distribution of the nerves exposed, not only does the patient suffer from photophobia, but complains also of considerable pain in the eye, and ciliary neurosis.

The natural tendency of keratitis is to terminate in recovery, although the process is frequently a tedious one, extending over a period of several weeks or months, the disorder often attacking first one eye and then the other before it finally subsides; in neglected cases the iris may become involved, a condition which may only be recognized after the cornea has cleared. We may suspect complication of this description, or even the extension of the disease to the choroid, if during an attack of keratitis the patient complains of much ciliary neuralgia and pain on pressure over the ciliary body.

The disease is met with among people of all ages and classes, but the majority of cases occur among young and sickly children; we shall subsequently refer more particularly to instances arising from inherited syphilis. Occasionally it is a consequence of irritation by a foreign body or wound of the cornea.

Treatment.—Counter-irritation in the form of an issue opened in the skin of the temple, or a succession of blisters

established in this situation, are doubtless serviceable, and hasten the reparative process in keratitis. It is necessary to drop a weak solution of atropine into the affected eye, so as to keep the pupil dilated; by this means we diminish the secretion of aqueous, and preserve the iris at rest—both desirable objects in the treatment of these cases. If the eye is irritable it should be kept closed by a bandage, applied over the lids, to be worn during the day, but discontinued at night. The patient's general health must be attended to; tonics, a generous dietary, fresh air and exercise are demanded. In instances arising from the presence of a foreign body in the eye, the offending substance must be removed. If, after an injury, there should be much irritation and pain in the eye, a solution of cocaine must be dropped into the eye three times a day, and cold compresses should be constantly applied.

PARENCHYMATOUS, OR DIFFUSE INTERSTITIAL KERATITIS.—This form of inflammation of the cornea is most frequently met with among young persons, from the age of seven to twenty, who have had syphilitic parents. They usually possess other marks of inherited syphilis, such as scars round the mouth, prominent frontal eminences, deafness, and incisor teeth having an arched cutting edge, these teeth being semi-circular in form and separated from one another. The free extremity of the incisors are devoid of enamel, and they become worn away in the course of time, and so the arched cutting edge of the teeth is gradually ground out. The disease is almost always symmetrical, although it is often more advanced in one eye than in the other, there is no tendency either to the formation of pus, or to ulceration of the cornea in these cases. The disease runs a protracted course, and is very apt to recur, but if properly treated the recovery is not only much hastened, but may be permanent.

Symptoms.—At the commencement of the disease, the patient complains of watering of the eyes, and on examination a slight ciliary congestion may usually be observed; then a faint clouding is seen in the cornea, generally in one or more patches, and there is more or less haziness of vision. The nebulous areas extend, and in the course of a few weeks the whole of the cornea will generally have become “steamy,” or of a ground-glass appearance. Still the opacity is denser in some parts of the cornea than in others, ultimately the cornea becomes so opaque that the iris can no longer be seen. In this stage of the disease iritis and

posterior synechia often occurs. Blood-vessels not unfrequently pass from the ciliary vessels into the cornea; they appear in patches forming the "salmon patch" of Hutchinson. The vessels are very numerous and small, but under a lens may be traced in a straight course from the margin of the cornea towards its centre; the vascular patches not unfrequently take the crescentic form so common in syphilitic affections. The disease may run its course with only moderate conjunctival congestion and with little pain or photophobia; its progress, though slow, tends to recovery, and even in instances where the opacity of the cornea has been great, it may clear away completely. But unless properly treated, synechia, the result of iritis, may render the sight most imperfect; it is quite possible in such cases that the choroid has also become affected.

In tuberculous subjects this form of keratitis is complicated with greater irritability and photophobia; it was difficult in such cases, prior to the use of Koch's lymph, to determine how far the disease was due to syphilis, and how much to tuberculosis, but the reaction in the latter class of cases is marked, and we have seen dense opacities of the cornea clear up under its use.

Treatment.—In syphilitic cases a prolonged mild mercurial treatment is necessary, for months or even years, together with atropine in the more active stages of the disease to prevent the formation of synechia. The form of mercury to be administered must depend on the age and circumstances of the patient. Iron and cod liver oil are frequently required in these cases; and if there is much ciliary congestion and photophobia, in addition to these drugs, atropine should be employed; a seton or succession of blisters to the temple is often useful.

PHLYCTENULAR KERATITIS, or as it has been styled, herpes of the cornea, is exceedingly common; both eyes are usually affected. The disease is most frequently met with among children from six to twelve years of age. On examining the cornea, which may be a matter of difficulty, on account of the spasmodic closure of the lids and intolerance of light which attend the affection, we notice several small white specks on its surface, consisting of vesicles; their contents either become absorbed, or, the epithelium covering them falling off, leaves a small ulcer on the surface of the cornea. These little ulcers involving the superficial layers of the

cornea expose the terminal branches of a nerve and so cause intense photophobia. The vesicles are confined in great measure, to the superficial layers of the cornea, but the abraded surface sometimes takes a considerable time to heal, and is apt to degenerate into an unhealthy ulcer. There is a marked disposition for a succession of these pustules to form, sometimes for months together, rendering the complaint most distressing to the patient, and difficult to cure.

In well-marked cases the cornea is hazy, spots of opacity, corresponding to the vesicles, being scattered over its surface; vessels may also be seen meandering over it from the conjunctival border towards the vesicles. The vessels of the conjunctiva, as a general rule, become uniformly, though not deeply, congested; the subconjunctival tissue is also involved, and its characteristic pinkish zone, surrounding the circumference of the cornea, is often to be seen. The skin about the inner angles of the eyes is apt to become excoriated, from the patient constantly pressing his hands against his eyelids to exclude the light, and from the perpetual flow of tears over the part. This excoriated state of the inner angle of the eye and lower lid often adds much to the patient's troubles; moreover, in many cases, the disease is associated with eczematous or herpetic sores about the nostrils, lips, or cheeks, and it may be with an enlargement of the glands of the neck.

But the most characteristic feature of this form of the disease are the nervous phenomena which attend it—the intense intolerance of light, and spasm of the lids. There may be also considerable ciliary pain, but this is by no means a constant symptom. The photophobia and blepharospasm are intimately associated with each other, the former being referable to hyperæsthesia of the retina, by which a painful sense of dazzling is produced by even feeble light; and the latter, to a morbid reflex action, excited by irritation of the nerves of the cornea, causing intense hyperæsthesia of the retina, of the optic nerve, or both, which is reflected through the portio dura to the orbicularis muscle. There can be no doubt that the impression of light on the retina plays a most important part in exciting this spasm, for it is lessened if the patient be removed into a dark room, when he may succeed in opening his eyes; the relaxation of the muscular spasm, however, is by no means complete, and it therefore seems reasonable to infer that both the optic, and fifth nerve cooperate in its production, just as in the familiar instance of

sneezing, which though generally excited through the fifth nerve, may also, in this affection of the cornea, be determined by a dazzling light.

It is generally possible to diagnose a case of this form of keratitis from the appearance and gesture of the patient, without even examining his eyes; he comes to us with his eyelids firmly closed, his head bent down, and a handkerchief or both hands pressed against his eyes, so as completely to exclude light from reaching the retina. If we attempt to force open the eyelids a gush of tears escapes from them, and the eyeballs are involuntarily turned upwards, the patient making a desperate effort to close his lids, sometimes sneezing violently.

Treatment.—Our treatment must be directed to the improvement of the patient's general health. Cod-liver oil and iodide of iron, together with nourishing food, cleanliness, and fresh air, are the class of remedies upon which we can depend. In place of giving iron, we may commence our treatment by administering a few grains of quinine combined with carbonate of soda twice a day; these drugs may be continued with advantage, together with iodide of iron. Arsenic is sometimes useful in cases where the disease is accompanied with eczema, or other affections of the skin covering the patient's face; in instances of this description, to cure the disease of the skin is to cure the affection of the eyes. Arsenic is administered most advantageously in the form of the liquor arsenicalis, to be taken freely diluted in water, after food. The dose must vary with the age of the patient; for an adult we might order six minims, to be increased to ten, three times a day, until the affection of the skin and eyes begins to improve, or until the characteristic effects of the drug have manifested themselves. Counter-irritation, by means of tincture of iodine painted over the skin of the lids every evening, a succession of small blisters, or what is more effectual, an issue opened in the skin of the temple, are very useful adjuncts to the foregoing treatment.

A solution of atropine and cocaine should be dropped into the eye twice a day.

It sometimes happens that atropine irritates the conjunctiva, in which case the extract of belladonna may with advantage be smeared over the eyebrows twice a day. The patient usually experiences great relief after his pupils have become fully dilated by means of atropine or belladonna, used as above

directed. As soon as the irritation has subsided, calomel should be dusted over the surface of the patient's cornea once a day, until the haziness and vascularity covering it have disappeared. Calomel applied in this way is preferable to the red precipitate ointment, but in the case of irritable nervous children the latter application may perhaps be more easily managed. The ointment should be applied once a day; the lower lid being everted, a small piece of the ointment is to be deposited on its surface, and the eye then kept closed for a few minutes, the lid may then be again everted and the remains of the ointment wiped from its surface by means of a bit of soft rag.

FASCICULAR KERATITIS is a variety of the phlyctenular form, and consists usually of a single ulcer, which commences near the edge of the cornea, and has a very distinct dense band of parallel vessels going to it. This ulcer shows a great tendency to travel from the margin to the centre of the cornea, ulceration extending by its central edge, and dragging with it its leash of vessels. As the ulcer extends below the anterior elastic lamina into the true corneal tissue, it leaves a scar, when healed up, which is apt to be most marked at its central part.

The great object of our treatment must be to stop its progress before it reaches the central part of the cornea, when it may cause great impairment of vision by the opacity left behind; should it not answer to the ordinary treatment of ung. flav. dil. with atropine and cocaine, together with tonics internally, it may be necessary to cocainise the eye and then apply the electric cauterly, or the solid nitrate of silver, to the ulcer itself; or the vessels may be divided where they pass from the conjunctiva on to the cornea.

RHEUMATIC KERATITIS.—Whatever the cause of rheumatism it evidently has a marked tendency to produce hyperæmia of the connective-tissue series of structures, and among them the sclerotic and cornea. Rheumatic sclero-keratitis is most frequently met with among persons advanced in life; we seldom see both eyes affected at the same time. It by no means occurs only among persons who are victims to constant attacks of rheumatism; on the other hand, we have often met with this affection of the eyes in individuals who have hardly suffered from rheumatism in other parts of the body.

Rheumatic keratitis commences with pain in the affected eye and congestion of the sclerotic zone of vessels extending

from the cornea outwards. This zone in the early stages of the disease is similar to that seen in instances of iritis; it has the same purplish tint. The vessels of the conjunctiva are more or less congested, but there is no muco-purulent secretion from its surface, as in catarrhal conjunctivitis, nor is there the feeling of grit or sand in the eye commonly complained of in cases of conjunctivitis. But there is a deep-seated throbbing pain in the globe which extends over the temple, cheek, and along the side of the nose, and is worse at night; the skin becomes extremely tender over these parts of the face and forehead, the coats of the various branches of the temporal artery, and even of the vein, appears to be tense. The pupil is contracted, but in the early stages of the disease it responds to the stimulus of light, and dilates freely under the use of atropine. There is always some increased tension of the eyeball; the globe is also very tender if pressure is applied to it. When the eye is inverted or everted, so as to stretch the tendons of the recti muscles, the patient complains of a good deal of pain.

Should the disease continue unchecked for two or three weeks, or it may be sooner, we shall find that in places the epithelial layers of the cornea are hazy, at the same time the zone of sclerotic vessels has advanced over the margin of the cornea. This condition of keratitis is apt to be overlooked, because the opacity of the cornea is at first faint, and there is so much photophobia and intolerance of light that it is difficult to obtain a good view of the eye. On making a rapid inspection it is quite possible to mistake the dull appearance of the iris, seen through the altered cornea, for iritis, especially as the sclerotic zone of vessels is well marked. But on careful examination of the eye the muddy appearance of the iris will be found to depend on opacity of the cornea rather than upon a turbid state of the aqueous; nevertheless, if the disease has existed for some time, inflammation of the iris supervenes, and the pupil is fixed and irregular. The existence, however, of synechiæ may not be discovered until the acute symptoms have subsided, and the cornea has regained its transparency.

Superficial ulceration of the cornea is often met with in the progress of this affection of the eye, but we have not seen perforation, or, as a rule, the collection of pus between the layers of the cornea in instances of rheumatic sclero-keratitis.

In the early stages of this disease the patient is often feverish, his temperature rising to perhaps 101° at bedtime,

his tongue is furred, and the pain at night so severe as to prevent him from sleeping. There is loss of appetite and much depression of spirits, not only in consequence of the constitutional disturbance, but also from the tedious course which the disease usually runs.

The treatment of this affection of the eye must depend largely on the degree of tension of the globe of the eye; if it be increased, avoid the use of atropine or cocaine, for either of these drugs applied to the surface of the conjunctiva may instantly induce an attack of acute glaucoma. A solution of eserine applied to the eye twice a day is often useful in cases of this description. If there is no increased tension of the eyeball we should still advise caution to be exercised in the application of a solution of atropine to the eye; if it causes no accession of pain or tension the drug may be used; and, in such a case the employment of the belladonna fomentation often relieves the symptoms. At the same time the patient's bowels should be freely acted upon by a few doses of blue pill and rhubarb, and the following draught taken every six hours: Potass. Iodid. gr. iij, Soda Salicylate (natural) gr. xv, Vin. Colch. ℥x, Aqua ℥j; 20 grains of soda bicarb. may with advantage be ordered at bedtime in half a tumbler of water. After all acute symptoms have subsided, should we find that synechiæ have formed, it may be necessary to perform an iridectomy in order to prevent recurrent iritis.

KERATITIS PUNCTATA, or as it is sometimes called Descemetitis, is not a keratitis at all, it is characterized by the presence of a number of small spots, scattered over the posterior elastic lamina of the cornea, consisting of patches composed of lymph and proliferating epithelium. The spots are usually arranged in the form of a triangle having its base downwards and its apex near the centre of the cornea. This condition of the cells of the posterior elastic lamina is usually complicated with some amount of general haziness of the cornea, which by interfering with the passage of light to the retina, renders the patient's sight very imperfect. The opaque epithelial cells are shed from time to time, and may sometimes be seen in the aqueous, which becomes, in consequence, more or less turbid. Keratitis punctata occurs in patients suffering from inflammation of any part of the uveal tract, the most frequent cause being serous cyclitis.

Symptoms.—During the early stages of the disease, only

slight pain is felt in the eye, with dimness of vision. There is a zone of injected vessels surrounding the cornea, and usually a considerable amount of conjunctival congestion, the opaque spots on the posterior surface of the cornea are best seen by focal illumination. The aqueous appears somewhat muddy, and flakes of degenerated epithelium are occasionally seen floating about in it; some of these may be deposited on the iris, giving it a speckled appearance. But we have, superadded to the abnormal state of the cornea, symptoms indicative of disease of the deeper structures of the eye, such as increased tension of the globe, and ciliary neurosis, intolerance of light, and inability on the part of the iris to respond to its natural stimulus, or to the action of weak mydriatics.

The course of this form of disease is unfavourable under any circumstances; the cure is always a very protracted one, and we should be careful not to give a favourable prognosis until we are sure that the deep structures of the eye are unaffected.

The Treatment resolves itself into the use of much the same means as those recommended in cases of iritis and irido-choroiditis. (See Chap. VI.)

SUPPURATIVE KERATITIS includes abscess and ulceration of the cornea, and is characterized by so great an increase in the cell infiltration, or exudation into the cornea, that its structure is destroyed to a greater or less extent.

Acute Suppurative Keratitis is attended with considerable lachrymation, often violent pain in the affected eye, extending to the eyebrow and temple, and is most commonly the result of injury; the wound possibly becoming infected by some septic matter contained in the conjunctival sac. The patient complains of intolerance of light, and the conjunctiva is usually much congested, and often considerable chemosis exists, concealing the injected zone of vessels which surrounds the circumference of the cornea. The cornea itself is hazy, and as the disease advances suppuration takes place in its laminated structure. The pus thus formed may escape externally, giving rise to an ulcer, or may burst into the aqueous chamber forming hypopion; lastly, it may gravitate downwards between the layers of the cornea to its inferior section, forming a yellow opaque patch, resembling in form and size the white mark seen at the root of the finger-nails, and hence the term *onyx*. The superior border of this collection of

matter is convex, and being situated between the layers of the cornea, it does not change its level as an hypopion does, when the patient bends his head over to one side.

The course which this disease pursues depends on the situation of the abscess; if superficial, the pus usually makes an opening for itself externally, and comparatively little injury is done to the cornea; the pressure of the aqueous from behind not only tends to force the matter outwards, but also to keep the walls of the abscess in apposition when empty, so that the cavity occupied by the pus is thus effectually closed, leaving however a more or less opaque patch in the cornea. Should it happen, however, that the haziness, though slight, is near the centre of the cornea, the patient will complain grievously of the impairment of vision which it produces.

If the abscess is situated deep in the laminated tissue of the cornea the matter is prone to spread among the corneal fibres, and by pressure inflict irreparable damage to its structure; or it may force its way between, and separate the posterior elastic lamina from its attachments. The chances of its finding a vent into the aqueous chamber, through the posterior elastic lamina, are small, for an opening in the latter membrane is immediately closed by the outward pressure of the aqueous. In these circumstances the diseased action will probably spread to the iris and deeper structures of the eye. In cases of this kind we can generally best determine the condition of the parts by the focal method of illumination; the posterior layer of the cornea will be seen bulging backwards, and often touching the iris, and flakes of lymph may usually be observed floating about in the muddy aqueous humour. The fibrous structure of the iris will be more or less hazy, and the pupil, in all probability, refuses to dilate when atropine is applied to the eye; or if the iris acts, the pupil may assume all manner of shapes from the existence of synechia. Under these circumstances, the pain in the eye and side of the head, from which the patient suffers, is often excruciating.

The prognosis in this class of cases, is unfavourable, for if the posterior elastic lamina be involved, general inflammation of the globe of the eye may at any time be excited. In other cases, the suppuration and destruction of the cornea continue until it can no longer resist the intra-ocular pressure, the degenerated structure gives way, and the contents

of the eyeball escape; or if the rent in the cornea has not been very considerable, prolapse of the iris and a staphyloma may occur.

The Treatment of abscess of the cornea must be conducted upon the same principle as that of a similar collection of matter in any other part of the body. If the pain and ciliary neurosis are very great, as is usually the case, warm fomentations may be constantly employed, and the subcutaneous injection of morphia beneath the skin of the temple must be resorted to. A solution of atropine should be applied to the eye every six hours. Whenever matter forms in the cornea, the sooner we make a dependent opening into the part the better, so as to allow the pus to escape externally. In some instances the matter is thick and will not readily flow through an incision in the cornea; if this is the case, a small scoop should be introduced into the abscess, and its contents evacuated. The incision in the cornea should take an oblique direction, to avoid the risk of running the point of the instrument into the anterior chamber, which is undesirable, because the presence of the aqueous is serviceable in keeping up pressure from behind, and forcing the pus out through the external opening which we have made in the cornea. The patient generally experiences relief when the matter has been allowed to escape; subsequently hot poppy-head fomentations may be used three or four times a day, and in the intervals an ointment composed of morphia, belladonna, and Indian hemp should be smeared over the eyelids, and the eye kept closed with a light pad or bandage. Should it appear that the iris has become involved, the treatment of the abscess in the cornea must still be conducted upon the principles above detailed; but we shall have to use frequent instillations of atropine, in order if possible to dilate the pupil as speedily as possible.

In some instances of suppurative keratitis, the tendency of the affection is to spread rapidly from the original seat of the disease, and yet the pain and irritation in the eye may have subsided. In this dangerous class of cases a solution of sulphate of eserine should be instilled into the eye three times a day. A firm compress and bandage may be applied over the closed eyelids, but should the compress increase the pain from which the patient suffers it had better be discontinued, and iced compresses must be constantly employed.

Subacute Suppurative Keratitis differs from the acute form

of the disease, in that there is no marked appearance of inflammation in the part, nor does the patient usually complain of much pain or photophobia. It is most commonly met with among persons in a debilitated state of health; we see it for instance after cholera, starvation, or small-pox, especially among children, and it then pursues a rapid course. The disease commences with the appearance of one or more patches of exudation and suppuration, situated in the laminated tissue of the cornea; these spots extend rapidly, they coalesce, and in the course of a few days, or it may be hours, a considerable portion of the cornea is involved. The further course of the disease depends upon the extent and rapidity with which the degenerative changes progress, and also upon the position of the accumulated matter. If the pus has formed in the anterior layers of the cornea, the abscess may burst externally; but should it occupy the deeper layers, so as to involve the posterior elastic lamina, it is probable that the diseased action will extend to the iris and choroid. The conjunctiva is then usually much congested, and the destruction of the cornea frequently progresses rapidly.

The Treatment to be followed in these cases must be directed towards the restoration of the nutritive powers of the patient, so as, if possible, to stay the destructive process going on in the cornea. In all probability we shall have to resort to stimulants, a nutritious diet and tonics. Among the latter, the tincture of muriate of iron, given in twenty minim doses, with a grain of sulphate of quinine, every six hours, will sometimes be beneficial.

Should a collection of matter take place in the cornea, it must be evacuated as soon as possible, in the manner already described. These cases are occasionally influenced for good by a compress carefully applied over the eye. With regard to the compress, it is seldom likely to be beneficial if it increases the pain in the eye; we must then slacken the bandage, or leave it off for several hours during the day, and use poppy-head fomentations. Unfortunately our best efforts are too often unavailing, the destructive changes in the cornea advancing so rapidly, that we have no time to improve our patient's health. The affection, moreover, having a constitutional basis, both eyes are often involved, so that the condition of the patient is hopeless.

KERATITIS FROM NERVE LESIONS.—This form of keratitis arises from defective innervation of the cornea, in consequence of which its nutrition is impaired, and degenerative changes such as those above described occur. The most common cause of this form of the disease, are wounds or injuries affecting the superficial branches of the fifth nerve. Thus we occasionally see rapid destruction of the cornea take place, apparently from the irritation caused by a foreign body lodged in the folds of the conjunctiva. Injuries affecting the origin or trunk of the nerve may induce a similar train of symptoms which, when once begun, generally defy our efforts to stop their progress.

In cases arising from peripheral irritation of the nerve, we may, by the removal of the cause, put a stop to its injurious effects on the cornea. M. Snellen considers that in the analogous case of ulceration of the cornea, apparently arising from injury of the fifth pair, it is from the particles of dust and dirt which then find their way into the eye, that the destructive changes arise. He asserts that if, after injury of the nerve, the eyelids are kept perfectly closed, should ulceration occur at all, it is very partial in its effects.

Dr. Sinitzin, on the other hand, considers that after injury to the fifth nerve, neuro-paralytic phenomena occur whether the eye is protected or not; he states that, having studied the effects of ablation of the superior cervical ganglion of the sympathetic upon the eye, in a large number of experiments, he has arrived at the following results:—Immediately after the ablation of this ganglion, increased vascular injection was constantly observable in the fundus of the eye of the same side. Ophthalmoscopic examination showed that the choroidal vessels had increased in size, that their anastomoses had become much more distinct, and that in general the fundus was of a much deeper red on the operated than upon the sound side. The temperature of the eye of the operated side rose. In the sac of the conjunctiva and beneath the capsule of Tenon the difference in temperature amounted to as much as 0·9 to 2·4 per cent. The cornea of the side operated upon possessed, when compared with the other, a much greater capability of resistance to the action of foreign and neutral substances. If, for instance, a fine spicula of glass was inserted to an equal depth into each cornea, it always happened that, whilst on the sound side the spicula excited more or less violent conjunctivitis, pannus, purulent infiltration of the cornea,

with subsequent ulceration and ultimate disintegration of the adjoining tissue, or a more or less severe iritis and threatening of panophthalmitis—on the operated side either scarcely any reaction occurred, which was most commonly the case, or at most it was slight. It was also observable that, as Claude Bernard has shown, the stronger the animal the greater the difference in the temperature, and the sooner after the operation the foreign body is inserted, the greater is the resistance exhibited by the sound side. The well-known neuro-paralytic phenomena, consequent upon section of the fifth nerve in the skull, immediately in front of the Gasserian ganglion, do not occur if shortly before this operation, or immediately after it, the cervical ganglion is removed. Even when some of these neuro-paralytic phenomena have made their appearance after section of the fifth, ablation of the ganglion will cause them to vanish in the course of a few (two to four) days. Such disappearance is possible so long as the surface of the cornea remains moist and polished; if these conditions have supervened, separation of the epithelium, haziness of the cornea, as well as injection and swelling of the iris, they will no longer disappear. The complete atrophy or destruction of the eye, consequent upon section of the fifth, may still be staved off if the ganglion be removed during the progress of the changes, the conditions present either remaining *in statu quo* or undergoing more or less improvement. The ulceration of the lips, especially of the lower one, following section of the fifth, as well as the ulceration of the eyelids, completely vanish after section of the sympathetic. For the improvement taking place under the four last heads it is not requisite for the animals to have any special protection from injury afforded. In Dr. Sinitzin's opinion, the neuro-paralytic phenomena after division of the fifth occur whether the eye of the side operated on is protected from irritation or not. The diminution of temperature, observed by various experimenters on the same side after section of the fifth, never occurs when ablation of the sympathetic ganglion has been simultaneously performed. Dr. Sinitzin says that the changes in the circulation appear to be at the bottom of these effects. Ligature of the carotid, or irritation of the depressor nerve of the heart, neutralizes the inhibitory effects of the ablation of the sympathetic ganglion upon the neuro-paralytic phenomena consequent on section of the fifth.

The treatment in these cases, when suppuration is estab-

lished, is to be conducted upon the same principles as in the case of abscess; it may be necessary to perform an iridectomy in order to save the transparent portion of the cornea.

In herpes zoster frontalis a number of small vesicles may form on the cornea, which burst and become ulcers with more or less infiltration; the disease is usually accompanied with very severe pain, and healing takes place very slowly; the cornea may remain anæsthetic for some time after the healing is complete. These cases are due to a lesion of the Gasserian ganglion.

ULCERS OF THE CORNEA.—So far we have considered the various forms of infiltration keratitis. It remains to refer to those cases of keratitis accompanied with destruction of the superficial parts of the cornea. Ulcerative, differs from non-suppurative keratitis in that the loss of substance of the cornea leads to scars, which may vary much in density and size; when the opacity is superficial and slight, it may be described as a *nebula*; when dense, as a *leucoma*. The ulcer may vary in every possible way, it may be acute or chronic, superficial or deep, transparent or opaque, vascular or non-vascular, circular, irregular or serpiginous, and it may occupy any part of the cornea. Should perforation of the cornea occur, the aqueous escapes, the lens comes in contact with the posterior surface of the cornea, and if it remains long in this position, the danger is that the cells of the capsule of the lens may proliferate at the point corresponding to the perforation, forming a permanent opacity in that position; this goes by the name of pyramidal cataract; or the iris may fall into the perforation and become permanently fixed there, forming an anterior synechia, the condition left is often spoken of as *Leucoma Adherens*.

The symptoms of ulceration of the cornea vary much in different cases, according as they are acute or chronic, superficial or deep; some of the following symptoms are, however, usually present in a more or less pronounced form:—(a) Some loss of vision; (b) Photophobia and blepharospasm; (c) Lachrymation; (d) Congestion of the palpebral and orbital portions of the conjunctiva with or without ciliary congestion; (e) Pain and tenderness in and around the eye.

The pain and congestion are usually most prominent in adults, and depends a good deal on the acuteness of the case. The photophobia and lachrymation are, as a rule, most marked

in children, being often quite out of proportion to the amount of the mischief, and most marked when the ulceration is superficial; we often find that any attempt to examine the cornea causes a rush of tears, and sets up severe blepharospasm, with perhaps sneezing, which is of a reflex character.

Causes.—Ulceration of the cornea, except when the result of an accidental abrasion, usually indicates that the patient is out of health.

Prognosis.—This will depend more upon the depth and situation of the ulcer than upon its being either of an acute or chronic character. Thus, even a subacute ulcer, from its long continuance, may involve the posterior elastic lamina, and ultimately set up lesions in the deeper structures of the eye; though such complications are doubtless more liable to occur in cases of acute ulceration, because the latter has a marked tendency to spread, not only in circumference, but also to the deeper layers of the cornea.

Again, the course of acute ulcers being more active, when once they begin to heal, reparation goes on favourably; but whenever there has been loss of substance in the cornea, whether by acute or subacute ulceration, more or less opacity of the part will remain; and should this opacity happen to be situated in the axis of vision, the patient's sight must be impaired. Much may perhaps be done by forming an artificial pupil, but still the injury inflicted by the ulcer is lasting. Unfortunately, this does not represent the whole risk of corneal ulceration; we have not only to fear the formation of cicatricial tissue in deep ulcers of the cornea, but also that the attenuated cornea at the seat of ulceration may give way before the intra-ocular pressure, and that a staphyloma of the cornea and iris will occur.

The situation and depth, therefore, of the ulcer are important points to consider in forming a prognosis; superficial ulcers may heal, and the parts recover their normal transparency, but the effects of deep ulcers of the cornea are never overcome. Should the latter not extend to the centre of the cornea, they may still be comparatively harmless; but if, from thinning of the cornea, a staphyloma takes place, this, by involving the iris, as we shall subsequently explain, is apt to occasion serious mischief, if not absolutely to destroy the eye.

Treatment.—It will be evident from what has been said regarding the prognosis, that our main object in treatment must be to prevent, if possible, the ulcerative process from

extending either in depth or area ; for such extension must result in loss of transparency in the cornea. In most instances of ulceration (excepting traumatic cases, or those depending on conjunctivitis), the patient's general health will be found at fault ; in no affection of the eye is it more necessary to attack the disease by improving the assimilative and nutritive functions of the body, and, as a general rule, a tonic and supporting plan of treatment is demanded. Iron and quinine, good food, cleanliness, and fresh air are the fundamental requisites for the cure of almost all instances of ulceration of the cornea, whether they be acute or chronic.

The local treatment must consist in the application to the eye of a solution of atropine, 2 grains to the ounce of water, three or four times a day, and where the photophobia is great, the combination of atropine with cocaine in equal proportions, may be of the greatest benefit. In some cases a better effect is obtained from a solution of eserine (2 grains to the ounce), instilled into the eye in place of the atropine ; this is especially the case in spreading ulcers and those which are breaking down quickly, the eserine seems to check the escape of leucocytes and lowers the tension of the eye. Both eyes require shading, and when the ulceration is acute, a pad and bandage may be applied with advantage ; we thus give support to the eye and at the same time save the cornea from the constant friction of the lids.

When the pain is very acute and does not readily give way to local applications of atropine, cocaine, and hot belladonna fomentations, a hypodermic injection of morphia may be given ; the aim of all this is to ensure rest to the cornea ; when the ulcer is of a chronic character it may be stimulated with advantage ; this can be best done by touching the ulcer lightly with the electric cauter, by the application of the yellow oxide of mercury ointment, or the solid stick of nitrate of silver. Sometimes counter irritation does good either in the form of a seton in the temple, or a succession of small blisters behind the ears or over the temples.

When perforation of the cornea threatens, paracentesis of the anterior chamber may be performed with advantage.

In performing paracentesis of the cornea under these circumstances, the point of the needle should just be allowed to pass through the floor of the ulcer into the anterior chamber, otherwise the iris, or even the lens may be wounded.

It is by no means necessary to wait until the deeper

layers of the cornea are involved before performing paracentesis, for we thus limit the opening in the cornea to that of the size of the needle we introduce, in place of having a large rent through the bottom of the ulcer. The puncture should be made so that the aqueous escapes slowly. If, after puncturing the ulcer, we notice, in the course of a few days that its base is again bulging forward, and likely to burst, the operation may be repeated, and it may require to be done even a third time. After the paracentesis, the eye must be carefully closed with a light compress and bandage.

When the ulcer shows great tendency to extend quickly over the surface of the cornea as well as deeply into its substance, and presents a grey floor which is opaque in places and accompanied with hypopion, Saemisch recommends that the ulcer should be divided with a Graefe's knife in the following manner:—The point of the knife is entered just beyond one margin of the ulcer, and then passed through the anterior chamber behind the ulcer, and brought out in healthy cornea on the opposite side of the ulcer, and the section slowly completed, thus dividing the ulcer and infiltrated cornea beyond. The aqueous and pus are thus evacuated from the anterior chamber, the progress of the mischief is arrested, and healing soon commences.

HERNIA OF THE CORNEA consists in a protrusion of the posterior elastic lamina through the outer layers of the cornea, which may have been destroyed by ulceration. The elastic lamina has considerable power in resisting destructive changes, and hence, after the laminated tissue of the cornea has been destroyed, it may remain unaffected, and being forced outwards by the pressure of the aqueous, form a little glassy-looking nodule, projecting from the corneal surface. The transparent appearance of the tumour, bulging through the jagged border of the ulcer, is sufficiently characteristic to enable us at once to recognise the nature of the disease.

From the extreme thinness of the posterior elastic lamina, it necessarily follows that, when a hernia of this kind has occurred, the slightest force applied to the eye is likely to rupture it. Hence herniæ of the cornea are of short duration, and seldom come under observation, the posterior elastic lamina usually giving way before the distending force of the aqueous, the corneal hernia being replaced by a prolapse of the iris. It occasionally happens, however, that the hernia

remains for some weeks, and then gradually becomes converted into cicatricial tissue.

Treatment.—The patient having been placed under the influence of chloroform, and a stop speculum adjusted, a broad needle should be run through the cornea, and the instrument being tilted on its edge, the aqueous is allowed to escape slowly from the eye. The needle is then to be removed, and a solution of atropine dropped into the eye, a compress and bandage being firmly applied over the closed lids, and kept there for forty-eight hours. The eye may then be examined, but it will be better to re-apply the compress, and continue its use for some days. It may be, that on opening the lids at the expiration of forty-eight hours, we find the hernia of the cornea reproduced, in which case the paracentesis must be repeated, the compressing band and the caustic pencil being applied. This treatment will excite sufficient inflammation in the part to set up material changes in the ulcer, and although a cicatrix will remain as a permanent blemish, still, its formation may prevent a prolapse of the iris with its attendant evils.

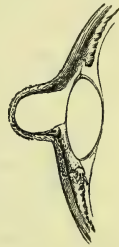STAPHYLOMA OF THE CORNEA.—If the resisting power of the fibrous structure of the cornea has been destroyed, or considerably weakened by the ulcerative process, the remains of the laminated tissue, together with the posterior elastic lamina, are likely to yield to the distending force of the aqueous; and bulging forwards, to a greater or less extent, they form a staphyloma of the cornea, which is very disfiguring.

From their relative positions, it follows, that when a partial protrusion of the cornea occurs, the iris is apt to be carried forward into the protrusion. Moreover, in the majority of these cases, a small opening occurs at the most prominent part of the staphyloma, through which the aqueous drains away; or the aqueous may percolate through the attenuated portion of the cornea; in either case, the anterior chamber being emptied, the vitreous forces the lens, and with it the iris, forwards against the cornea. The iris thus frequently becomes fixed to the inner surface of the protrusion (Fig. 28), while its outer surface acquires a coating of fibrous (cicatricial) tissue, and thus the staphyloma ultimately assumes a dense opaque appearance.

Staphylomata of this kind vary much in size, sometimes being so large that they protrude between the eyelids, at other

times they are no larger than a pin's head. The thickness of their walls is also subject to variation; in many instances the summit of the staphyloma is very thin, whereas in other cases it is comparatively thick, and may contain cholesterin imbedded in it. The apex of the staphyloma may ulcerate, and a fistula form, through which the aqueous drains away; or the staphyloma may burst open, and through the rent thus made, the lens, and, in fact, the contents of the globe, escape; the eyeball then shrinks up, and sinks into the orbital socket.

FIG. 28.



It sometimes happens that more than one staphyloma exists in the same cornea. This condition arises from the previous formation of several ulcers in the cornea, which have accordingly yielded at more than one spot to the intra-ocular pressure, while the intermediate parts, retaining their fibrous structure, have effectually resisted the distending force, forming bands between which the several small staphylomata have occurred.

The symptoms to which a staphyloma of the cornea gives rise consist principally in various degrees of impairment of vision, depending upon its position and size. When endeavouring to estimate what may be the ultimate effect of a staphyloma on the patient's vision, the condition of the iris is one of the first points for consideration, in instances where a portion only of the cornea is involved. Should the iris have been drawn into the protrusion, it is very probable that the pupil may likewise be included in the staphyloma, and the patient will not be likely to see much with an eye so affected. In other cases a part of the pupil may remain free, and should there be any transparent cornea in front of it, the patient may still retain a fair amount of sight. Again, supposing the staphyloma leaves the centre of the cornea clear, it is far less likely to impair the sight than if situated in the axis of vision. It is by no means an uncommon circumstance, however, for glaucomatous changes to occur in an eye in which a staphyloma has become developed; the degree of tension of the eyeball must therefore be carefully attended to in cases of this kind. In addition to all this, there is danger of sympathetic trouble in the other eye.

Treatment.—This will depend on the size of the staphyloma and the length of time it has existed.

If the protrusion be a small one, and of recent formation, the best thing we can do is to puncture the inferior part of the staphyloma with a broad needle, so as to allow the aqueous to escape, and then apply a firm compress and bandage over the eye; the instillation of atropine should also be employed. Our first object in this proceeding will be to empty the anterior chamber; the intra-ocular pressure being thus removed, the compress may possibly prevent a re-formation of the staphyloma, until cicatricial tissue has formed, which retains the parts in their normal position.

If the staphyloma is a large one—involving, say, a quarter or more of the cornea, we must resort to an iridectomy, as the surest means of treatment. If this be neglected, it is probable that the iris and pupil will subsequently be drawn into, and become attached to the cornea; we anticipate this evil, by excising at once a fourth of the iris from behind the clearest portion of the cornea, we release the iris from its attachment, and by diminishing its secreting surface lessen the quantity of aqueous formed, so that we may hope, by the careful application of a compress and bandage subsequently to the iridectomy, to reduce the dimensions of the staphyloma itself; and beyond this, prevent glaucomatous changes from taking place in the eye. Besides the immediate advantages to be derived from this proceeding, we must bear in mind the fact, that if the iris becomes permanently involved in the staphyloma, it may possibly give rise to sympathetic irritation in the other eye; this is therefore an additional reason for resorting as early as possible to iridectomy in this class of cases.

In instances of large and old staphylomata, in which a portion of the cornea remains transparent, a similar plan of treatment must be adopted. In the first place, it will be necessary to apply atropine to the eye, in order that we may discover the state of the pupil, whether it remains partially open, or has been entirely occluded and dragged into the staphyloma. In the former case, it will dilate under the influence of atropine, and, if practicable, we must form an artificial pupil.

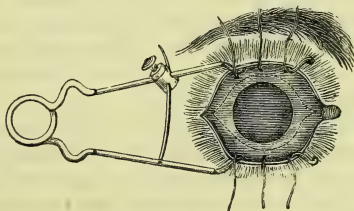
In instances of staphylomata involving the whole of the cornea (Fig. 29), and being an inconvenience to the patient, not only on account of their unsightly appearance, but also by interfering with the action of the eyelids, either of the following operations may be performed. In many cases

the most suitable operation, and the one accompanied by the least disfigurement, is *evisceration* with the introduction of a glass sphere into the bare sclerotic, this affords a good prominent, moveable stump; this operation will be subsequently described.

The eyeball may be removed entirely in the ordinary way, or *abscission* may be performed as follows:—

The patient having been placed under the influence of chloroform, a stop speculum is adjusted, and the surface of the globe having been thoroughly bathed with a solution of corrosive sublimate, the surgeon transfixes the globe of the eye with a couple of needles armed with carbolised sutures in a line corresponding to the ciliary processes (Fig. 30). The staphyloma is fixed with a pair of toothed forceps, and that part of the globe of the eye anterior to the suture is to be

FIG. 30.



removed with a knife or a pair of scissors. The ends of the suture are then to be tied, so as to bring the edges of the wound in the sclerotic together, the speculum removed, and antiseptics applied to the eye. As a rule, however, it is better to remove the staphylomatous eye entirely, rather than to abscise the front of it. Or in most cases *evisceration* is a suitable operation.

FISTULA OF THE CORNEA is an occasional though very rare sequence of ulceration; the opening through the cornea usually takes an oblique direction, and is prevented from healing by the constant drain of aqueous through it. No sooner does perforation of the cornea take place, than the iris and lens are thrust forward, and should the capsule come in contact with the internal opening in the cornea, it is likely to give rise to partial capsular cataract. But more

serious consequences may be expected to follow if the fistula remains open; for the constant dribbling away of the aqueous diminishes the intra-ocular pressure, and gives rise to anomalies in the circulation through the choroid and retina, terminating, probably, in extensive disease of the fundus of the eye. Anterior synechia, again, may form in instances of fistula, from the contact of the iris with the cornea; and when this has taken place, irritation of the iris is apt to be induced, and, extending to the choroid, may compromise the eye, and involve the sound one in sympathetic irritation. A fistula of the cornea may arise from other causes than ulceration, as for instance a penetrating wound which has been prevented from entirely closing by the drain of aqueous through it. But from whatever cause produced, the fistula may at any time lead to complications such as those I have mentioned above. We can seldom overlook the existence of a fistula of the cornea; its external orifice may generally be seen, a minute drop of aqueous oozing through it when gentle pressure is made on the globe of the eye. The depth of the anterior chamber is much diminished, and in many instances the iris is thrust forwards against the posterior surface of the cornea.

Treatment.—Fistulous openings in the cornea are difficult to heal, on account of the drain of aqueous through them; the lens, moreover, being thrust against the internal orifice of the cornea, keeps up irritation in the part, tending yet further to interfere with the healing of the fistula. In cases of this kind, the best plan of treatment is to administer chloroform, and having separated the lids with a spring speculum, to pass a blunt-pointed needle, with a cutting edge, through the fistula, and incise the whole thickness of the cornea from above downwards, and from side to side. The edges of a crucial incision of this kind will fall into accurate apposition; and if a compress and bandage be carefully applied, it is more than probable they will heal in the course of forty-eight hours and the fistula be cured. Before resorting to this treatment, we may be inclined to try what a simple compress and bandage, applied over the closed lids, will do, a solution of atropine at the same time being dropped into the eye twice a day, in order, if possible, to dilate the pupil. In addition to this, the external orifice of the fistula may be touched with the electro-cautery.

OPACITIES OF THE CORNEA.—Opacities of the cornea vary greatly in extent and density, as well as in their permanency, according to the circumstances which have given rise to them. The opaque condition may amount only to a milky cloudiness, extending over the whole cornea, or it may be confined to certain portions of it; and may be limited to the superficial layers, or occupy the substance of the proper corneal tissue. In other cases, following considerable loss of substance in the cornea, the opacity is much denser. The denser variety of opacity is described as *leucoma*; hazy, semi-opaque forms are called *nebulae*.

Epithelial and interstitial opacities, depending on the presence of cellular infiltration, may in time clear away more or less completely, and we shall have the better reason to expect such a result the more recent the affection, and the younger and more vigorous the patient. On the other hand, whenever there has been loss of corneal substance, which has been replaced by cicatricial tissue, restoration of transparency is impossible. Such new formations, however, are often surrounded by a margin of cloudy opacity, which may clear away spontaneously.

Prognosis.—The chief points for consideration, in forming a prognosis in instances of opacity of the cornea, are the situation and extent of the structural changes that have taken place. For the reasons already stated, a dense leucoma can never be removed, and if it be situated in the axis of vision, our main hope will rest in forming an artificial pupil should any part of the cornea remain transparent. If the leucoma, on the other hand, is eccentric, and the pupil in its normal position, the opacity will be of comparatively little consequence. It generally happens, however, that the border of a leucoma shades off into a nebulous area, and if this extends in front of the pupil, it may be almost as detrimental to the perfection of vision while it lasts as a denser opacity would be.

In the case of *nebulae*, where the cause which gave rise to them is no longer in operation, and the patient young, we may look for a disappearance or great diminution in the opacity; but this must be a work of time. If situated in the laminated tissue, or in the posterior layer of the cornea, *nebulae* may be easily overlooked, unless the part is carefully examined by the focal method of illumination. We cannot, therefore, be too careful in exploring these parts, when

dimness of vision is complained of ; for opacities, though so faint that they are with difficulty detected, may be sufficient to obstruct the passage of rays of light, and so offer serious embarrassment to distinct vision.

Slight opacities of the cornea, if of long duration, may induce myopia. The haziness of the transparent media, by diminishing the clearness of the visual image, causes the patient constantly to exert his accommodative power in the vain effort to attain distinct vision.

Corneal opacities in hypermetropic eyes may combine to produce strabismus by lowering the visual acuity in one eye, and thus diminishing the stimulus for binocular vision.

The Causes which give rise to opacities of the cornea are numerous. Glaucoma, for instance, may render it hazy, by increasing the tension of the eye. In certain forms of iritis, the posterior layers of the cornea are involved, and this may give rise to opacities. Granular lids and the various forms of inflammation and ulceration of the cornea are frequent causes of leucomata or nebulæ.

Chemical agents again, by destroying the vitality of the tissue, may induce opacity of the cornea. Acetate of lead, applied as a lotion to the eyes, by chemical decomposition with the lachrymal secretion, may be converted into carbonate of lead and become deposited on the cornea in the form of a permanent opacity, especially if its surface happens to be ulcerated or uneven at the time the lotion is used. In like manner, nitrate of silver, if long used as a lotion to the eyes, may stain the cornea and conjunctiva black. Opacities of the cornea, again, may be induced by the deposit of earthy matter on its surface.

Wounds and injuries, which cause loss of substance, must, in healing, give rise to nebulæ, while slight mechanical violence may be followed by only temporary opacity. But of all these causes of loss of transparency, ulceration, and mechanical irritation from trachoma of the palpebral conjunctiva are the most frequent.

Treatment.—In a case of leucoma, as we have already remarked, it is impossible, by any remedial agencies, to remove the opacity. We may often do much towards restoring the patient's sight by means of an artificial pupil, but so far as the cornea is concerned, time is required to produce improvement. If the leucoma is of recent formation, it is possible that the hazy rim of cornea which usually sur-

rounds it will gradually disappear, and thus the extent of opacity diminish.

In cases of nebulæ, time will often effect a cure, especially among young people; but we may sometimes hasten the process by the application of a lotion containing one grain of iodine, and two of iodide of potassium, in an ounce of water, a few drops to be instilled into the eye twice a day. Should this lotion cause any irritation, it must be discontinued for a time. If the opacity is superficial, the cornea should be dusted over with calomel every other morning. The dilute yellow oxide of mercury ointment, weak astringent lotions, and in fact a multitude of so-called specifics, have been employed from time to time to cure these opacities of the cornea.

Opacities of the cornea arising from stains, such as that caused by nitrate of silver, can hardly be removed; a weak solution of cyanide of potassium has been recommended and may be tried for want of any more efficient plan of treatment. The opacities produced by deposits of carbonate of lead are more manageable. The eye must be cocainised and a stop speculum having been applied, the eye is to be fixed with a pair of forceps, and the surgeon may then scrape off the deposit of carbonate of lead from the laminated tissue of the cornea with a broad needle. A few drops of oil should be dropped into the eye after the deposit has been removed, and the lids kept closed with a pad and bandage for a few days. The same treatment may be adopted in cases of a deposit of earthy matter formed on the surface of the cornea. The opacity has the appearance of occupying a superficial position, and of being very slightly raised, but the surface reflects the light as brilliantly as other parts of the cornea. These opacities come on gradually, and are caused by a deposit of the salts of lime beneath the epithelium of the anterior layer of the cornea.

It has been proposed to tattoo opaque spots in the cornea; and there can be no question as to the fact that this proceeding not only improves the appearance of the affected eye, but also diminishes the diffusion of light thrown on the retina in instances of opacity of the cornea; but is apt to set up dangerous irritation in the eye. The operation of tattooing the cornea is performed as follows:—The lids having been separated with a speculum and the globe of the eye fixed, a number of small oblique punctures are made into the cornea

with a sharp-pointed hollow spud, or needle, which has been dipped in fluid Indian ink. The speculum should be left in the eye till the ink has dried in the cornea. The operation may have to be repeated several times until the requisite amount of the white spot in the cornea has been dyed black.

PANNUS consists of an opacity of the cornea, usually most marked at its upper half and frequently limited entirely to this part, the opacity is composed of connective tissue, with large vessels which are developed on the anterior surface of the cornea immediately below the epithelium; the vessels are usually large, tortuous, distinct from one another, and directly continuous with the conjunctival vessels; the epithelium covering the affected part is somewhat irregular. (See page 97.)

The most common cause of this disease is chronic granular conjunctivitis; the friction produced by the uneven surface of the upper lid rendered irregular by the granulations as well as by the cicatricial changes which take place during the healing process, probably have much to do with the production of pannus; great variety will, however, be found in different cases; in some, where the granulations are plentiful, and the scarring of the inside of the lids considerable, and where, in fact, the friction must be of an aggravated form, but little pannus may exist; whereas, in other cases which seem much milder, the pannus may be more marked, therefore it is probable that in addition to the friction some other cause exists in the production of pannus; possibly, some corneæ resist friction much better than others, or there may be some extension or possibly inoculation of the granular inflammation from the surface of the lid into the cornea.

Sometimes the pannus is so thick and vascular that it has quite a raw fleshy appearance, rendering the outline of the cornea indistinguishable.

Another form of this disease occasionally met with is *Strumous Pannus* (tuberculous); this variety is most frequently found in children, it may affect any part of the cornea and is not limited to its upper part; the abnormal process appears to extend into the corneal tissue below the anterior elastic lamina.

The appearances of pannus are so characteristic that it cannot easily be mistaken for keratitis.

The Treatment of vascular opacity of the cornea will depend upon the cause of the disease; for instance, if arising from

trichiasis, or entropion, the inverted cilia or margin of the lids must be either removed, or restored to their normal position, before we can hope to overcome the disease; and if we can only succeed in getting rid of the source of irritation, we shall have every reason to expect that the condition of the cornea will improve. In many instances of pannus, consequent on granular conjunctivitis, in the early stages of the disease, by destroying the granulations and dusting the eye with equal parts of tannic acid and iodoform, much of the opacity of the cornea will clear away. In old standing cases the contraction of the cicatricial tissue following these affections shortens the lids from side to side, so that they press unduly and irregularly against the eyeball; this, together with the roughness of their surfaces, irritates the cornea during the movements of the eyelids. Under these circumstances we must endeavour, in the first place, to correct this shortening of the eyelids, and for this purpose it will be necessary to divide the external commissure as described at page 42. By this proceeding we not only elongate the palpebral fissure, and directly relieve the pressure exerted by the contracted eyelid on the cornea, but having divided some of the fibres of the orbicularis muscle, we weaken its action, and this again tends to lessen the pressure of the lids on the eye. Provided we can, by this proceeding, sufficiently relieve the friction of the palpebral conjunctiva against the diseased cornea, the pannus will probably disappear to a great extent without further treatment; this desirable result is, however, frequently hastened if tannic acid be dusted over the cornea every morning, until the opacity diminishes, when it may be used every three or four days.

In cases of pannus occurring in tuberculous patients, we have found injections of Koch's lymph produce marked and favourable action on the cornea. The doses should be small, half to one milligram, and repeated according to the extent and length of the local action.

Supposing, however, that no favourable results follow this treatment, or that the condition is due to some other cause than tuberculosis or contraction of the eyelids, we may still hope to improve the state of the cornea, by inducing inflammation in the diseased eye. The more vascular the cornea, the less danger is there of suppurative inflammation being followed by destructive ulceration. The state of the patient's general health should be attended to before submitting

him to this plan of treatment, for if he happens to be in a weak condition, sloughing of the cornea is more apt to occur. There is seldom any difficulty in exciting purulent inflammation in the diseased eye; but in some few instances the conjunctiva has been so completely altered in character, after long-continued granular conjunctivitis, that we have been obliged to inoculate it with pus several times before purulent inflammation could be established.

The pus employed for inoculation may be taken from the eye of another person suffering from purulent conjunctivitis, or gonorrhœal matter may be used. It should be placed on the everted lower lid, and a few slight punctures in the conjunctiva be made with the point of the lancet, so as to insure the grafting of the matter. In the course of thirty-six hours the purulent matter grows rapidly, causing first irritation and inflammation, followed by purulent discharge.

So long as the cornea remains free from ulceration we may allow the inflammatory process to run its course, simply keeping the eye scrupulously clean. If ulceration of the cornea supervenes during the progress of the disease, we must strictly follow out the treatment recommended in cases of purulent conjunctivitis. It is interesting to watch the effects of the inflammatory process on old-standing vascular opacities of the cornea; they often improve remarkably as the suppurative action subsides, and ultimately the patient may regain some amount of vision. After the inflammation has entirely passed away, chlorine water may with advantage be dropped into the eye three or four times a day: it appears to act as a mild stimulant, and is certainly a useful remedy in cases of this kind.

Inflammation may also be produced by infusions of jequirity seeds, and is more easily controlled than purulent ophthalmia.

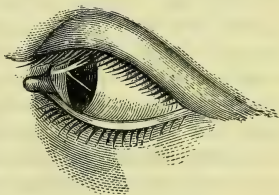
PERITOMY.—This operation consists in excising a band of conjunctiva and subconjunctival tissue about the eighth of an inch broad, extending entirely round the circumference of the cornea and close up to its margin, so as to cut off the communication between the vessels of the conjunctiva and those covering the cornea. The patient being under the influence of ether, the lids are to be widely separated with a spring speculum, a fold of conjunctiva is to be seized with a pair of toothed forceps, and with a pair of curved scissors an incision is carried through the conjunctiva round the cornea.

The band of conjunctiva is now to be dissected off, together with the subconjunctival tissue down to the sclerotic. The lids are then to be closed and covered with a compress and bandage. This operation is well suited for severe cases of pannus which continue *after* the granulations of the lids has been cured; but our experience of it has not been very encouraging. The great advantage of this operation is, that it is quite free from risk, which is more than can be said for the treatment by inoculation or by jequirity.

CONICAL CORNEA OR KERATOCONUS consists in a thinning and bulging outwards of the whole or a part of the cornea, without loss of transparency. It sometimes appears as an abrupt cone rising from the centre of the cornea, or the protuberance may be eccentric, but, as a general rule, the whole of the cornea is involved, its centre forming the most prominent part of the cone (Fig.

31). It necessarily follows, under these circumstances, that the refraction of the rays of light entering the eye is greatly increased, and they are brought to a focus anterior to the retina; the patient is therefore myopic. As a general rule, the disease appears between the ages of fifteen and twenty-five.

FIG. 31.



It does not occur as a sequence of inflammation, but more commonly manifests itself in weak and sickly subjects, and generally progresses with equal rapidity in both eyes, though it may advance more rapidly in one than the other.

In conical cornea, although the protuberance is often considerable, the cornea seldom gives way; it seems probable that as the laminated tissue becomes thinner it allows of a freer transudation of aqueous fluid through its substance than in health, and the intra-ocular pressure being thus relieved, there is not the same tendency that there otherwise would be, for the attenuated tissue to rupture, and give exit to the contents of the eyeball. There can be no doubt of the fact, that as the first step in this change, the laminated tissue of the cornea yields to the intra-ocular pressure, apparently from an inherent weakness in its fibrous structure; but that when the consequent attenuation has reached a certain limit,

the balance is restored by exosmosis, and further distension prevented. These alterations in the resisting powers of the fibrous layers of the cornea advance most rapidly in its central portion, and degenerative changes occasionally occur in this situation, which render it more or less opaque; but with this exception, notwithstanding the very remarkable alteration of form which the cornea undergoes, it remains transparent.

The rapidity with which the disease progresses is variable; sometimes it makes rapid strides, and in other instances takes years to advance. These variations, however, will much depend on the state of the patient's health; any cause which impairs the nutrition of the part, or which induces congestion of the choroid, and increased intra-ocular tension, will tend to augment the protrusion. Excluding such disturbing causes, the disease will generally advance to a certain point, and then remain stationary for years, or it may be for life.

Symptoms.—Besides the alteration in the appearance of the eye, conical cornea gives rise to impairment of vision, the degree of which depends very much upon the extent to which its curvature has been altered. In the early stages of the disease, the patient probably complains of slight, but gradually increasing myopia, consequent on the increased refractive power of the dioptric media. This defect may be corrected for a time by the use of concave glasses; but as the disease advances, not only is the refraction so much augmented that concave glasses cease to rectify the evil, but even before the disease has reached this stage, the altered curvature of the cornea, which is seldom equal in all its planes, gives rise to astigmatism. This again, if stationary, may be partially corrected by cylindrical glasses. Should the degenerative changes continue to progress, opacity of the central portion of the cornea gradually supervenes, and the eye is destroyed.

Conical cornea may be detected in marked cases by simple inspection, or by focal illumination, the bulging forwards of the cone will be most distinct if the cornea be viewed in profile; in slight cases of the disease the ophthalmoscope or Placido's disc must be called to our aid. Retinoscopy gives us a shadow which on moving the mirror seems to run round the cornea in a circular manner; by the indirect method of examination we shall see a distorted image of the disc, this distortion is much increased by slight movements of the objective; with Placido's disc the image of the rings formed

on the cornea are smaller than when formed on a normal cornea, besides undergoing a good deal of alteration in shape, being more or less drawn out according to the increase in the curve of the cornea.

Treatment.—Our first and obvious duty will be to supply the patient with concave or cylindrical glasses, to correct his error of refraction, and thus prevent, as far as possible, all straining of the eyes, which tends to produce intra-ocular congestion and increased tension of the globe. In selecting glasses, the rules ordinarily applicable to cases of myopia and astigmatism hold good.

In the second place, we must do all in our power to improve or maintain the patient's general health. Lastly, we may lessen the secretion of aqueous, in bad and advancing cases, by iridectomy, the upper section of the iris being removed; nor should this operation be long delayed if its full advantages are to be gained. We do not assert that iridectomy will stop the progress of the affection, but in its early stages it affords us the best chance we have of checking it, especially in instances where the disease is making rapid progress.

Von Graefe recommended the following proceeding in cases of advancing conical cornea. The pupil having been fully dilated with atropine, a narrow-bladed knife is to be thrust into the middle layer of the cornea, at the apex of the cone, and then passed out again, so that a small superficial flap may be made. The anterior chamber is not to be punctured, but only the outer layers of the cornea raised and turned back, the flap thus formed being cut off at its base with a pair of scissors. If the cornea should by chance be punctured, the operation must be put off for a few days until the wound has healed. The day after the operation, the surface from which the flap of cornea has been removed is to be touched with a pencil of dilute nitrate of silver (nitrate of silver one part, nitrate of potash two parts), at first very lightly; this proceeding must be repeated every other day until an ulcer surrounded by a halo of infiltration is procured. The anterior chamber is then to be cautiously opened through the base of the ulcer. The perforation is repeated daily for three or four days, and then the eye is bound up, and the ulcer allowed to heal. The result is the flattening of the excessive curvature, and the formation of a leucoma at the part of the cornea most affected. It may be necessary to displace the pupil subsequently by means of iridectomy. With reference

to operations of this kind, it is almost unnecessary to remark that they should only be practised in advancing, or extreme cases of conical cornea.

Another operation which may give a good result, is the removal of a small elliptical piece of the whole thickness of the cornea at the point of the cone.

WOUNDS AND INJURIES OF THE CORNEA.

ABRASION OF THE CORNEA.—A foreign body, striking the surface of the cornea, may scratch off a portion of its epithelium. These corneal abrasions are often followed by acute pain in the eye, and sometimes, in neglected cases, by destructive inflammation. The patient usually comes to us with the eye firmly closed, suffering from considerable pain, lachrymation and photophobia, and complaining of a sensation as if a foreign body were lodged in the eye. The moment the lids are opened a gush of tears takes place from the eye; the palpebral and orbital portions of the conjunctiva will be found more or less congested. If the eye is cocainised and the cornea examined by focal illumination, we may notice that the abraded portion has a glistening appearance, and is surrounded by a slight ridge, occasioned by the free margin of epithelial cells bordering the injured part. The outline of the excoriation is generally irregular, and its size will vary according to the extent and nature of the injury. An abrasion of the cornea, if it occurs in a healthy person, and is properly treated, generally heals in the course of three or four days; the epithelium is re-formed, and the parts assume their normal condition. But if the patient be out of health at the time of the injury, or if the case be carelessly treated, simple abrasion may induce troublesome keratitis, even leading to ulceration or abscess of the cornea.

Treatment.—In a case of abrasion of the surface of the cornea, it is well to open the lids and drop some solution of cocaine into the eye, which may be repeated every two hours, apply a pad of cotton-wool and bandage, so as to keep the parts at rest for twenty-four hours. If after this the patient continues to suffer from pain, it will be advisable to drop a solution of atropine and cocaine into the eye, and order poppy-head fomentations to be employed frequently, the pad and bandage being applied in the interim. After an accident

of this kind, if the irritation has run on to inflammation or ulceration, we shall have to treat the case upon precisely the same principles as those we have already laid down, when discussing the subjects of keratitis and ulceration of the cornea.

CONTUSIONS OF THE CORNEA resulting from direct injury are uncommon, nevertheless, cases of contusion of the cornea do occur, and in old and sickly people are at times followed by rapidly advancing destructive changes in the part, independently of complications, such as detachment of the retina or choroid, which are likely to take place under the same circumstances. After contusion, the cornea may rapidly assume a hazy appearance, the patient suffering great pain in the eye, the conjunctiva becomes deeply congested; in unfavourable cases, these changes may run on into suppurative keratitis, in spite of our best efforts to prevent it; and if necrosis of the cornea commences under these circumstances it will almost certainly terminate in the destruction of the eye.

PENETRATING WOUNDS OF THE CORNEA, provided they are not complicated with prolapse of the iris, will, if their edges fall into accurate apposition, usually heal rapidly. On the other hand, wounds with jagged edges, or those accompanied with loss of substance, heal with difficulty; and, as a rule, an opaque cicatrix remains to mark their position on the cornea, and materially interferes with the patient's sight if it be situated in the axis of vision.

The complication which principally interferes with the healing of wounds of the cornea is a prolapse of the iris, preventing the apposition of the edges of the wound, and thus involving the iris to a greater or less extent in pathological change. Unfortunately, in extensive wounds of the cornea, it is often impossible to replace the iris in the anterior chamber: if it be thus replaced, the aqueous, accumulating, is apt to burst open the edges of the wound, and as the fluid escapes, the elastic vitreous pushes the lens and iris forwards against the cornea, and a further prolapse occurs.

Treatment.—Theoretically we might suppose, that to dilate the pupil with atropine for a central wound, or to contract it with eserine, for a peripheral one, and so drag the iris away from the wound in the cornea, would be a rational and effective plan of treatment. Unfortunately, the iris will seldom

dilate under the influence of mydriatics, however powerful they may be, if the anterior chamber is empty, and the iris compressed between the cornea and the lens. Atropine and cocaine, therefore, although they should always be employed, are not often of much use in extensive wounds of the cornea; in small ones these drugs may be useful, as it is possible that the pupil may then be made to dilate, and the edges of the wound in the cornea falling into apposition, the aqueous is retained, when the full effects of the drugs may then be induced, and so keep the iris away from the rent in the cornea.

In instances of wounds of the cornea not complicated with prolapse of the iris, a solution of cocaine and atropine should be dropped into the eye, three or four times a day; it tends to soothe the irritation, and, together with a carefully applied pad and bandage, keeps the eye at perfect rest. In severe wounds, whether they be contused or incised, we should be prepared to find that detachment of the retina, or some such complication, has occurred in the deeper structures of the eye.

If the wound in the cornea is a *small and recent* one, and a nodule only of iris protrudes through it, we may be able to return it into the anterior chamber. Under these circumstances it will be well to puncture the prolapsed iris with a broad needle; we thereby relieve any slight congestion of its protruding vessels, and allow the aqueous to escape from behind it—both important points to be attained; atropine must then be applied to the eye, and a pad and bandage carefully adjusted. But we cannot expect success from this proceeding in large wounds of the cornea, where a considerable extent of the iris is prolapsed; and even if we excise the prolapsed iris, as above directed, there is always a risk that the wound in healing will retain a portion of the iris in the cicatricial tissue, which may be the means of setting up sympathetic irritation in the sound eye—a disaster against which the surgeon can hardly be too much on his guard. The method of treatment which is most generally applicable in these cases, is to perform an iridectomy, removing the protruded portion of the iris, and thus preventing the chance of a further prolapse, or the ill consequences arising from the iris becoming involved in the cicatrix. But in performing an iridectomy under these circumstances, we must bear in mind the fact that there is no anterior chamber, the lens being thrust against the posterior surface of the cornea; to make an iridectomy, therefore, the patient must be placed

under an anæsthetic so as to relax the muscles, and the section in the cornea should be performed with a narrow-bladed knife, which should transfix the margin of the cornea only. If, as will certainly be the case in most extensive wounds of the cornea, a traumatic cataract exists, and the patient retains only a perception of light, the sooner the globe of the injured eye is removed the better.

FOREIGN BODIES IN THE CORNEA.—Particles of dust, bits of coal, straw, and such like substances may find their way into the eye, and becoming fixed in the epithelial layers of the cornea, excite irritation, pain, and intolerance of light, together with profuse lachrymation. There is generally but little difficulty in detecting the presence of a foreign body on the cornea, if the eye is cocainised and the part examined by the lateral method of illumination; and the sooner an offending particle is removed from this situation the better, for the patient by constantly rubbing at the lid, is apt to drive the offending substance deeper into the cornea, and it may then give rise to severe inflammation of the eye. Its removal is greatly facilitated by instilling into the eye a drop or two of cocaine solution.

When consulted in cases of this kind, the surgeon should seat his patient in front of a good light, and standing behind him, with the aid of an assistant, he should keep the eyelids wide open, the patient being at the same time directed to look steadily forwards; with a small spud or cataract needle, the surgeon may then pick the offending particle off the cornea. If it happens to have been a little bit of iron or coal, or in fact any substance likely to stain the cornea, although the particle is detached, the discolouration may remain. We should not attempt its removal, it will wear away in the course of a few days, as new epithelial cells are formed.

Cases of Impaction.—The foreign body may, however, strike the cornea with sufficient force to be driven deeply into the laminated tissue, and it then gives rise to the most severe irritation, and it may be, inflammation of the eye. The hyper-action thus induced may become localized around the offending particle, and suppuration taking place, it is gradually loosened from its position by the disintegration of the surrounding tissue, and so cast out of the eye. An ulcer thus formed usually heals tolerably quickly, a small nebulous

spot remaining to indicate the position the foreign body occupied. In other cases no such localization of the inflammation occurs around the offending particle, but spreading from the seat of injury it gradually involves the whole cornea, and ultimately the deeper tissues of the eye, terminating in general inflammation of the globe.

When called to attend a case where a foreign body has become impacted in the cornea, our first duty is obviously to remove it as soon as possible. Having cocainised the eye, the point of a cataract needle or spatula being inserted beneath the foreign body, it is to be lifted from its position. It is surprising how firmly particles of iron or dust may become wedged into the laminated tissue, and it often requires the greatest patience on the part of both surgeon and patient to dislodge them. Mr. Snell, of Sheffield, has had much experience among workmen employed in iron and steel factories, and he finds that in cases where chips of either of these metals have become firmly impacted in the cornea that an electromagnet is most useful in drawing the chips out of the structures in which they have become embedded. After removal, the eyelids must be kept closed for a day or two with a pad and bandage. If the foreign body has given rise to abscess or suppuration of the cornea, the case must be treated upon the principles already laid down with reference to these affections (page 134).

It does not often happen that foreign bodies become encysted in the cornea, but occasionally we meet with instances of the kind. Thus, a grain of gunpowder, or some such substance, becomes embedded in the cornea, and probably gives rise to some slight irritation in the first instance; this gradually subsides, and the particle remains encysted, causing no further inconvenience.

Perforation of the Cornea.—We sometimes meet with instances in which a chip of steel, or other hard substance, has been driven against the cornea with sufficient force to perforate it, the inner extremity of the foreign body wounding, perhaps, the iris and lens. It is upon a consideration of the size and position of the particle, and the complications to which it may give rise, that our prognosis and treatment must be based. If the foreign body is a large one, it will excite much more irritation and inflammation in the eye than a smaller one would do. So again with regard to its position—if, in the axis of vision, it will almost

certainly injure the cornea to such an extent as to interfere with the subsequent perfection of vision.

So far the features of such a case are sufficiently obvious ; but it requires a certain amount of experience, and a careful study of the parts, to determine if a foreign body, which has perforated the cornea towards its circumference, has wounded the iris or lens. In most cases where the cornea is thus transfixed, the aqueous escapes, and the iris and lens are thrust against the inner extremity of the foreign body, and thus placed in imminent peril.

The intense pain, intolerance of light, and lachrymation to which these more serious injuries of the cornea give rise, render it necessary to cocainise the eye thoroughly before making our examination. The lids having been separated we must examine the seat of the injury by focal illumination ; the position and relations of the foreign body are thus to be carefully studied. If the iris is in its normal position, being well away from the cornea, the aqueous humour still fills the anterior chamber, and the inner extremity of the foreign body, unless it be of some considerable length, may not have wounded the iris or lens. In these circumstances the case will be a comparatively simple one, provided no deep-seated inflammation of the eye has been excited. On the other hand we may discover or suspect, from the escape of aqueous or the depth the foreign body has penetrated, that the iris or lens has been wounded. If the iris has suffered, the case may be complicated by iritis ; and if the capsule of the lens has been injured, a traumatic cataract will add further to the difficulties we shall have to contend with. Supposing that both the iris and lens have escaped injury, we may generally lay hold of the foreign body with a pair of forceps, and remove it from the eye without difficulty.

If, from the patient's endeavours to rub the foreign body out of his eye, he has driven its outer extremity inwards, flush with the cornea, or it may be deeply into its laminated tissue, it is frequently impossible to seize hold of it with a pair of forceps ; any forcible attempts to do so would probably drive it completely into the anterior chamber. It is advisable, under these circumstances, to enlarge the wound in the cornea, and then seize hold of the foreign body and remove it. It has been recommended, in cases of this description, to pass a broad needle through the margin of the

cornea, the flat blade of the instrument being inserted beneath the inner extremity of the foreign body; the latter may thus be pushed outwards, and taken hold of with a pair of forceps.

Mr. S. Snell, in the *British Medical Journal* for 1881, 1883, and 1890, has described his instrument and published a series of cases in which he has employed the electro-magnet for the removal of chips of iron and steel from the eye. His increased experience has rendered him more positive in the opinion he formerly expressed—"that the electro-magnet is most useful in the extraction of metallic substances of this kind from the eye. No one who has read Mr. Snell's cases, can fail to be impressed with the truth of the conclusion he has arrived at on this subject, and that the electro-magnet greatly facilitates the removal of these foreign bodies from the eye without the risk of inflicting further injury to this delicate organ, a complication not unlikely to occur when cutting instruments are used for this purpose."

A solution of atropine should subsequently be dropped into the eye three or four times a day so as, if possible, to keep the iris away from the wound in the cornea, and a pad and bandage should be carefully applied. If the eye is much inflamed, cold compresses may with advantage be used, and opium must be administered internally, so as to allay the irritation in the part. Leeches will be necessary if the inflammation runs high.

If, on examining the eye, we find the foreign body has wounded the iris or lens, but can still be withdrawn from the cornea, we shall, of course, lose no time in removing it; but if it has fairly passed through the cornea, and fallen into the lower part of the anterior chamber, or is seen sticking in the iris, we can no longer hope to seize it with the forceps; having once passed through the cornea the elastic lamina closes over it, and defeats all our attempts to get at it in this way, and a different method must be employed. The management of these cases will be found described under the head of Wounds of the Iris, the corneal injury being a matter of secondary importance.

SENILE DEGENERATION OF THE CORNEA.—This condition of the cornea is characterized by the presence of the *arcus senilis* or white margin, which Mr. Canton describes as

follows:—"The arcus senilis, if closely examined, will be found to be composed of two parts, the outer having a greyish white or dusky tint, the inner one being milky in colour. These are separated from each other by a clear, unaffected line of cornea, and through this the iris can be distinctly seen."

This alteration in the margin of the cornea usually commences in its upper section, and in both eyes at the same time; subsequently the lower portion is similarly affected, so that the eye then presents two white crescents, an upper and a lower one; they gradually advance, and ultimately coalesce, and the cornea is then surrounded by a whitish band as above described. This band usually extends only a short distance from the margin of the cornea, but in some instances it encroaches on the more central parts, and may involve a considerable portion of the cornea, but such cases are rare.


This condition is not to be confounded with the grey line which corresponds to the border of the sclerotic, where it is bevelled off to overlap the cornea: the true arcus senilis depends upon fatty degeneration of the cornea, its transparent structure being converted into a semi-opaque band, of the extent and configuration depicted in Fig. 32.

As a general rule, the arcus does not appear before a man has reached the age of forty-five or fifty, but it may come on in younger people; when it does so, it may be taken as an indication of a constitutional tendency to fatty degeneration of the tissues. There can be no doubt

that the arcus senilis is hereditary; that is, the gouty or other diathesis upon which it depends, passes from parent to child, and with it the tendency to early fatty degeneration of the cornea, the muscular tissue of the heart, and other organs of the body.

We are not aware of a single instance in which this disease has advanced so far towards the centre of the cornea as to interfere with the perfection of vision. We cannot say that in operating for cataract, the presence of an arcus senilis influences us in the selection of one or other of the various modes of removing the lens; we have frequently performed

FIG. 32.



the flap extraction with the most favourable results, although an extensive arcus senilis has been present.

Instances have been recorded of an arcus senilis disappearing under a course of treatment calculated to increase the vigour of mind and body, among those whose constitutions have been impaired from overwork, ill-health, and other depressing influences.

LEPROUS AFFECTIONS OF THE CORNEA.—Among the natives of India, and in fact among all classes affected with leprosy, it often happens that both corneæ become nebulous, the opacity commencing at the extreme margin of the cornea, and extending year by year towards the axis of vision: vessels may from an early stage of the disease be seen protruding from the sub-conjunctival zone into the cornea, and from time to time these vessels become much congested, the hyperæmia lasts for a month or two and then subsides; but after each attack of this kind the opacity of the cornea increases both in extent and density, and so the patient's sight is slowly but surely lost for all practical purposes.* Changes in the transparency of the cornea such as we have above described, are due to the growth of leprous elements in the tissue of the cornea, and consequently we can only hope to influence the condition of the eye by acting on the primary cause of the disease. We have seen leprous patients improve under a long-continued course of tonics, combined with arsenic, change of climate, and a generous dietary, but never seen such a patient cured. We cannot cure the disease, but we may perhaps delay its progress for years.

Leprous Tubers of the Cornea commence as small pale elevations situated on the margin of the cornea; as the little tuber grows it becomes vascular, and gradually extends over the surface of the cornea. Both eyes are, as a rule, attacked, and the tubers are placed symmetrically on corresponding spots of the cornea, they take years to grow, but nevertheless surely and gradually increase in size until they entirely cover the cornea. As far as our experience goes, treatment is of little avail in this form of leprosy; an eye

* Some years since, I sent a patient suffering from leprous disease of the cornea to Mr. J. Hutchinson, and from this patient, Plate XXIX. was drawn the series of Chromolithographs of Diseases of the Skin, published by the New Sydenham Society.—N.C.M.

once affected by tuberos growths will, in spite of all we can do, gradually be destroyed.

GROWTHS OF THE CORNEA.—Dermoid cysts have occasionally been seen, they are congenital and do not usually interfere with vision; removal may be necessary.

EPITHELIOMA, FIBROMA, AND MALIGNANT TUMOURS are rare.

CHAPTER VI.

DISEASES OF THE SCLEROTIC.

Anatomy—Episcleritis—Anterior Staphyloma—Wounds of the Sclerotic—Contusions—Tumours.

SCLEROTIC.

THE sclerotic forms the external coat of the eyeball, and is especially tough and strong, so as to afford protection to the more delicate parts within; it is thickest at its posterior part, where the measurement amounts to 1 mm., and thinnest just behind the insertion of the recti muscles. In front it is covered by the conjunctiva. The sclerotic consists of closely interwoven connective tissue fibres intermixed with fine elastic tissue. The two sheaths of the optic nerves get rapidly thick as they approach the eyeball, at the point where they reach the choroid they bend round at right angles and unite, receiving the name of the sclerotic; this coat extends over five-sixths of the eyeball, joining in front with the cornea. The recti and obliqui tendons, spreading out at their insertion, also materially assist in strengthening the sclerotic, and contributing to its substance. Distributed among the fibres are numerous connective-tissue corpuscles lying in cell-spaces; they are identical with those of the cornea, but are less regularly arranged. A few blood vessels permeate the sclerotic, in the form of a network of capillaries with very wide meshes. In the neighbourhood of the cornea a zone of greater vascularity exists. It is invisible in health, but in inflammatory conditions of the ciliary body and iris, becomes very marked as a rosy zone of vessels encircling the cornea. The sclerotic continues to increase in size until

about the twentieth year, when it ceases to grow. During its development, it is evident that anything which tends to weaken or soften the tissue, or to cause an unnatural strain on any part of its surface, will result in a permanent alteration in the shape of the globe and tend to develop myopia or staphyloma.

EPISCLERITIS.—We occasionally meet with cases, especially among adult females, in which *parenchymatous formations* of a limited character take their rise in the sclerotic. A patient affected in this way presents himself to us with a dusky-red or dull purple bulging of the sclerotic, probably as large as a split pea or bean, usually situated on the inner or outer side of the globe, near the insertion of one of the recti muscles. There is generally some slight conjunctivitis over and around this little nodule in the sclerotic. The patient seldom complains of pain or inconvenience beyond a slight stiffness in the movements of the eyeball; but there is always tenderness on pressure, in some cases, especially those subject to rheumatism, the patient complains of intense neuralgic pains extending from the affected eye over the side of the temple, with considerable photophobia. The protuberance feels hard, precisely as if a small fibrous tumour were growing from the sclerotic; the part is vascular, but the rest of the eye may be perfectly healthy; the injected conjunctiva can be moved over the upraised sclerotic.

Some of these cases may be traced to a syphilitic taint, the hypergenetic process in the sclerotic resulting in the formation of a gummy tumour of small size, pursuing the same course as similar growths do in other parts of the body, and under these circumstances, the growth in the sclerotic is likely to recur after it has disappeared for a time. More frequently there is a rheumatic or gouty diathesis.

The progress of episcleritis is slow, often lasting for several months; but it has a natural tendency to recover, and will in time entirely disappear; but if of syphilitic origin it may degenerate into an ulcer, unless properly treated.

It sometimes happens that inflammation and infiltration of the sclerotic occurs near the margin of the cornea or in the ciliary zone. There is a slight bulging of the sclerotic, which is of a violet tinge, and having enlarged conjunctival vessels over it. Extending from the inflamed area cloudy opacity and often ulceration of the cornea occurs. The disease is very apt to recur, and with each fresh attack more of the

cornea becomes involved ; the iris also is implicated, and in cases the diseased sclerotic yields to the intra-ocular pressure, and a staphyloma is the result.

Treatment.—The eye should be kept at rest with a pad and bandage, and, as a rule, iodide and bromide of potassium combined with bichloride of mercury, will hasten the removal of these parenchymatous growths. When there is a rheumatic or gouty history, the remedies appropriate for these diseases must be employed. Sometimes massage over the closed lids will do good.

ULCERATION OF THE SCLEROTIC.—Sir W. Bowman has described a peculiar form of this affection as “small, intractable ulcers of the sclerotic,” and we have lately met with a case of this kind. The patient was in bad health, the ulcers occurred in succession in both eyes, and were situated near the cornea ; they looked as though a small piece of the sclerotic had been punched out ; and in the right eye they extended so deeply into the sclerotic, that ultimately it was perforated. The disease was of a most obstinate nature, and the patient suffered considerably from pain in the eyes, intolerance of light, and profuse lachrymation. In addition to these doubtful cases of syphilis, gummatous ulcerations of the sclerotic are occasionally met with.

ANTERIOR STAPHYLOMA OF THE SCLEROTIC, OR SCLEROCOROIDITIS ANTERIOR.—By this term is understood a bulging outwards of a limited portion of the sclerotic, either close to the junction of the cornea, over the ciliary region, or near the equator of the globe. A staphyloma is said to be “partial,” when only a portion of the sclerotic between the cornea and equator of the eye is involved ; it is “complete” when the whole circumference of the globe is involved, the diseased action being in the majority of cases confined to the region of the ciliary body. In the complete form of anterior staphyloma, the sclerotic is extensively degenerated, and yields before the intra-ocular tension.

Anterior staphyloma of the sclerotic may arise :—1st, From degenerative changes, the result of iritis involving the vessels and fibrous tissue of Fontana’s space. 2nd, From inflammation of the ciliary body and iris. In this case the sclerotic in the immediate vicinity not only suffers directly from the effects of inflammation, but also from faulty nutritive changes and secondary degeneration, in consequence of the disease of

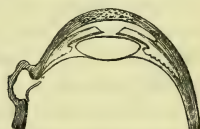the ciliary body. 3rd, A staphyloma may arise from the effects of an incised wound over the region of the ciliary body or choroid.

1. In the first class of cases the conditions leading to a staphyloma are gradually established, commencing with disease of the iris and fatty degeneration of the tissues at the line of junction of the cornea and sclerotic. The sclerotic is largely dependent upon the vessels of the choroid, ciliary body and iris for its nourishment; and so inflammatory changes lead not only to atrophy of the diseased tissues, but to secondary changes in the sclerotic, which is no longer able to resist the intra-ocular pressure, and bulging outwards, forms a staphyloma (Fig. 33). The size of the protuberance depends upon the extent of the degenerative changes that have taken place.

A staphyloma of the sclerotic thus formed is generally of a dark bluish colour, often almost black on account of the pigment cells of the ciliary body having become intimately attached to its inner surface, and their colour being seen through the attenuated sclerotic. This form of disease often makes but slow progress, and may become stationary; but if irritation and congestion are excited in the neighbouring structures, the parts already prone to disease undergo further changes, and a large staphyloma results. In this case the nutrition of the vitreous and lens is apt to suffer, the former becoming fluid and flocculent, the latter more or less opaque, so as greatly to interfere with the perfection of vision.

2. In instances of anterior staphyloma of the sclerotic originating in inflammation of the ciliary body, precisely the same pathological changes ensue as in the previous variety. The early symptoms, however, are those of irido-cyclitis; the congested sclerotic zone of vessels exists, indicating abnormalities in the intra-ocular circulation; there is pain in the eye, increased on pressure over the inflamed ciliary body, and intolerance of light; haziness of vision from opacity of the vitreous follows; and there is marked increase of tension of the eyeball. The symptoms often run a subacute course; but from effusion taking place into the part, the ciliary body is apt to be torn away from the sclerotic; or from damage done to its vessels during the inflammation,

FIG. 33.



degenerative changes progress rapidly in the latter structure, and, as we have above described, it yields to the intra-ocular pressure, and a staphyloma occurs. This bulging of the sclerotic may be of very considerable size, so much so as ultimately to project forwards between the eyelids and impede their movements, or even prevent their closing. In instances of this kind the retina becomes detached, and the eye totally destroyed. On the other hand, if the staphyloma does not reach any very considerable size, and a sufficient quantity of healthy choroid is left to supply nourishment to the vitreous and lens, the patient may retain a fair amount of vision for a time; but in too many cases of this description exacerbations of the disease occur, ending in destruction of the eye.

3. In instances of wounds of the sclerotic over the ciliary region a hernia of a portion of the ciliary body may take place through the incision, and unless the case is speedily brought under treatment, the intra-ocular pressure not only forces the edges of the wound apart, but protrudes more of the ciliary body through it. This extruded portion becomes in the course of time covered by fibrous tissue, so that a staphyloma is formed, the inner surface of which is lined by the remains of the ciliary body or choroid, according to the position of the original wound. In consequence of the irritation and stretching to which the parts are exposed, subacute inflammation is established, and progressive degenerative changes set in; more of the sclerotic may, in this way, be involved, until at last a large staphyloma is formed.

In instances of this description, unfortunately, the damage is not confined to one eye—the irritation is too frequently propagated from the injured eye to the sound one, and unless the source of irritation is speedily removed, the patient will lose his sight altogether.

From whatever cause a staphyloma of the sclerotic may arise, it follows, if the protrusion be a large one, surrounding perhaps, the whole or a greater part of the circumference of the eye, that extensive changes occur within the globe. We must bear in mind the fact that staphylomata involving the sclerotic round the margin of the cornea implicate the spaces of Fontana, which is the chief region of filtration of the intra-ocular fluids; hence, we notice in cases of this kind that the iris becomes altered in colour, the lens often opaque, the vitreous degenerated. In fact, glaucomatous changes occur, and in many cases the eye thus affected becomes completely

disorganized; on the other hand, staphylomata posterior to the ciliary region (if the consequence of a limited choroiditis) are less likely to lead to destructive changes in the eye than those which implicate the spaces of Fontana.

Treatment.—In the degenerative form of anterior staphyloma of the sclerotic, but little can be done to cure the disease. Much may be effected, however, in the way of preserving the eye from further damage, by warning the patient of the danger he runs from over-exerting it, and of the necessity there is for protecting it from external injury and from the glare of the sun, and, in fact, of taking all possible care of the diseased organ. If the affection depends upon inflammatory changes, our treatment must be mainly directed towards the mitigation of the primary cause of the disease; and as a means to this end we shall probably resort, among other measures, to paracentesis or iridectomy; but for further details on this subject we would refer to the chapter on iridocyclitis. If, in instances of this description, the staphyloma is of considerable size, and the sight of the eye destroyed, there can be no two opinions as to the propriety of excising the diseased globe.

In the third class of cases, of staphyloma of the sclerotic resulting from an incised wound, whether of recent origin or otherwise, if the patient's sight is much impaired, the sooner excision of the eyeball is performed the better. Sympathetic irido-choroiditis, as we have elsewhere explained, is a most insidious and dangerous form of disease, and is what we have most reason to fear in cases of sclero-choroiditis arising from wounds of the sclerotic. We have no hesitation, therefore, in saying that, even supposing the sight of the injured eye is partially retained, but the vision of the sound eye gradually becomes impaired, or symptoms of irritation in the iris or deeper structures make their appearance, extirpation of the injured organ must be insisted on at once; any delay, under these circumstances may end in total loss of sight in both eyes. On the other hand, by removing the diseased eye before sympathetic irritation has been excited, we may reasonably hope to prevent the sound eye becoming blind.

WOUNDS OF THE SCLEROTIC.—Incised wounds of the sclerotic are not uncommon. An injury of the kind is apt to be complicated with prolapse of the choroid or ciliary body into the wound, and a portion of the vitreous may escape. The pro-

lapsed structures are liable to get entangled in the wound, and as the latter cicatrizes and contracts, sympathetic iridochoroiditis may be set up in the other eye, necessitating the removal of the wounded eyeball.

RUPTURE OF THE SCLEROTIC may occur from a direct blow on the eye, inflicted with a blunt instrument, the closed fist, or from a fall. In cases of this description, the sclerotic is most commonly burst open at its upper or inner part, near the margin of the cornea, or between the cornea and the insertion of the recti muscles. A blow on the eye sufficiently severe to rupture the sclerotic, necessarily affects the other structures contained in the eyeball, and at the instant when the sclerotic is ruptured, the lens is usually forced out through the wound, dragging the iris, and often a portion of the choroid, away with it. The vitreous may also escape, and, in fact, the eye too often collapses, and is totally lost. In less severe cases the retina may be detached from the effects of the concussion, or from the bursting of some of the choroidal vessels, and the hæmorrhage which then takes place behind it. Under these circumstances, the anterior and vitreous chambers become filled with blood, and it will be impossible to ascertain exactly the lesions that have taken place in the fundus of the eye until the blood has become absorbed. Lastly, during and after the healing process, there is always great danger of sympathetic irritation being excited in the sound eye, in consequence of the prolapsed tissues becoming adherent to the cicatrix of the wound in the sclerotic.

CONTUSIONS OF THE SCLEROTIC, apparently of a trivial nature, are at times followed by degenerative changes in the vitreous. Probably, the circumstance of the injury is forgotten, and the patient consults the practitioner for gradual loss of sight, usually complaining also of dark objects waving about before the field of vision. On examining the eye with the ophthalmoscope, we not unfrequently find partial detachments of the retina, and that the vitreous is fluid; small brown or black specks may be seen floating about in it whenever the patient moves his eye.

Prognosis.—The prognosis to be formed in instances of severe wounds or injuries of the sclerotic, is, as a rule, unsatisfactory. Even in slight cases, complications such as above indicated, consisting of detachment of the retina and degeneration of the vitreous may occur. Lastly, injuries of this description are likely to involve the choroid, entailing remote

ill-consequences, and we shall subsequently explain when speaking of diseases of that structure.

Treatment.—In a case of rupture or wound of the sclerotic, if no great amount of the vitreous has escaped, its edges, under some exceptional circumstances, may be brought together by means of fine sutures, and the eye kept at rest till the wound has healed. But if the lens and a considerable portion of the choroid or ciliary body protrudes into the wound, the mischief does not stop here, for sympathetic irritation is so frequently set up in the other eye, that it is better to remove the injured globe at once, especially if the sight of the eye is destroyed.

TUMOURS OF THE SCLEROTIC.—Cases of fibroma, and sarcoma growing from the sclerotic have been described; but such tumours invariably commence in the episcleral tissue, at the corneo-scleral margin.

CHAPTER VII.

DISEASES OF THE IRIS AND CILIARY BODY.

Anatomy—Hypercæmia of the Iris—Iritis—Varieties—Detachment—Coloboma—Tumours—Mydriasis—Myosis—Iridec-tomy—Cyclitis—Sympathetic Ophthalmitis.

THE IRIS is a thin circular diaphragm which regulates the amount of light entering the eye; it is suspended in the aqueous humour and separates the anterior from the posterior chambers. By its outer margin it is attached to the ciliary ligament and the posterior elastic layer of the cornea, its inner margin forms the pupil, which can contract or enlarge as occasion requires; the pupil is usually circular in form and is a little to the nasal side of the centre. The anterior surface of the iris is directed towards the cornea, and is variously coloured in different persons; the posterior surface is covered with pigment and is in contact, near the pupil, with the anterior surface of the lens.

The Iris is composed of muscular and connective tissues, containing a rich network of pigment-cells, vessels and nerves. From before backwards we find the following layers: (1) the endothelial layer, with (2) its delicate hyaline membrane, the continuation of the remnant of Descemet's membrane; (3) the substantia propria, which consists of bundles of connective tissue, holding in its meshes the vessels and nerves and numerous branched pigment-cells; (4) a hyaline layer continuous with the lamina vitrea of the ciliary processes and choroid; (5) the "uvea," a prolongation of the pigmentary layer of the retina and ciliary processes and similar to it in structure. In blue irides this is the only layer that contains pigment granules.

The iris, ciliary processes and choroid, not only closely re-

semble one another in structure, but their inner layers (viz., the substantia propria, hyaloid, and pigmentary membranes) may be traced without solution of continuity from the optic nerve to the margin of the pupil.

The arteries of the iris are remarkable for the thickness of their walls, especially their outer and middle coats. They spring from a vascular ring formed by the anastomoses of the long and anterior ciliary arteries round the base of the iris (circulus major), and pass forwards in a tortuous manner in the middle of the stroma to form a second circle of anastomoses at the pupillary margin. Here they communicate with the veins by means of a very fine capillary plexus. The veins follow the arterial branches. Lymphatic sinuses exist in the sheaths of the bloodvessels and between the trabeculæ of the connective-tissue bundles. They open into the spaces of Fontana.

The muscular fibres of the iris are situated in the stroma. The sphincter consists, like the dilator, of unstriped fibres. The dilator is developed from the fasciculi of the sphincter by a series of overlapping arched fibres. As the fibres pass to the circumference they divide, to form two layers, a superficial coarse layer and a deeper fine layer. At the ciliary border they form by their interlacement a narrow circular plexus of fibres.

If a living healthy eye be examined with a magnifying glass, the deep layer of fibres will all be seen to have a wavy outline~~~~~, while the thicker superficial ones will be seen to divide dichotomously, the two branches uniting in a similar way to form a fibre like the original one, thus resembling two Y's joined end to end (Y). There are endless modifications of this shape; but whatever their shape, wavy, curved, or branched, they all appear to serve one purpose—viz., to allow of the pupil becoming contracted without the least stretching of the delicate tissues of which the iris is composed.

Hyperæmia of the Iris is a condition met with in conjunction with a contracted state of the pupil (myosis), a result of irritation of the cornea, or it may be of some of the deeper structures of the eye. It may also occur from a rheumatic or gouty state of the system. The iris in cases of this kind, loses its natural colour, its fibrous striæ become blurred, and its natural brilliancy disappears. The pupil may respond to light but as a rule fails to dilate freely when light is excluded

from the eye. There is generally some slight pericorneal congestion, and the patient complains of dimness of vision and a certain amount of aching pain in the eye, or rather on the eyebrow. The treatment of cases of this description must be carried out upon the principles subsequently described for iritis; one of the most important points being to keep the pupil fully dilated with atropine, and the eyes shaded from the light by coloured glasses.

Iritis, or Inflammation of the Iris, is characterized by certain symptoms common to all forms of the disease, and which it will be convenient to describe under distinct headings, so as to save unnecessary repetition when giving the features of each variety of iritis.

Pain in the affected eye is a constant symptom of iritis; in some subacute cases it is only slight, but in more acute cases the pain is severe and extends to the temple, and often to the cheek and side of the nose. The pain is increased by exposure to light or by any effort made to use the affected eye; it is always worse at bedtime, and usually lasts until the early morning; it is often relieved by warm fomentations and increased by cold. The eye is tender on pressure, but this symptom is not so pronounced or marked in cases of iritis as it is in cyclitis.

Pericorneal Zone.—This consists of a pinkish rim of injected vessels surrounding the cornea, the vessels do not extend into the cornea as in keratitis, but this zone is formed by the branches of the anterior ciliary arteries and veins which supply the iris and form a network of vessels about a quarter of an inch wide, round the cornea. The intensity of the injection of the vessels of the iris is therefore indicated by the extent of this pericorneal zone, in acute cases the zone is well marked and broad, but is often covered in and obscured by hyperæmia of the vessels and effusion into the conjunctiva. In fact, there are few cases of severe iritis in which there is not a considerable amount of conjunctival congestion, and thus, unless to the practised eye, it is not easy to make out the pinkish zone of pericorneal vessels which are covered in by the injected conjunctival tissues. As the inflammation of the iris subsides the pericorneal zone disappears, unless adhesions have formed between the iris and lens, in which case these deep vessels surrounding the cornea are often persistently congested in consequence of chronic inflammation of the iris.

Changes in the Colour and Texture of the Iris are noticeable in all cases of iritis; a blue or grey iris becomes more or less green; a green iris has a yellow tint and a dark brown iris a red hue. These alterations in the colour of the iris are obvious if only one iris is inflamed, by comparing the diseased with the healthy eye. Even in those rare cases in which the colour of the healthy irides differ, when inflamed the contrast between the appearance of the eyes is marked, in that the fibrous structure of the inflamed iris is blurred or muddy. This muddiness of the iris is caused by exudation from the congested vessels into the tissues constituting the iris, and also into the aqueous humour; the former blurs the natural texture of the iris, and the latter alters the transparent nature of the aqueous, so that the iris is seen through a hazy medium. It is largely in consequence of this turbid condition of the aqueous that the patient's sight becomes dim in the early stages of iritis.

Alteration in the Mobility and Form of the Pupil.—The congested state of the vessels, together with the serous effusion that occurs in the early stages of inflammation of the iris, necessarily impair the functions of the contractile elements of the iris, and consequently its mobility; hence a defective response of the iris to the stimulus of light is an early symptom of iritis. Subsequently the effusion from the congested vessels of the iris becomes organized, forming adhesions (posterior synechiæ) between the iris and the capsule of the lens. As these adhesions form, they not only impede the action of the iris, but when under the influence of atropine the pupil assumes an irregular shape, or the iris being fixed to the capsule of the lens by connective tissue is unable to dilate. From the commencement, therefore, and throughout the course of an attack of inflammation, the iris responds imperfectly, and it may be is altogether insensible to the stimulus of light or to mydriatics.

Intolerance of Light and Lachrymation are symptoms so frequently met with in iritis, that they may be considered as common to all its forms. In chronic or subacute cases they may be hardly noticeable, whereas in the active stages of the more acute forms of the disease, the patient complains of the exacerbation of pain which he experiences the instant he approaches the light, and he is perpetually wiping away the tears that flow over his cheek.

Congestion of the Conjunctiva is always present to some

extent in iritis, and in many instances its vessels are so deeply injected, that it is well nigh impossible to distinguish the pericorneal zone of vessels. In these cases, if the posterior layers of the cornea are also affected, the condition of the iris, which is the real centre of disease, is apt to be overlooked. Any doubts that may exist as to the nature of the affection can be cleared up by employing the focal method of examination, or by applying a solution of atropine to the eye; the irregularities of the pupil will then become apparent.

Causes of Iritis.—We may classify cases of iritis clinically under two heads: the plastic and suppurative or parenchymatous. Plastic iritis forms probably not less than 85 per cent. of the cases of iritis which we meet with in practice, the greater number being connected with exposure to sudden changes of temperature, or to damp and cold; rheumatic iritis, as it is commonly called. Gonorrhœa is another, though uncommon cause of this form of iritis, for it sometimes occurs in persons suffering from gonorrhœal rheumatism (synovitis), probably resulting from ptomines circulating in the blood, produced by the gonococcus, rather than directly to micro-organisms in the tissues of the iris. Patients affected with syphilis in its less advanced stages not unfrequently suffer from plastic iritis, and we see this form of inflammation following blows or injuries of the eye. Suppurative or parenchymatous iritis may result from incised wounds of the cornea and iris, through which septic micro-organisms have gained access to the injured tissues and given rise to purulent inflammation, which is apt to extend to the ciliary body and choroid. In long-standing cases of syphilis, rarely in its earlier stages, gummata form on the iris and may degenerate into pus. Cases of inherited syphilitic iritis are met with from time to time among young infants, but iritis is one of the most uncommon forms of disease of the eye arising from inherited syphilis. The nodules of tubercular iritis, and of leprosy, may both degenerate into pus and produce hypopyon. Serous iritis is described under the heading of cyclitis; it occurs most frequently in women in a debilitated state of health, suffering from some uterine affection.

PLASTIC (OR RHEUMATIC) IRITIS forms by far the most numerous class of cases of inflammation of the iris which we meet with in practice; its characteristic feature is, that the

exudation, both on the surface and in the substance of the iris, tends to become developed into connective tissue; bands of adhesion are thus formed in the early stages of the disease between the iris and capsule of the lens (*synechiæ*), and in the contractile tissue of the iris itself. The products of inflammation in plastic iritis, as a rule, do not degenerate into pus, and appears to have little or no tendency to spread by infiltrating or by infecting neighbouring structures. In favourable circumstances this form of disease may run its course in from ten to fifteen days, and then gradually disappear. Instances of this kind are, however, exceptional, unless the patient has been brought under treatment at an early stage of the affection. The majority of cases of plastic iritis, if left to themselves, terminate in *synechiæ*; slight adhesions form in the first instance between the pupillary margin of the iris and the lens, which fix the iris to the capsule at one or more points. Every time the pupil dilates, these tags of adhesion pull on the iris, keeping up a state of irritation in the part, which, in conjunction with the primary constitutional cause of the affection, induces further inflammatory growths; more extensive adhesions form, until, after repeated attacks of this kind, the iris becomes firmly bound down to the lens. Degenerative changes then take place in the fibrous structure of the iris, which ultimately becomes atrophied. Unfortunately, the mischief that occurs in these circumstances does not stop here; the communication between the anterior and posterior chambers of the eye becomes closed, an abnormal collection of fluid takes place behind the iris, the lymph channels which pass out at the iritic angle are obstructed, and so increase of tension of the globe of the eye, with the train of evils which follow in its wake, is apt to take place.

Symptoms.—As a rule, the zone of pericorneal vessels is well marked in the early stages of plastic iritis. The mobility of the iris is affected, its free margin appears to be swollen and thickened, its fibrous structure loses its distinctness, and its colour is likewise altered. The amount of exudation varies in quantity in different cases; it is first deposited on the posterior surface of the iris, and may add to the uniformly hazy, swollen condition of that structure, but is otherwise not distinguishable. In other instances, the exudation forms small papillary excrescences on the surface of the iris, particularly at its pupillary margin; if numerous, these run into one another, and reaching over the pupil cover the centre of

the capsule of the lens; in any circumstances the exudation is apt to form adhesions between the margin of the pupil and the capsule of the lens. These papillary excrescences are often mere specks, so that we may not be able to detect their presence by simple inspection, and in this respect plastic differs from the parenchymatous iritis. The amount of pain from which a patient affected with this form of iritis suffers, varies with the intensity of the disease; in subacute cases it is not severe, but in all acute cases the pain is excruciating, extending from the affected eye over the temple and side of the face; it almost always increases in intensity towards evening, continuing until the early hours of morning.

Gonorrhœal Iritis is a form of plastic inflammation which runs a course similar to that of acute rheumatic iritis. It is well known that some persons when suffering from gonorrhœa are attacked with symptoms of synovitis, and among such individuals iritis not unfrequently occurs. The affection of the eye in these cases comes on usually a short time after the commencement of the urethritis, and continues so long as there is any discharge from the urethra. Attacks of iritis in one or both eyes occur during each successive gonorrhœa, and the affection of the eye not unfrequently precedes that of the joints; it is further remarkable that if iritis exists before the synovitis, the former diminishes in severity as soon as the joints become painful and swollen. Gonorrhœal iritis is generally attended with intense pain, great mental depression, and sleeplessness; it too often leads to extensive synechia, for the disease is intractable; in fact it will seldom yield to treatment so long as the gono-coccus retains its hold on the mucous membrane of the urethra. Leeches, atropine, and constant fomentation are almost always necessary, and full doses of the iodide of potassium should be administered, but it is to the complete cure of the urethritis we must direct our attention, otherwise our efforts to relieve the iritis will fall short of the mark and irreparable damage be done to the eyes. In these cases the conjunctiva is always more or less affected, but there is none of the purulent discharge or ulceration of the cornea which characterises instances of gonorrhœal conjunctivitis.

Suppurative or Parenchymatous Iritis, the most obvious feature of this form of iritis, as contrasted with plastic inflammation of the iris is, that some of the inflammatory exudation has a tendency to degenerate into pus, and these

cells appear to be capable of infiltrating surrounding structures, and thus of conveying living micro-organisms into neighbouring tissues; the diseased action is consequently apt to spread to the ciliary body and other parts of the eye. A portion of the inflammatory exudation, however, becomes organised, and synechiæ are thus produced; so that in addition to the pathological changes in the iris met with in plastic iritis, we find inflammatory materials in various stages of degeneration, and the tissues in which these changes have occurred have passed, more or less, into a state of necrosis. This process may be an acute one, as in most instances of suppurative traumatic iritis, or it may be a chronic disease, as in some cases of tubercular leprosy, or of old-standing syphilis, in which gummata have formed on the iris. Gummata growing in this situation vary much in size, some not being larger than a pin's head, whereas others cover a large part of the iris and may project so far forward as to reach the cornea. We have seen growths of this kind mistaken for tumours of the iris; at first they are of a reddish-brown colour; subsequently, they assume a more distinctly yellow tint. A gumma of this kind may become absorbed under proper treatment, but as a rule, if left to run its course it degenerates into a pus-like fluid, which sinks into the lower part of the anterior chamber, forming a hypopyon. Gummata of this description commence in the parenchymatous tissues of the iris, and in their growth they completely destroy those structures, and by disturbing the nutrition of the surrounding tissues lead to inflammatory exudation and the formation of synechiæ. Almost precisely similar changes are frequently seen in cases of tubercular leprosy; and in that uncommon form of disease, in which the *Bacillus tuberculosis* finds a congenial soil in the iris wherein it can grow, and produce tubercles.

In perforating wounds of the cornea, whether incised or lacerated, if the iris has also been injured, septic matter is apt to pass into the eye. In the same way particles of steel or other foreign bodies may lodge in the iris, conveying with them septic matter. In these circumstances, in place of healthy reparative action taking place in the wounded iris, suppurative inflammation occurs, generally of an acute character, pus forms in the iris, hypopyon follows, and the ciliary body and choroid are likely to be affected, either by

septic emboli passing to them along the veins, or by direct infection along the suppurating tissues.

Symptoms.—These vary with the nature of the disease, but in all instances of parenchymatous iritis the symptoms characteristic of inflammation of the iris are well marked. The pericorneal zone of vessels, alteration in the colour of the iris, impaired action of the iris, irregular pupil, and pain in the eyes and temple being present. In addition to these symptoms we have in the majority of instances of this form of iritis, a well marked history of syphilis with a gumma, such as we have described, growing from the iris. But these gummata are not characteristic of syphilitic iritis, for in no inconsiderable number of cases of syphilitic iritis gummata do not form, the inflammatory action is of the plastic variety; on the other hand, although in this country gummata of the iris are characteristic of syphilis, in other parts of the world precisely similar formations occur among patients suffering from leprosy. Whether the gummata are of syphilitic or of leprosy origin, they are apt to degenerate and give rise to a sanguineous purulent fluid which sinks into the lower part of the anterior chamber, forming an hypopyon. The turbid aqueous contains also floating particles of the gumma and inflammatory materials. In many cases the posterior elastic lamina of the cornea becomes hazy. Extensive synechiæ form, and the whole of the iris in neglected cases of syphilis undergoes disintegration, and in cases of leprosy invariably does so in spite of any treatment as yet recommended for its relief.

Tubercular Iritis.—There is no longer any question as to the fact that Jacobs, of Dublin, was correct in describing the so-called granuloma of the iris as tuberculosis, for these granules have been proved by inoculation and by culture to contain the tubercle bacillus. A patient affected with this form of disease in the first instance, suffers from the ordinary symptoms of serous or of plastic iritis; but small nodules soon make their appearance on the iris and may become confluent; or they may disappear for a time, to be followed by a fresh crop of tubercles. This affection of the iris, as a rule, manifests itself between the ages of five years and eighteen; it is seldom met with after the adult period of life. The tubercles commence as small yellow nodules in a case presenting the other symptoms of iritis; and the patient almost always manifests clearly marked signs of tuberculosis, such as enlarged cervical glands, loss of flesh and other constitutional weakness, with,

it may be, obvious indications of tubercles in other structures of the body.

Treatment of Iritis.—After what has been said as to the various conditions which may give rise to iritis, we need hardly observe that, before commencing the treatment of any particular case, we should endeavour to arrive at a definite conclusion as to its origin. There is usually no difficulty in recognising the presence of a well-marked rheumatic, gouty, or syphilitic taint; but it is far more troublesome to ascertain the nature of the case if a patient is suffering from any of those less definite ailments, induced by functional derangement of the secreting organs, which, by altering the character of the blood, interfere with the nutrition of the various tissues of the body. We must, nevertheless, attempt to master the subject, and also to right matters by the use of such remedial agents as we have at our command.

Atropine is invaluable in the treatment of all cases of iritis, for if we can keep the pupil dilated, it is difficult for synechiæ to form; besides which, when the iris is well contracted on itself, forming a narrow rim round the anterior chamber, it follows that its bloodvessels can hardly remain in a state of congestion; they must, in fact, be pretty well emptied of their contents under these circumstances. The inflamed tissue is also kept at rest when under the influence of mydriatics—a most important point in the treatment of all kinds of inflammation.

If a case of iritis is brought under our notice before adhesions have formed, or the structure of the iris has become atrophied, we may with safety rely upon atropine as being the most efficient curative means at our disposal; a few drops of a solution of atropine, of the strength of one grain to two drachms of water, should be allowed to run into the eye every second hour, until the pupil is fully dilated. The addition of an equal quantity of cocaine to the atropine solution often adds to its mydriatic effect. If the pupil dilates under this treatment, we may confidently hope to cure our patient in the course of a short time. In the more acute forms of the disease it is often a difficult matter to bring the pupil under the influence of atropine, and it may be necessary to continue its instillation every six hours, for some time. In some instances the atropine is unable to act, on account of the swollen and congested state of the iris; in these cases we should endeavour to reduce the inflammatory action by

mercury or iodide of potassium, and above all by the application of leeches to the temple, the atropine drops being continued at the same time. It is advisable not only to dilate the pupil, but to keep it dilated for some time after all acute symptoms have passed away; in fact, till the pericorneal zone of vessels has disappeared, and the balance of the circulation in the iris has been restored.

In many cases of iritis, bands of adhesion exist between the iris and the capsule at certain spots, only the remainder of the iris being sufficiently healthy to respond to the action of atropine. Under these circumstances, the pupil, in dilating, assumes all manner of shapes, expanding in one direction, and being prevented doing so in another by the adhesions. Atropine should be steadily and freely employed in these cases, it may be for several weeks; the connecting bands are sometimes broken through under its influence, and the existing iritis subsides; moreover, the synechiæ being destroyed, subsequent attacks of iritis will probably be prevented. While, therefore, employing the various means at our command for improving our patient's health, and, if possible, acting on the cause which has induced the iritis, we should endeavour to dilate the pupil to its full extent with atropine and cocaine, without any consideration as to the form of the disease or the progress it may have made. The prolonged use of atropine may, however, excite an attack of acute granular conjunctivitis in persons affected with the trachoma coccus; if we observe any symptoms indicating the commencement of an attack of this kind, the instillation of atropine must be at once stopped, but we may apply the extract of belladonna mixed with atropine over the patient's eyelids and temple. Extract of belladonna, however, is a less potent remedy than atropine, and is not to be relied on for dilating the pupil in iritis. Equal parts of extract of belladonna, Indian hemp, and glycerine, to which atropine has been added, form a useful mixture, which may be smeared over the affected eye to relieve pain.

Mercury.—It is unnecessary to resort to the use of mercury unless in cases of syphilitic iritis, but in such case it is the only means as yet discovered by which the disease can be cured. Mercury may be administered in the form of blue pill, or calomel combined with opium, or by inunction; for an adult half a drachm, or a drachm of the strong mercurial ointment being rubbed into the inside of the arms and thighs twice

daily, until the gums are slightly affected. The latter, in the majority of instances, is the best plan of administering mercury in the class of cases under consideration. If it appears advisable to affect the system rapidly, on account of the severity of the case, two grains of calomel with the eighth of a grain of opium may be given by the mouth every three hours, for two days. It will be necessary, although lessening the quantity of mercury employed after the iritis has begun to subside, to continue its use for some five or six months in small doses; probably one and a half grains of hydrarg. c. creta, as a pill at bedtime, is as good a form as we can prescribe for such patients; our object being to destroy the cause of the disease, and thus prevent a return of the iritis. Subsequently the patient may with advantage be put on a course of iodide of potassium.

Iodide of Potassium has for many years been employed with such marked success in certain cases of syphilitic affections of the iris, that it deservedly holds a high position among the remedial agents at our command; it may be administered in ten-grain doses three times a day, gradually increasing the quantity to twenty or thirty grains.

Salicylate of Soda (natural).—In cases of iritis occurring in rheumatic patients, salicylate of soda, administered in ten-grains every second hour, for forty-eight hours, and then in less frequent doses, often exercises a marked influence on the disease.

Opium.—In acute inflammation of the iris with great pain, opium should be administered; probably, for an adult, one grain twice a day, would be about the dose required. Among younger patients, and in less urgent cases it will be unnecessary and hardly advisable to order opium.

Leeches applied to the temple of a patient affected with iritis, will often exercise a marked beneficial influence on the progress of the disease. If the patient is suffering from much pain, two leeches may be applied near the affected eye, and the part should subsequently be fomented with hot water, so as to encourage the flow of blood from the leech-bites. If this treatment appears to exercise a favourable action on the disease, we may repeat it on the following day, often to the great relief of the symptoms. Cases of this description are likely to be much benefited by a dose or two of blue pill and colocynth, followed by a saline purgative in the morning, low diet at the same time being enjoined; in

fact, the leeches will form a part of an antiphlogistic plan of treatment.

Fomentations, Shades, &c.—Poppy-head fomentations are often soothing to the patient, and whenever this is the case, they may be used with advantage five or six times a day; if they do not relieve the pain it is advisable to discontinue them. Hot water compresses of as high a temperature as the patient can bear, to be changed every ten minutes, are useful in many cases of acute iritis.

Dry heat is often most comforting to the patient and can best be applied by holding a large piece of cotton wool to the fire, and then applying it directly over the affected eye; a second piece of wool may be heated to take the place of the first pad, as the heat goes off.

In all instances of iritis the affected eye should be shaded from the light, and the patient made to rest.

With regard to stimulants and food; in a case of iritis occurring in a plethoric individual, purgatives, and low diet are called for; but in many cases of iritis the patient requires a moderate amount of stimulants, good wholesome food, and fresh air; to some we shall have to administer bark and ammonia, together with wine and beef-tea. It is impossible to lay down rules on these matters applicable to all cases; nothing but the exercise of common sense and experience can guide us to a right conclusion.

In addition to local treatment such as that described in other forms of iritis, in tubercular iritis, strict attention must be paid to the patient's general health, in the hopes of overcoming the tendency which the bacillus has to grow, and to extend from the iris to other organs of the body. It has been proposed to excise that portion of the iris affected with tubercles, a rather hopeless proceeding; it would seem better in a case of this kind to open the anterior chamber and wash it out thoroughly with a very weak solution of corrosive sublimate; other authorities recommend enucleation for fear of the infected iris acting as a breeding ground, from which the tubercle bacillus may spread to the brain, lungs, or other organs. This may seem an extreme measure to take, but in cases of advancing tubercle of the iris the prognosis as regards the eye is bad, and what is still more important patients affected in this way too frequently succumb to general tuberculosis, which there is reason to believe may have started in the iris; in fact the prognosis in cases

of tubercle of the iris and choroid is serious not only with regard to the eye, but in too many instances of this kind the patient has been killed by the tuberculosis of other organs of the body; we have had no experience as yet of the treatment of tuberculos iritis by means of Koch's lymph.

Treatment of Synechiæ.—This subject will be more fully considered under subsequent headings describing the operations of corelysis, artificial pupil and iridectomy, but we may here remark that supposing a patient's sight to be impaired by synechiæ, which have occluded the pupil to some extent, and united the iris more or less completely to the lens, our first effort must be directed towards dilating the pupil by the persevering use of atropine; but in case the adhesions cannot thus be broken down, and provided the acute inflammatory symptoms have passed away, it will be necessary to resort to an iridectomy. In instances where the pupil is only partially closed, or when the synechia binds the iris down to the lens at one or more points, a portion of its margin remaining free, if atropine, after a persistent trial fails to dilate the pupil, and break down the bands of adhesion, it may seem advisable to perform the operation of corelysis. For adhesions involving more than the margin of the pupil, and when the iris is completely tied down to the lens, we must resort to iridectomy.

Prognosis in various Forms of Iritis.—In the first place the type of the disease and the progress it has made must be considered; for iritis presents not only different stages, but the disease is met with of very different degrees of severity. In slight and recent cases of iritis complete restoration may be predicted; in more serious cases the improvement can only be partial; in severe and neglected cases, it is but too often evident that we can hold out but slender hopes of recovery. It is, however, to the presence and extent of the synechiæ that we should principally direct our attention, in endeavouring to form a prognosis in cases of iritis. If bands of adhesion exist between the iris and lens, they too often lead to repeated attacks of inflammation, terminating in occlusion of the pupil and atrophy of the iris. In plastic iritis, if the adhesions are slight, or have only been recently formed, so that they can be broken through by dilating the pupil with atropine, we form a favourable prognosis, although the patient's sight for a time may be impaired by patches of uvea which remain

adherent to the capsule of the lens. If the synechiæ cannot be torn through by the action of mydriatics, much may still be done to improve the condition of the patient by an iridectomy, but our prognosis under these circumstances should be guarded: the patient's sight is never likely to be perfectly restored. In parenchymatous iritis, our prognosis, as a general rule will be unfavourable, unless the disease has been brought under treatment before it has made any great progress. It is true, some cases run a subacute course, but this is unusual; unless judiciously treated, the disease more commonly leads to multiple synechia, closed pupil and more or less disintegration of the iris. If, however, at any stage of the affection, we can dilate the pupil with atropine, we may expect a favourable issue, as we can then prevent the formation of synechiæ, and in all probability the further progress of the disease. In forming our prognosis, we should never lose sight of the fact that in all cases of iritis there is a tendency for the disease to recur, and that each successive attack leaves increased synechia, and the inflammation is liable to spread to the choroid.

There is a deceptive condition of the eye, the result of iritis, in which the patient's sight remains good, although the iris is closely bound down to the lens by synechiæ. This arises from the fact, that a small but clear opening remains through the pupil, and the rays of light reach the retina without hindrance; nevertheless, the sight is endangered from the closure of the communication between the chambers of the eye. Cases of this kind are but rarely met with in practice; we far more frequently see instances of closed pupil and extensive synechiæ, where the patient may have sufficient sight left to find his way about, but is unable to read or write with the diseased eye. If, under these circumstances, we fail to dilate the pupil with atropine, and if the tension of the eyeball is either increased or diminished, the prognosis cannot but be unfavourable; the deeper structures of the eye will probably have become implicated in the disease.

WOUNDS AND INJURIES OF THE IRIS.

INCISED WOUNDS.—We have described the symptoms and treatment of prolapse of the iris following perforation of the cornea; it is consequently unnecessary to return to the sub-

ject. As the result of an accident, incised wounds of the iris can seldom occur, without injury also to the lens and the formation of a traumatic cataract. But wounds inflicted by the surgeon on the iris with a clean instrument, heal without inflammation. In fact it appears for so delicate a structure as the iris, that it may be subjected to considerable contusion, as, for instance, in extracting an opaque lens without iridectomy, and yet remain free of any signs of inflammation.

In accidents involving the iris the eye should be kept at rest with an antiseptic pad and bandage; if the lens has been injured the consideration of the subject may be referred to the section on traumatic cataract, and if prolapse of the iris has occurred, to wounds and injuries of the cornea.

A Foreign Body sometimes penetrates the cornea and becomes fixed in the iris, the cornea closing over it; an accident of this kind, however, is of rare occurrence unless complicated with a wound of the lens, because, as a rule, if a particle of steel, or any other such hard material has penetrated the cornea, and not fixed itself in the lens, it falls to the bottom of the anterior chamber; and should it pass into, and remain in the iris, the chances are much in favour of its having penetrated the lens. It is often most difficult to see a minute foreign body either in the anterior chamber or in the iris. A patient comes to us complaining that while at work a particle of steel had struck his eye, we find him suffering from great pain in the eye, which is inflamed, extremely intolerant of light, and streaming with tears. A five per cent solution of cocaine should at once be dropped into the eye and repeated in three or four minutes, and again if the irritation in the eye has not much subsided. We then carefully examine the cornea and conjunctiva, but fail to find a foreign body. It may be there is evidence of a wound in the cornea; but if the foreign body is of very small size and with sharp edges, it may have made so clean a cut in the cornea that it is difficult to detect any wound. After careful inspection by focal illumination, we recognize the presence of the foreign body fixed in the iris. The question is, what are we to do? In the first place it is well to dilate the pupil as much as possible with atropine. We have seen cases of this kind in which the foreign body, a particle of steel, has fallen from the iris into the bottom of the anterior chamber, as the iris began to act under the influence of atropine. On the other hand it is more common in accidents

of this description to find that the foreign body has transfixed the iris and become fixed in the lens, so that the iris is unable at this point to dilate under the influence of atropine. In such a case we should open the cornea rather freely, in a position so as best enable us to pass forceps or other instrument into the anterior chamber, and then to take hold of the foreign body and withdraw it from the eye. If the foreign body consists of a chip of iron or steel, this operation may be facilitated by the aid of an electro-magnet. The removal of a foreign body from the iris is often a difficult proceeding, and unless we are fairly confident of success on account of the nature and position of the body, it is better in the first instance to make an incision through the margin of the cornea, and to excise that portion of the iris into which the foreign body has passed; after its removal, the eye must be washed freely with a solution of boracic acid or of corrosive sublimate, and closed with antiseptic dressings. A punctured wound of the lens, if it is small, and not too deep, may heal without leading to opacity of the whole lens. If a traumatic cataract has formed, the lens had best be extracted; and for the same reason if a foreign body has passed into the eye and fallen to the bottom of the anterior chamber, it should be removed through an opening made in the cornea for the purpose.

DETACHMENT OF THE IRIS from its ciliary border may be complete—that is the whole of the iris may be detached; or a mere slit may exist in its ciliary border. An accident of this kind usually occurs from an injury, as for instance from a blow with the fist upon the eye. In these cases the nature of the accident may not be detected in the first instance, on account of the effusion of blood which takes place into the anterior chamber. It will be necessary, therefore, to be guarded in our prognosis, as it is impossible to determine the extent or nature of the injury, or if it be complicated with detachment of the retina, until the effused blood has become absorbed.

If a portion of the iris has been detached from its ciliary border, as soon as the aqueous becomes clear, we shall notice a false pupil, varying in size according to the extent of the detachment of the iris (Fig. 33). The part of the pupil corresponding to the detached border of the iris is uninfluenced by the stimulus of light, its nerves and contractile

tissue having been torn through at the point of separation of the iris from its ciliary border.

In instances where the line of separation is narrow, it often requires a careful examination of the parts to detect the lesion, and to account for the otherwise inexplicable irregularity and inaction of a portion of the pupil.

FIG. 33.



A patient's sight is usually somewhat impaired by an accident of this kind, the irregularity of the pupil interfering with perfect vision; and if the rent in its ciliary border is a large one, a number of extraneous rays of light enter by the artificial pupil, and, falling on the retina, produce considerable confusion in the visual image. In a remarkable instance the whole of the iris was removed by Von Graefe; and what is most curious is the fact recorded by Mr. Soelberg Wells, that the patient's vision was as perfect without his iris as with it. Mr. Wells remarks of this case—"The field of vision of the right eye, in which the iris had been extracted, is normal; the sight most excellent, so that the patient can count fingers at the distance of 120—140 feet, and can read the smallest print. He possesses great power over the dispersed rays, and does not find himself in the least dazzled by the light. And lastly, to crown all, the accommodative power of this eye, with its *irideremia totalis*, is almost ($\frac{1}{6}$ — $\frac{1}{7}$)."

We can do little in the way of treatment in cases of detachment of the iris, beyond keeping the eye at rest, for the accident is irremediable, so far as the reparation of the injury is concerned.

LACERATION OF THE PUPIL.—A few cases of laceration of the pupillary margin of the iris have been recorded, following blows, and unaccompanied by either a wound or external injury to the globe of the eye. It is difficult to conceive how an accident of this kind can take place from concussion, nevertheless a rent of the pupillary border, and in other cases rupture of the fibres of the iris, have been known to follow it. As the opening in the iris is nearer the axis of vision than in detachment of its ciliary border, the defect of sight is greater, because the rays of light fall on the retina nearer the macula.

Coloboma of the Iris is a congenital defect due to non-closure of the foetal fissure, often associated with a similar

defect of the choroid. The slit is either downwards, or downwards and inwards, and frequently exists in both eyes; it may be partial or complete with reference to its extension or not to the ciliary border. In some rare cases the fissure in the iris is divided by a band forming a bridge.

TUMOURS OF THE IRIS.

CYSTIC TUMOURS OF THE IRIS are rare, and when met with, as a general rule, follow an injury to the eye, and the formation of a clot of blood in the substance of the iris; in fact they are small hæmatomas; but, independently of accidents, cystic tumours do occasionally grow from the iris. They usually appear as a small transparent vesicle springing from a broadish base attached to the anterior surface of the iris. Mr. Hulke remarks:—An examination of all the cases which I have been able to collect shows: I. That cysts, in relation with the iris projecting into the anterior chamber originate in two situations—(1) in the iris; and (2) in connexion with the the ciliary processes. The first lie between the uveal and the muscular stratum of the iris, and are distinguished by the presence of muscular fibres upon their anterior wall; the second lie behind the iris, and bear the uveal as well as muscular strata on their front. II. It also shows that these cysts are of more than one kind; that there are (1) delicate membranous cysts, with an epithelial lining and clear limpid contents; (2) thick-walled cysts, with opaque thicker contents (whether these are genetically distinct from 1 we are not yet in a position to determine, but it seems probable that they are so); (3) solid cystic collections of epithelium, wens, or dermoid cysts; (4) cysts formed by deliquescence in myxomata. III. As regards treatment, puncture, simple or combined with laceration, is so generally unsuccessful that excision is always preferable. It is evident that the chances of success will be proportionate to the completeness of the excision, and the practicability of this will vary with the size of the cyst and the extent of its connexions, and with its position in or behind the iris. It is clearly advisable, therefore, to excise the cyst, together with the segment of the iris from which it springs, as speedily as possible, otherwise the abnormal growth may excite dangerous irido-choroiditis, or sympathetic disease in the other eye.

A gumma may sometimes be seen springing from the iris in cases of parenchymatous inflammation.

The syphilitic history of the case should lead us to a correct diagnosis of the disease; and its treatment is comprised in that already recommended in parenchymatous iritis. There is only one condition of the parts which could be mistaken for the disease in question, and that is the presence of neoplastic growths, such as are sometimes observed on the iris in those who suffer from leprosy; but the history and appearance of the patient would at once inform us as to the nature of the disease.

MELANOMA AND SARCOMATOUS TUMOURS of the iris have been met with, the latter extending forward as a rule from the ciliary body. Cases of this kind have been removed with success.

CYSTICERCUS OF THE IRIS are occasionally met with: in a case described by Mr. P. Teale, in the *Ophthalmic Hospital Reports*, Vol. V., the cysticercus was attached to the iris, and was removed, together with a portion of the iris. The eye, prior to the operation, presented the following appearances:—On the surface of the lower part of the iris was seen an opaque body, constricted in the middle, and rather larger than a hemp seed, which was evidently causing some distress to the eye. The conjunctiva was slightly injected; the cornea was bright, but dotted on its posterior surface with minute spots, as in corneo-iritis; the iris was active, except at the situation of the white body, near which it was adherent to the capsule of the lens; tension normal. In instances of this kind the cysticercus may be excised, together with the portion of the iris to which it is attached.

LEPROUS AFFECTIONS OF THE IRIS are extremely common among persons suffering from this disease; in fact, in cases of leprosy of long standing, it is rare to find the iris and cornea healthy. We have observed that, as a general rule, the cornea is affected before the iris, and that plastic iritis is more common than the parenchymatous form of disease, to which we have already referred, page 181.

FUNCTIONAL DISEASES OF THE IRIS.

MYDRIASIS is an abnormal dilatation of the pupil, occurring independently of disease of the retina or other structures of the eye. The pupil does not contract on exposure to light, and the patient suffers from impairment of vision, in consequence of the excess of light admitted into the eye. This defect is remedied by placing a diaphragm, with a small hole drilled through it, in front of the eye. The outer rays of the cone of light impinging on the retina being cut off, the defective vision is in great part corrected; and the patient, while looking through the hole in the diaphragm, sees well. This contrivance will not, of course, overcome defects due to loss of accommodation, depending on causes similar to those which induce the mydriasis. The same result may be attained by causing the pupil to contract by the application of eserine to the eye. The above definition of *mydriasis*, therefore, excludes all cases of dilatation of the pupil depending on deep-seated disease of the eye, or from the tonic effect of certain drugs.

Mydriasis may be confined to one eye, or both eyes may be affected. The cause of the dilatation of the pupil may be the suspension of the functions of the third nerve, the circular fibres of the iris being thus paralysed, for when this nerve is divided the pupil remains dilated. The same effect may be induced by irritation of the cervical branches of the sympathetic, which are distributed to the dilator pupillæ; this muscle being thrown into action, the pupil dilates. In this way abnormal dilatation and fixation of one or both pupils may be met with after a contusion of the eye, exposure to cold, and following diphtheria; it sometimes accompanies paralysis of the muscles of the eyeball.

The Treatment of mydriasis must depend on the nature of the disease. In some few instances it appears to arise from reflex action, excited by the presence of a foreign body on the cornea or conjunctiva; or it may be that some more distant branch of the sentient nerve is in the first instance affected, the irritation being conveyed by reflex action through the oculo-motor nerve, and thereby destroying the contractile power of the circular fibres of the iris. In these cases our first care should obviously be to remove, if possible, the cause of the irritation.

If the mydriasis appears to depend on defective action of the third nerve, faradization may be useful; the action of the galvanic current, however, should never be continued for more than a few seconds at a time, and if the pupil does not contract speedily under its influence, we can expect but little benefit from continuing this treatment. Should the patient have suffered from syphilis, the case must be treated upon the principles generally applicable under such circumstances.

If the dilatation of the pupil results from irritation going on in the intestinal canal, whether excited by worms or any other cause, and propagated through the sympathetic to the radiating fibres of the iris, we must endeavour to remove the source of irritation by anthelmintics in one case, and by a blue pill and black draught in another. Some such source of irritation, it may be connected with bad teeth, are the most frequent causes of mydriasis. The affection may sometimes be relieved in a marked way by the instillation of a solution of eserine, but can hardly be cured unless by appropriate treatment directed towards the restoration of the functions of the stomach, liver, or any other source of irritation.

MYOSIS is precisely the opposite condition to mydriasis; the faulty innervation causing the pupil to become abnormally contracted, and failing to dilate as it should do when the patient is placed in a dark room, or after sunset. The pupil will, however, expand under the influence of mydriatics; and it may then be noticed that it is perfectly regular, and hence its inability to dilate is clearly not dependent on synechiæ. The contraction of the pupil under ordinary circumstances is a reflex action, excited by the stimulus of light falling on the retina, and being propagated to the oculomotor nerve, so that the circular fibres of the iris contract and close the pupil. If only a small quantity of light enters the eye, as is the case after sunset, its action on the retina is slight, and consequently the excitation of the third nerve is proportionably less than in daylight, the pupil remaining semi-dilated. Division of the sympathetic in the neck is likewise followed by contraction of the pupil, the *dilatator pupillæ* being paralysed; lesions of the spinal cord affecting the sympathetic may thus produce myosis; so that, in instances of myosis, we must consider all the circumstances of the case by the light of our knowledge of the physiology

and pathology of the third and sympathetic nerves. This condition is occasionally caused by long-continued work upon minute objects, as for instance in watchmakers, the sphincter muscle of the iris acquiring a preponderating power over the dilator.

Cases of myosis are sometimes mistaken for hemeralopia (night blindness), in that the patient complains principally of impairment of vision coming on after sunset, which evidently depends on an insufficiency of light reaching the retina through the contracted pupil, to produce distinct vision. The patient has no pain in the eye, and his sight is good during the day. The case very much resembles one of hemeralopia, with this difference, however, that in hemeralopia the pupil acts freely, the disease essentially consisting in a temporary loss of power in the retina, arising from over-stimulation, or from anæmia of its nervous elements; the latter being by far the most common cause of night blindness. We know at present so little about the functions of the sympathetic, that it is impossible to understand why, in some cases of habitual constipation, or of dyspepsia, myosis occurs. We suppose that it arises from some disturbance of the sympathetic, propagated to the branches supplying the iris—a very vague explanation it is true, but the best we can give of the matter. In cases of this kind, our wisest plan of treatment is to correct and improve the state of the digestive organs as far as we can.

Irritation of the oculo-motor nerve arising from meningitis, or a clot of blood, or other affection involving the nuclei of these nerves, may induce contraction of the pupil; but, in these circumstances, the myosis is a very unimportant matter in comparison with the primary disease. The contracted state of the pupils in cases of *tabes dorsalis* is frequently seen among out-patients at our hospitals; and is characterised by the condition known as the *Argyll-Robertson pupil*.

Artificial mydriasis and myosis may be induced respectively by the action of atropine and Calabar bean, as well as by some other drugs.

TREMULOUS IRIS (*iridodonesis*) is seldom met with unless the lens has been removed. As the iris rests on the crystalline, we can readily understand that when the lens is taken away, the iris having lost its support, hangs like a loose curtain in the anterior chamber, and consequently has a

tremulous movement imparted to it when the eye is turned sharply in any direction. The same result may occur from an excess of aqueous in the posterior chamber, forcing the lens backwards and the iris forwards (hydro-ophthalmia)—a condition but rarely seen. If the vitreous is in a fluid condition, the lens may recede from the iris, and iridodonesis result; in these circumstances the ophthalmoscope will reveal floating bodies in the vitreous, and indicate the nature of the disease, and the cause of the tremulous movements of the iris.

OPERATIONS OF CORELYSIS, ARTIFICIAL PUPIL, IRIDECTOMY.

Corelysis.—The steps to be taken in performing the operation of corelysis are as follows:—A solution of atropine must first be dropped into the patient's eye, three or four times a day, for a week prior to the operation; we shall thus be able to discover those parts of the margin of the pupil which are still free from adhesions, by the pupil dilating at those points; and, as our object is to insert a small spatula through an opening of this kind, between the lens and iris, and then carefully to break down the synechia with the instrument, so as to free the iris from the capsule, this careful study of the condition of the parts, before we attempt to operate, is very necessary.

The eye having been cocainised, and the patient placed in the recumbent position (it is safer in most cases to administer an anæsthetic), a stop-speculum is adjusted, the surgeon, standing behind his patient, secures, with a pair of fixing forceps a fold of conjunctiva close to the margin of the cornea, so as to steady the eyeball. A sufficiently large puncture is then made in the cornea, as nearly as possible opposite to the principal adhesion; a Streatfeild hooked spatula is inserted through the wound into the anterior chamber, and the blunt extremity of the instrument is passed under the margin of the pupil, and between the iris and lens (its point being carefully directed away from the latter) and far enough beneath the iris to enable us by a slight lateral and traction movement, to lift the iris away from the lens and break through the synechia. The hook near the extremity of the instrument is very useful, enabling us to tear through any tough bands of adhesion, which might otherwise become elongated when force is applied, and so

elude our best efforts to reinstate the pupil. It is necessary to be careful not to wound the capsule of the lens during this operation. Those parts of the synechia only which are opposite the point of puncture in the cornea, should be broken through during one operation; for instance, if the adhesions we propose dividing are situated on the inner side of the pupil, but if there are also others above and below the pupil, we should make our puncture in the outer part of the cornea, and passing the spatula through it, insert the point of the instrument beneath the inner margin of the pupil, breaking down the adhesions in this situation and leaving those above and below for a future operation. For the division of these, the punctures must be made in the lower and upper part of the cornea respectively.

It is a point of some importance in operating, to take care that the aqueous humour is prevented from escaping, till after the synechia is broken through. This may generally be managed by having a spatula just large enough to fill the puncture made in the cornea. It is impossible to lay down any precise rules as to the distance from the margin of the cornea at which the opening should be made. Our aim should be to select a spot which will most readily admit of our passing the spatula through it, in such a direction as to avoid the lens and enable us to break through the adhesions at the greatest advantage. The after-treatment is very simple. Atropine must be dropped into the eye three times a day, so as to dilate the pupil as far as possible, and the eye is to be kept closed with a pad and bandage for ten or twelve days; we may then proceed to break through any remaining adhesions, if the irritation caused by the former operation has subsided.

ARTIFICIAL PUPIL. CONDITIONS REQUIRING AN ARTIFICIAL PUPIL.—The end we have in view is, to make an opening for rays of light to reach the retina, when they are otherwise prevented doing so by a central opacity of the cornea, a closed pupil, or other obstruction. The operations usually employed for this purpose are, First, with a broad needle, or narrow-bladed keratome and Tyrrell's hook. Second, iridectomy.

The conditions necessary, therefore, for the successful performance of this operation are—First, that a portion of the cornea is transparent, and its curvature not greatly altered, otherwise the refraction of the rays of light which reach the

retina may be so much deranged as to lead to irremediable impairment of vision. Secondly, if the iris is completely adherent to the lens or cornea, we can hardly expect to form an artificial pupil. Lastly, the lens and internal membranes of the eye must be tolerably healthy, otherwise making an opening in the iris will scarcely improve the patient's sight. We may generally form a tolerably accurate opinion as to the state of the retina in these circumstances, by holding a bright lamp in front of the affected eye. The degree in which the patient is conscious of the illumination will be our guide to the amount of retinal sensibility; if he cannot distinguish the existence of the flame it will be almost useless operating. The tension of the eyeball will also afford us valuable information as to the condition of the deeper structures. In many instances the globe will be found soft and hopelessly atrophied; in other cases its tension may be increased from intra-ocular pressure; in either case, our chance of success by means of an artificial pupil will be lessened.

In cases of central opacity of the cornea, whether complicated with staphyloma or not, but obstructing the passage of light to the retina, it is well in the first place to apply atropine to the eye, and thus discover to what extent the pupil is dilatable. It will be advisable to make an artificial pupil downwards and inwards if possible, but should the cornea be opaque in this position, we must make an opening in the iris downwards and outwards; and failing this, behind the most healthy part of the cornea. But if, in central opacity of the cornea, we find the pupil will not dilate, the iris being fixed to the capsule of the lens or to the cornea, it will be necessary to employ the forceps in order to withdraw a fold of iris from the eye, which must then be snipped off by an assistant. With regard to the dimensions of an artificial pupil, this will depend much on the condition of the cornea; but as a general rule, we may endeavour to make our opening through the iris about the size of the healthy semi-dilated pupil.

It may, however, be necessary to make an artificial opening through the iris under other circumstances than those of opacity of the cornea; as for instance, after injuries or wounds of the cornea, where a prolapse of the iris has taken place into the wound and the pupil has been drawn into the cicatrix. Such an accident sometimes occurs after extraction of the lens. In cases of this

kind, it will be well to use the forceps, excising a fold of the iris as nearly as possible in the axis of vision. To prevent any dragging on the iris during the operation, the opening in the cornea must be made well forward, in fact, as near as possible to the position of the artificial pupil, without being actually in front of it.

Lastly, an artificial pupil may be necessary in certain forms of posterior capsular cataract, the margin of the lens being transparent. A cataract of this kind has often but little tendency to extend, and therefore it may be unnecessary to remove it; but the pupil may be advantageously displaced towards the transparent margin of the lens.

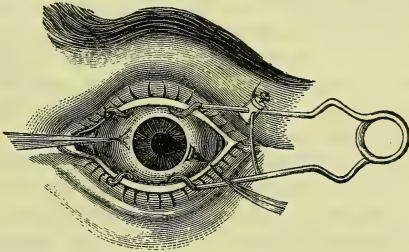
We are often consulted by patients having one sound eye, and the other damaged, and the question arises as to how far it is advisable to attempt to improve his vision by making an artificial pupil. As a rule, if the diseased eye is perfectly quiet and has been so for some time, it is better not to make an artificial pupil, unless by so doing the opening made in the iris is likely to restore binocular vision; if eccentric this is hardly likely to be the case, although it may bring both eyes into play. It will be necessary, before operating in cases of this kind, to ascertain the amount of vision the patient possesses with the diseased eye; it is useless interfering if it has little or no perception of light.

TYRRELL'S OPERATION FOR ARTIFICIAL PUPIL.—It is well to give an anæsthetic, unless the patient can bear some amount of pain, when the eye may be cocainised. The patient being laid on his back upon a couch in front of a good light, and a stop-speculum adjusted, the eye must be washed well with an antiseptic fluid. The surgeon standing in the position most convenient to effect the work he has to perform, secures the eyeball by seizing a fold of the conjunctiva, near the margin of the cornea, with a pair of toothed forceps. He then passes a broad needle through the margin of the cornea, at a spot nearest to the point at which he proposes excising the iris. A Tyrrell's blunt hook is to be inserted sideways through the opening in the cornea, and passed onwards until its hooked extremity reaches the margin of the pupil, when it is to be turned downwards, so as to hook over the pupillary margin of the iris. The instrument is then to be carefully withdrawn from the eye, being again partly rotated, and dragging with it a small fold of the iris. Immediately this fold is drawn out beyond the wound in the cornea, an assist-

ant should snip it off, close to the edges of the wound, with a pair of curved scissors. A spud, or other blunt instrument, should be inserted through the wound so as to disentangle the iris and prevent it from becoming involved in the cicatrix as the wound heals; the speculum is then to be removed, and the eye kept closed with a pad and bandage for a few days.

If an extensive and deep opacity of the cornea exists immediately in the axis of vision, preventing our seeing the edge of the pupil, although it may have been dilated with atropine, it is evident that we cannot perform the operation above described. It would be a dangerous proceeding to grope about with the blunt hook in the anterior chamber, in the hope of seizing the pupillary margin of the iris, which we cannot see through the opaque cornea. In these circum-

FIG. 34.



stances a modification of Tyrrell's operation is rendered necessary.

In place of passing a hook into the anterior chamber, it will be requisite to make the opening in the margin of the cornea sufficiently large to allow of a pair of cannula or iridectomy forceps being introduced into the eye. A fold of the iris, as near as possible to its pupillary margin, is to be seized, and having been withdrawn through the wound, is to be snipped off close to the cornea by an assistant (Fig. 34). Care must be taken that the iris is, if practicable, excised from its pupillary margin outwards, and that no tags of it are allowed to remain in the wound.

2. IRIDECTOMY.—The instruments required for this operation will be a stop-speculum, to keep the eyelids apart; a pair

of fixing forceps, to steady the eyeball with ; a broad lance-shaped knife, either straight or bent according to the direction in which we propose making the iridectomy ; a pair of iris forceps ; and lastly, curved scissors. Dr. Wecker's iris scissors are useful in this operation. The patient having been placed in the recumbent position, it is, as a general rule, advisable to get him fully under the influence of ether ; the stop-speculum is then to be adjusted ; and the eye well washed with an antiseptic fluid.* The surgeon, either in front or behind the patient, standing or sitting as he may find it most convenient, seizes a fold of the conjunctiva, opposite the intended point of puncture, with a pair of fixing forceps, so as to steady the globe of the eye. He then passes the keratome (or a Graefe's knife if he prefer it) through the sclero-corneal junction, at a point from $\frac{1}{2}$ to $1\frac{1}{2}$ lines behind the margin of the cornea, and thrusting the blade of the instrument steadily onwards, close in front of the iris, an opening about a quarter of an inch long is made in the sclerotic. The keratome is then to be slowly withdrawn, so that there is no sudden rush of aqueous from the eye. If the anterior chamber is very shallow, the incision may best be made with a Graefe's knife, there is less risk of wounding the lens with this instrument than with a keratome.

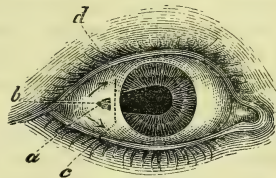
The surgeon, still fixing the globe of the eye with one hand, takes a pair of iridectomy forceps in the other ; and if the iris does not protrude through the wound, he inserts the points of the forceps (closed) through the wound, seizes a fold of the iris about midway between its ciliary and pupillary borders, and drawing the fold of iris out through the wound, an assistant cuts off the requisite amount of iris with a pair of scissors, close up to the edges of the wound in the cornea. In many cases of glaucoma, after the opening has been made in the cornea, the iris protrudes through the wound ; this is an advantage, for it enables us to seize a fold of the iris without inserting the forceps into the anterior chamber.

The fold of iris may be excised as above, or it may be cut off by either of the following proceedings. The iris is brought outside the globe as above described, and divided with small scissors, on one side of the forceps, from the pupillary to the

* Some surgeons are content with cocaine to render the eye insensible to pain in this operation, unless there is some reason for not administering ether, or it may be chloroform, the eye is safer under an anæsthetic, and of these ether is to be preferred to chloroform.

ciliary border, the forceps pulling it gently at the same time, so as to ensure complete division of the iris. The end of the iris held by the forceps is then torn from its ciliary attachment as far as the angle of the incision, and even dragged upon a little so as to detach it beyond the angle, and divided with the scissors quite close to the angle. The cut end of the iris retreats within the chamber; the opposite side of the prolapsed part is then seized and dealt with in the same manner. But however the iris is excised, great care must be taken that none of it is left between the lips of the wound, lest the healing process be imperfect, and subsequent irritation occur in the eye. This proceeding is shown in Fig. 35; *a*, the prolapse, divided into two portions at *b*. The lower portion is to be drawn, in the direction of *c*, to the lower angle of the incision, and snipped off. The upper portion is then to be drawn in the direction of *d*, and also divided.

FIG. 35.



Instead of dividing it into two portions, the prolapse may be drawn to one angle of the incision, and partly divided close up to the angle; the other portion, being then gently torn from its ciliary insertion (slight snips with the scissors aiding in the division), and drawn to the opposite angle, is there to be completely cut off. This is illustrated in Fig. 36;

FIG. 36.

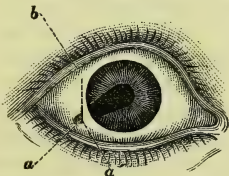
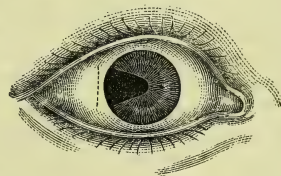


FIG. 37.



a, the prolapse drawn down to the lower angle *a'* of the incision, where the inferior portion is to be divided, and the other drawn up in the direction of *b*, to the upper angle of the incision. The latter proceeding is perhaps to be preferred if there is much bleeding, for then it is not always easy to find the uncut portion, more particularly if it has slipped

back between the lips of the wound. Either method will yield an excellent artificial pupil. The iris will be torn away quite up to its ciliary attachment, and the pupil will consequently reach quite to the periphery (Fig. 37).

If there is any hæmorrhage into the anterior chamber the fluid-blood should be permitted to escape before coagulation. To effect this object a small curette should be inserted between the lips of the wound, slight pressure being at the same time made upon the eyeball with the fixation forceps so as to facilitate the escape of the blood. The curette should not be inserted into the anterior chamber; if the blood does not flow off readily, it may be permitted to remain; it will soon be absorbed. The excision of the iris having been completed, the stop-speculum is to be removed, and the eye kept closed with a pad and bandage. If the patient suffers much pain subsequently to the operation, morphia may be administered; but this is seldom necessary.

In performing the operation of iridectomy, the chief points to attend to are to make a sufficiently free opening into the anterior chamber. With a wound less than a quarter of an inch long it is almost impossible to complete the operation satisfactorily. A larger opening in the sclerotic can do no possible harm; the wound will close in twenty-four hours; there is no fear of prolapse of the iris; a free opening is most essential to the success of iridectomy. The points of the knife must be kept midway between the iris and cornea. By attending to this rule, both the lens and cornea will escape injury. It is necessary that the ciliary attachment of the iris should, if practicable, be divided. The edges of the wound must be carefully freed from any portion of the iris; if tags of it are left between them, a troublesome fistula of the sclerotic may form, or continued irritation of the iris and sympathetic irritation in the other eye established.

With regard to the position of the opening to be made in the iris, other circumstances being favourable, the superior section of the iris should be removed, as the upper lid covers the part to a considerable extent, and in this way lessens the blurring caused by the excessive amount of light which would otherwise reach the retina. In instances of ulceration or opacity of the cornea, the position of the iridectomy must be adapted to the circumstances of the case. The after-treatment consists in keeping a pad and bandage over the eye; the wound in the sclerotic heals in three or four days. Never-

theless, it frequently happens, that a few days after the operation of iridectomy the tension of the eyeball increases, and continues in this condition for some time, when the intra-ocular pressure diminishes, but the full advantages of the operation are not perfected, until it may be six weeks, or even two months' time after it has been performed. Iridectomy is especially called for in glaucoma, acute serous choroiditis, irido-choroiditis, rapidly advancing or intractable ulcers of the cornea, and in combination with other operative means for the removal of the lens.

CYCLITIS.

From the similarity which exists between the structures of the iris and the ciliary body, and their direct connection with one another, it is evident that inflammation of the iris is likely to spread backwards to the ciliary body, or it may commence in the latter structure and extend to the iris.

PLASTIC CYCLITIS.—This is the most common form of cyclitis. In the early stages of plastic cyclitis we find that its blood-vessels are congested, and the surrounding tissue infiltrated with cell-elements from which neoplastic formations grow. In some cases, leucocytes from the engorged vessels pass forwards, not only to the iris, but fill the posterior chamber, and unless speedily absorbed, extensive synechiæ form, leading to the obliteration of this chamber. The exudation may extend over the posterior surface of the lens, and traverse the whole uveal tract; in cases of this kind the retina frequently becomes affected, sending out tubular excrescences from its uveal layer into the cyclitic membrane; these processes have been mistaken for bloodvessels. At a subsequent stage of the disease, calcification of the choroid and ciliary body may occur. But prior to such changes the neoplastic tissues will, as they become organized, contract, and in doing so they obliterate the vessels of the ciliary body, and lead to opacity of the lens; from the same cause, detachment of the ciliary body, the choroid or retina may occur, and too frequently the eye becomes atrophied.

Symptoms.—In cases of plastic cyclitis there is congestion of both the deep and superficial vessels surrounding the cornea, and the peri-corneal zone is therefore well marked. The patient often suffers from acute pain in the eye and

always from tenderness on pressure over the region of the ciliary body. The iris is discoloured and pressed forwards towards the cornea, synechiæ form; and the vitreous becomes more or less opaque. As a result of the action going on in the ciliary body and choroid, not only is the episcleral zone of vessels engorged, but numerous large and tortuous bloodvessels may be seen on the surface of the iris. If the disease is not checked at an early stage the patient's sight is permanently impaired, and too frequently completely destroyed.

Causes.—Excluding cases of “sympathetic cyclitis,” the most frequent cause of plastic cyclitis is syphilis; but the disease may arise from an injury to the eye, such as an incised wound over the ciliary region, the lodgment of a foreign body in the eye, or the forcible removal of a piece of opaque lens capsule, if during the operation the ciliary processes are dragged upon by the surgeon.

SEROUS CYCLITIS.—At a meeting of the Ophthalmological Society, held on the 12th of March, 1891, Mr. E. T. Collins described a glandular structure, which he had discovered beneath the epithelial layers lining the ciliary processes of the choroid. The existence of these glands seems to clear up much that was obscure regarding the pathology of serous cyclitis, for we can readily comprehend how increased action of these glands might pour out an excess of serous fluid into the vitreous, choroid, and iris, and so induce the symptoms characteristic of serous cyclitis. This condition is hardly ever found independently of iritis. It is characterised by the effusion of serous fluid into the ciliary body, posterior and vitreous chambers. In some cases the tissue of the ciliary body becomes distended by the effusion, so as to present the appearance of a trabecular network. Synechiæ form and the iris becoming fixed to the lens, the serous fluid collects behind it and bulges the iris so far forwards as almost to touch the cornea. At the same time the epithelial cells of the posterior layers of the cornea become opaque in patches (*keratitis punctata*).

Symptoms.—Serous cyclitis commences with impairment of sight from opacity of the vitreous usually in one eye. The patient complains of a cloud or film over the visual field of the affected eye, which increases day by day. He has considerable pain in the eye, and tenderness on pressure over the ciliary region; the amount of pain, however, varies much in

different cases. On examining the eye we notice subconjunctival injection, often limited to isolated segments of the scleral zone. The aqueous humour is turbid, and in some instances flakes of opaque matter may be detected floating in it. The posterior layer of the cornea is hazy and dotted; at this stage of the disease the symptoms may abate and the eye resume its functions; but in most cases before long there is a recurrence of the attack, and as the disease advances the iris is discoloured, and the pupil is tied down by adhesions of greater or less extent to the capsule of the lens; in some cases the pupil is entirely closed by neoplastic formations passing between it and the capsule. A few distended vessels may be seen coursing over the iris, and these are apt to give way and cause hæmorrhage into the aqueous chamber. If the dioptric media of the eye are sufficiently transparent to allow of our examining its deeper structures, the vitreous will be found hazy, with flocculent bodies moving about in it. The tension of the eyeball is increased. If the disease advances, the subconjunctival injection is augmented, and so also is the tension of the eyeball; at the same time the patient's vision becomes more impaired. The synechiæ increase, and the fibrous structure of the iris is more and more disorganized, it becomes relaxed, and finally the iris projects into the aqueous chamber irregularly, attaining a spongy appearance. This bulging forward of the iris is very marked, and is due to the collection of serous fluid behind, forcing forward those attenuated portions of the iris which are not tied down to the capsule of the lens. In the meantime the neoplastic growths about the pupil have been increasing, becoming organised and contracting so that the pupil may be closed by a false membrane; it assumes an irregular shape, appearing as an opaque patch or spot in the centre of the bulging iris. When the disease has advanced thus far, the tension of the globe may become lessened. The iris undergoes degeneration, and the patient's sight is in fact almost lost, the globe rapidly undergoing atrophy.

SUPPURATIVE CYCLITIS is most commonly observed after incised wounds, or rupture of the ciliary region and the admission of septic matter to the injured tissues; suppuration into the ciliary body follows, and unless speedily relieved, ends in abscess of the globe of the eye. From whatever cause the suppurative inflammation of the ciliary body starts, in consequence of its relation to the deeper

tissues of the eye, the retina, lens, and vitreous seldom escape without irreparable mischief.

Symptoms.—The symptoms of purulent cyclitis are those of the plastic form of the disease intensified; the pain is often very great, the sclerotic zone of vessels and also those of the conjunctiva are much congested. The patient's sight is rapidly lost, the iris is cloudy, the lens and vitreous speedily become opaque; pus not unfrequently finds its way into the anterior chamber, and the eye is totally destroyed.

Prognosis.—As in iritis, so in cyclitis, the prognosis will be more favourable in the serous than in the plastic form of disease. But whatever the form of the cyclitis, the first point we should consider in our prognosis is as to the state of the patient's vision. We should notice if he can see large objects—if he can count fingers held up before the diseased eye; whether he can discern the flame of a candle in a dark room; if not, in all probability extensive lesions of the vitreous, choroid, and retina exist in addition to the cyclitis; but if the patient can count fingers or other large objects held before his eyes, we may reasonably hold out hopes of improvement, especially if the pupil dilates under the use of atropine. We shall also be guided in our prognosis by the tension of the globe; if the eyeball is soft we can hardly expect any amendment to occur, although, if its tension is only slightly diminished, it is just possible some improvement may take place.

Treatment.—The treatment of cyclitis depends on its cause, and the stage to which it has advanced when first brought under our care; if, as is not unfrequently the case, it depends upon sympathetic irritation or to disease propagated from the other eye, the sooner the diseased eye is removed the better.

When the cyclitis is referable to syphilis, we may, in the early stages of the disease, by means of atropine, hope to keep the iris away from the lens, and so prevent the formation of synechiæ; at the same time, mercury and iodide of potassium must be administered.

Serous cyclitis is most frequently met with in females suffering from vaginal or uterine troubles; and to effectually treat the cyclitis we must combat, if possible, the disorder which is the cause of general ill-health; local treatment, so far as the eye is concerned, will otherwise fail to cure a case of cyclitis depending on these causes. In both

plastic and serous cyclitis we have referred to the liability that exists for synechiæ to form, and to overcome this state of things we must resort to the operation of iridectomy; it is our only hope in this formidable disease. It not unfrequently happens, however, that in performing an iridectomy in cases of cyclitis, we find that the iris is so firmly bound down to the capsule, that on attempting to withdraw a fold of iris, it is so rotten that it breaks away from its attachments to the capsule, leaving a piece of iris attached to the lens. In these circumstances we may, with advantage, subsequently perform a second iridectomy from the other side of the eye, if possible, excising a portion of the upper and lower sections of the iris. Nor does it always follow that the excision of a second portion of the iris is sufficient for our purpose. In bad cases of cyclitis we have Sir W. Bowman's authority for excising a third section of the iris. One reason for this is, that it is not improbable that the space from which we have excised a piece of the iris on the first and second occasions may have been, or may subsequently become, filled in by uveal growths, preventing light from reaching the retina; nevertheless, these primary operations will have reduced the hyperaction going on in the part, so that subsequently to our third iridectomy, the space occupied by the opening through the iris may remain clear; and thus the last operation is by far the most satisfactory, particularly in cases of serous cyclitis. In the plastic form of disease, we cannot but fear, under any circumstances, that neoplasms will materially interfere with our best endeavours, and will occupy the space partially cleared by removal of a portion of the iris. In cases of this description we must not only remove a piece of the iris, but, in addition, the neoplastic growth behind it. The straight iridectomy forceps are best adapted for removing such an iris; with this instrument portions of false membrane adhering to the posterior surface of the iris may be taken away, but their removal often endangers the lens; for this reason, and also because the lens pressing on the iris may add to the risk to which such an eye is exposed, Von Graefe advises the removal of the lens in addition to an iridectomy, by means of the following operation:—

He makes the flap, if the condition of the cornea permits it, downwards, avoiding, if possible, wounding the iris; but if the latter is greatly bulged forward, he passes the knife

boldly through it, and in the latter case the capsule is already sufficiently divided to permit the ready egress of the lens. If this is not the case, or the iris has remained untouched, he introduces a pair of straight forceps or a hook, and removes or tears as much of the iris and membrane as is necessary to permit the exit of the lens. After the operation a compress is to be applied, firm at first, and afterwards somewhat looser. There is generally only very slight reaction, so that it is only necessary for the patient to remain in bed for a day or two, and from five to seven days in a darkened room.

In some of these cases the condition of the iris begins to improve after the lens has been removed. The anterior chamber becomes wider, and some patients have a little better perception of light. In many cases the ciliary neurosis is also much diminished. For bleeding into the anterior chamber a soft compress is best; sometimes the absorption of the blood may take as long as two or three weeks.

A month or six weeks after the extraction of the lens, an iridectomy is to be performed. Von Graefe makes a large linear incision, and passes a sharply-pointed hook perpendicularly through the tract of the membranes. If, on traction of the hook, a clear black pupil of middling size becomes apparent, and the vitreous humour penetrates into the anterior chamber, he considers the dilaceration as sufficient. If this is not the case, a blunt hook or a straight pair of forceps should be introduced and the opening enlarged. The same will be necessary if a secondary cataract appears in the newly-made pupil. After this operation, according to the late Prof. Von Graefe, the cornea becomes plumper, and may re-acquire a good amount of curvature, but we cannot say our experience coincides with his in this respect.

Sympathetic (Ophthalmitis) Cyclitis—*Septis and Neurotic Cyclitis*.—Sympathetic ophthalmitis as it was formerly called, is an affection of the eye which has always excited much interest and given rise to considerable controversy. It is essentially an affection of the ciliary body and uveal tract of one eye following an injury of the other eye, seldom commencing for three weeks and often much longer after the injury. As a rule disease of this kind when once it has been established leads to complete loss of sight in the affected eye, and as the other eye has probably been destroyed by the injury total blindness is too frequently the termination of

cases of this description. The degenerative changes which occur in the uninjured eye in the greater number of cases run a remarkably insidious course, creeping on month after month, or year after year, without pain, to the complete destruction of the eye. But we meet, though less frequently, with another class of cases in which, after a wound of one eye exposing the ciliary body and with more or less prolapse of that structure and the iris, inflammation sets in and leads to disorganization of the eye. It may be three weeks or as many months after the accident, the patient complains of dimness of vision in the other eye; there is pericorneal congestion, pain over the ciliary body and other symptoms of cyclitis, which run on in spite of treatment to the destruction of the second eye. So that the termination is similar to that of the first or insidious, and almost painless class of cases to which we have referred, the commencement of the trouble in the second eye in both class of patients is the same, namely, an injury to the other eye, but it seems probable that the pathological changes leading to this result differs in the chronic, and in the more acute cases.

From the investigation of biologists in this and other countries, it has been demonstrated that in some instances of the more acute form of sympathetic cyclitis, commencing in a wound of one eye that micro-organisms have been developed in this wound, exciting septic inflammation, and these micro-organisms have been traced along the lymphatic channels to spaces in the sheath of the corresponding optic nerve, and so to the uveal tract of the other eye. The micro-organisms having passed into the second eye in this way have there produced inflammation, and led to the destruction of the eye. It may be, however, that in a case of injury to one eye the wound heals, and in the course of months the eyeball shrinks up, and remains in a passive condition for two or three years. Then, perhaps, without any assignable cause the stump becomes painful, or without pain or signs of irritation in the injured eye, the patient finds his other eye growing dim, he sees floating bodies in the field of vision and loses his power of accommodation; these symptoms creep on, sometimes taking several years to run their course to total blindness. On examining such an eye atrophy of the tissues forming the uveal tract will be found, and degeneration of the lens, retina, and in fact of the contents of the eyeball.

It seems to us while fully admitting that cyclitis resulting

from a wound, and the admission of septic matter into the ciliary body may induce septic inflammation in the other eye, by the passage of micro-organisms from one eye to the other; it is quite possible that Mackenzie and his school were correct in attributing the degenerative changes in the chronic cases above referred to, to sympathetic or perverted nerve action. The train of changes in the second eye, consisting in atrophy of the tissues consequent on peripheral neuritis of the nerves corresponding with those implicated in the cicatrix, and other structures undergoing atrophic degeneration in the injured eye. We are acquainted with similar instances of disease due to peripheral neuritis in other parts of the body, and nerve irritations such as that sometimes caused by caries of the teeth, appear to exercise a decided influence upon the innervation and irritation of the eye on the side corresponding to that of the diseased teeth. However this may be, for us surgeons, one fact stands out prominently from the study of these cases; which is that an injured eye is likely to excite destructive changes in the other eye of a septic nature, or by some more insidious process; consequently we should remove the source of danger to the other eye by enucleation of the injured one; and this operation should be insisted on in all cases where the injury has been of such a nature as to destroy the sight; there can be no object in preserving such an eye, and it may, soon after the wound has been received infect the other eye, or destroy it at some subsequent time, through irritation of its nerves exciting peripheral neuritis in the corresponding nerves of the other eye. Supposing, either by antiseptic treatment or otherwise, the injured eye is preserved from septic infection, that is no reason for not removing it, because it may in after years destroy the other eye by reflex or sympathetic action. And we have here another most important clinical feature to insist on, which is, that if septic matter has passed from one eye to the other, the removal of the first eye will not stop the progress of the disease in the second eye. It is by early enucleation of the injured eye only, that we can be certain of preserving the other eye from infection. Should six months have passed after the primary wound has healed, and so the risks of septic infection have probably passed away, there is still the danger of peripheral neuritis in the other eye, and when once this affection of the nerves has commenced the removal of the injured eye will not stop the neuritis; the only way to

arrest this evil, is to remove the injured globe before the irritation of its nerves has commenced, to excite those most insidious and dangerous changes in the nutrition of the other eye, which terminate in complete loss of vision.

The question therefore arises as to how soon after a wound of one eye, by which its outer covering has been opened, are we to remove the injured globe. After such an injury there will be much effusion of blood into the eyeball. The eye and wound must be treated on strict antiseptic principles until this blood has been absorbed, probably in twelve or fifteen days. If the patient has then no perception of light, the injured globe should be enucleated at once. If the patient, however, has perception of light, we must put off our operation until we find out how much sight he may regain, for we should in very exceptional instances only, remove an eyeball when the patient has any distinct perception of objects with the injured eye. It may be well to observe that this rule applies only to cases of injury to the eye, in cases of suppuration or abscess of the globe of one eye, it is probable the lymphatic channels are occluded, and the nerves completely destroyed by the inflammatory process. However this may be, practically we find that after acute inflammation of the contents of the globe of one eye, there is little danger of sympathetic ophthalmia in the other eye. So that there is no such necessity for enucleating an eye which has been destroyed in this way, in order to preserve the other eye, as there is in cases of injuries inflicted on an otherwise healthy eye. The treatment of the second eye, in which disease has been established by infection, or by nerve irritation is most unsatisfactory. We should endeavour to keep the pupil fully dilated with atropine, and the eye should be maintained in a state of perfect rest. By a soothing plan of treatment we may hope to quiet down the inflammatory attack from which the patient may be suffering, at any rate for the time being; but recur it is almost certain to do, and each attack adds to the damage already inflicted on the eye. Nor can we with any confidence fall back upon an iridectomy in instances of sympathetic cyclitis; in the early stages of the disease it may perhaps be attempted, but with little hope of relief; in the latter stages the iris becomes so rotten, and firmly glued down to the capsule of the lens, that it breaks away when seized by the iridectomy forceps, and it is useless therefore attempting the operation.

CHAPTER VIII.

THE CHOROID.

Structure — Choroiditis — Varieties — Tubercle — Sarcoma — Injuries — Detachment — Posterior Staphyloma — Colloid Disease — Coloboma — Ossification.

THE CHOROID.

THE choroid is the vascular tunic of the eyeball, supplying nourishment to the retina and the outer part of the vitreous. It is bounded on the outside by the sclerotic to which it is loosely attached, and on the inside by the retina with which it is intimately connected; this tunic extends backwards from the ciliary bodies over the posterior part of the globe, and is perforated by the optic nerve and retinal vessels; the optic nerve opening is usually somewhat smaller than that through the sclerotic. Mischief commencing in the choroid very frequently extends to the retina. Any disturbance of the choroid, whether the result of accident, inflammation, or new growth is almost certain to leave marks behind it, in the shape of spots or scars with disturbance of pigment, and such occurring in the posterior half of the eyeball come within range of the ophthalmoscope, but it is necessary that the pupil should be well dilated with some mydriatic to allow of a thorough examination of the choroid, especially the peripheral parts.

THE STRUCTURE OF THE CHOROID.—The choroid is composed almost entirely of bloodvessels, and cells containing pigment; the amount of pigment varies much in different people and different ages; in children and persons of light complexion it is very scanty, more abundant in persons of dark complexion; in old age the pigment often undergoes a

sort of atrophy. The albino may be taken as the specimen with the least amount of pigment, and the negro that in which the greatest amount of pigment is present; between these every variety may be found.

The choroid may be divided into four layers:—

1. The lamina vitrea, a nearly structureless hyaline membrane.
2. The chorio-capillaris, or capillary layer, which consists of a close network, the separate vessels of which are not to be distinguished during life, together with branched spindle-shaped and flattened cells, pigmented and unpigmented.
3. The tunica vasculosa, which consists of the large blood vessels contained in a delicate stroma and having stellate pigment cells which lie between them. This layer forms the bulk of the choroid.
4. The lamina supra-choroidea, a loose connective tissue layer containing pigmented branched cells and lymph spaces.

The blood supply to the choroid is chiefly through the posterior ciliary arteries which anastomose freely with the recurrent branches of the long anterior and posterior ciliary, the blood leaves the eye in four or five main trunks which are formed by the stellate clusters of veins called the venæ vorticosæ, these venæ vorticosæ can sometimes be seen with the ophthalmoscope.

OPHTHALMOSCOPICAL APPEARANCES OF THE HEALTHY CHOROID.

—The retina being transparent offers no impediment to the examination of the choroid, which may vary much within normal limits; and it is one of the many difficulties which beset the beginner, to be able to recognise these various varieties; it is only by constant examination of a large number of eyes that one can become familiar with every variety of healthy choroid.

Ordinarily, on looking at the fundus, one gets a reflex of a uniform blood red colour, which is somewhat deeper at the yellow spot; this appearance is due to the blood in the choroid showing through the pigment epithelium, but this layer prevents one from seeing the details of the deeper part of the choroid; in fair persons and in young children the epithelial layer is of a light colour and often allows us to see the large vessels of the choroid (you will remember that the separate vessels of the chorio-capillaris are not visible). These large

vessels of the choroid are extremely tortuous, and very numerous, with small and irregular interspaces; these interspaces may contain but little pigment, and are often of lighter colour than the vessels themselves, or there may be a great deal of pigment in these interspaces, when they will present the appearance of dark islands intersected by light coloured vessels; the vessels become straighter towards the periphery, and the interspaces longer; the veins may be seen converging to form the *venæ vorticosæ*.

The veins are much more numerous than the arteries, but it is impossible to distinguish between them with the ophthalmoscope.

Among dark-skinned races, such as the natives of India, the hexagonal cells are so full of dark pigment that, when the eye is examined with the ophthalmoscope, the fundus appears of a slate colour, the rays of light being unable to reach the choroid. Frequently, however, cases are seen in which the whole of the pigment in the hexagonal cells appears to have been removed in the course of a short time. The fundus of an eye which has been of a uniform slate colour, speedily assumes quite a different aspect, being covered by an intricate network of choroidal vessels. But we have never been able to satisfy ourselves that hexagonal cells which have parted with their pigment ever regain it.

To recapitulate then, when examining a case with the ophthalmoscope it is necessary to bear in mind the following points:—(1) That the retina is transparent; (2) That the choroid consists of two chief layers; (3) That the pigment layer of the retina may prevent the details of the parts below from being seen; (a) The chorio-capillaris may be visible, but the individual vessels cannot be detected; (b) The layer of large vessels, which can frequently be seen in detail, with light or dark interspaces according to the amount of pigment contained in the stroma of this layer.

THE OPHTHALMOSCOPICAL SIGNS OF DISEASE OF THE CHOROID.

—These will vary much according to the cause from which they arise, and from the stage in which the disease is when seen.

Inflammatory and degenerative changes in the choroid may be entirely local as in myopia, or they may be symptomatic of a general disease, as syphilis or tuberculosis; and as scars result from any disease in this tissue, we need not be surprised with the frequency with which they are met with;

they are often as useful in diagnosis as cicatrices of the skin. The cases most frequently met with are not in an active condition, but present themselves in the shape of patches of atrophy, the result of previous inflammatory mischief, the chief signs of which are, spots or patches of a white or yellowish colour, which may vary according to the amount of atrophy that has taken place, from a pale red to the full white of the sclerotic. Black pigment in spots, patches or rings in or around the white patch. This pigment may come from three sources:—1. The heaping together of the normal pigment. 2. Increase of its quantity by proliferation. 3. From the colouring matter of the blood left after hæmorrhage. The amount of pigment varies much in different cases; in primary atrophy such as occurs in myopia, there is not much pigment, unless hæmorrhages have taken place; then again the situation of the pigment is of the greatest importance, for it may lie in the retina as well as in the choroid, although the mischief may have commenced in the choroid, the only way in which we can recognise that the pigment is retinal, is when it is found distinctly in front of the retinal vessels, or when it is like lace, bone corpuscles, or moss; in either of these cases it is certainly situated in the retina.

Then the extent of the choroiditis may vary considerably; thus it may affect only the epithelial and capillary layers, allowing the large vessels of the deep layer to be unusually distinct; this variety often covers a large area. Complete atrophy is shown when the sclerotic is seen in white patches or spots, often with sharp cut edges surrounded by more or less pigment; a retinal vessel may often be seen crossing such a patch.

The retina may or may not be involved over such patches, when it is implicated in these cicatrices, then its function is interfered with, and a scotoma is the result (by scotoma is meant that the retina over the involved part is blind); you cannot tell with the ophthalmoscope if such is or is not the case.

Hyperæmia of the choroid is not to be recognised.

CHOROIDITIS.—In cases of choroiditis the abnormal action commences with hyperæmia and exudation into the substance of the choroid, usually without any outward signs of inflammation. The diseased action is usually confined to a limited area, and the exudation in the first instance closely resembles that seen in cases of iritis. Greyish-yellow nodules of

exudation appear in the choroid; these extend and become organised, and converted into white patches of neoplastic tissue, surrounded by a border of black pigment. As the abnormal action extends, it generally involves the lamina vitrea, which may be perforated, and the surrounding portion of the retina becomes infiltrated with exudation from the choroid. In this way a choroido-retinitis is established, and in the course of time, pigment may appear in the retina.

In other cases the exudation is confined between the layers of the choroid, the lamina vitrea becomes glued down to the sclerotic, the intervening choroid is entirely destroyed, and white patches remain to indicate the site of the previous exudation. These are patches of choroidal atrophy.

Cases of choroiditis have been classified under several heads, but for all practical purposes, the following clinical varieties may be briefly described:—

1. Choroiditis.
2. Disseminated choroiditis.
3. Central choroiditis.
4. Myopic choroiditis.
5. Senile choroiditis.

CHOROIDITIS.—It is usually of a chronic character unaccompanied by pain or any external symptoms of inflammation, it consists of the exudation of lymph, in spots or patches into the substance of the choroid, having a whitish or slightly pinkish appearance with soft looking edges, shading off gradually into the healthy tissue; these patches gradually undergo absorption and with them the choroid, leaving a cicatrix in which the retina may or may not be involved. These spots of choroidal atrophy are exceedingly white, they are nothing else than patches of bare sclerotic, on which one can frequently see the remains of the choroidal vessels and pigment. Vitreous opacities frequently accompany this form of choroiditis. The patient usually complains only of dimness of vision, possibly also of muscæ and flashes of light. If the patches are not numerous and are confined chiefly to the periphery the prognosis will be good, though we must always bear in mind the liability to relapses. The causes of choroiditis are numerous, excessive work, especially if that work has been done in a very strong light, rheumatism, gout, and menstrual defects in women are among the number. The treatment of this form of choroiditis consists in a course

of mercury, with rest for the eyes, by means of atropine and a shade, the avoidance of strong lights, with leeching or counter-irritation to the temples.

2. **DISSEMINATED CHOROIDITIS.**—This variety is exceedingly common; it may occur in the form of small white dots which leave patches of atrophy, surrounded more or less with pigment, and having a punched-out appearance; these patches are found scattered over the periphery, or the spots may run together so as to form a patch which may cover a large area; these patches have irregular borders with more or less pigment scattered over them; usually both eyes are affected, though often unequally; frequently one eye is in advance of the other. Syphilis either inherited or acquired is the invariable cause, it may commence from one to three years after the primary disease, it may or may not involve the retina; when the superficial part of the choroid is chiefly involved, the retina is very liable to suffer, passing slowly into a condition of atrophy, the retina then becomes pigmented, its vessels small and the disc pale; this condition is commonly spoken of as syphilitic choroido-retinitis and presents exactly the appearance of retinitis pigmentosa. Choroiditis is frequently accompanied with vitreous opacities, which may be small and dust-like and somewhat difficult to see, or large, moving more or less quickly, according to the consistency of the vitreous. There is no constant difference between the acquired and inherited form of syphilitic choroiditis, but there is usually a greater amount of pigment present in the inherited form.

Treatment.—In the early stages when patches of exudation are present, complete rest for the eyes and the avoidance of strong light must be insisted on, mercury should be given and leeches or counter-irritation applied to the temples; in old cases, a long course of iodide of potassium often does more good than might be expected; this treatment should be followed up by a course of iron and strychnine.

3. **CENTRAL CHOROIDITIS.**—In this variety the inflammatory mischief is as its name implies limited to the yellow spot region; first exudation takes place, then there is proliferation of pigment with more or less disturbance; this is followed by absorption of the exudation with injury to the retinal elements. There are several varieties of central choroiditis, in some cases the changes are exceedingly fine and require great care not to overlook them, being only seen

by the direct method of examination. In addition to the ophthalmoscopic appearances, the subjective symptoms are often characteristic, patients complain that objects look distorted, sometimes they look small (micropsia); this is produced by displacement and separation of the cones, central vision quickly undergoes great impairment and frequently becomes lost, the scotoma which results varies according to the amount of retina involved.

Treatment.—Early treatment is essential if it is to be successful, and is the same as for the disseminated variety.

4. MYOPIC CHOROIDITIS.—This is exceedingly common in cases of high myopia, besides the inflammation and destruction of the choroid which frequently goes with the bulging of the sclerotic, known as “posterior staphyloma” and occurs immediately around the disc and crescent, mischief is apt to begin in independent centres, frequently in or near the macula, causing great impairment of vision. These cases require careful watching with tonic treatment and out-door country exercise; no spectacles should be allowed to correct the myopia, while active changes are taking place in the choroid.

5. SENILE CHOROIDITIS.—This variety is mostly confined to the epithelial layer of the choroid and is sometimes central; no treatment is of any avail.

ACUTE SEROUS CHOROIDITIS (GLAUCOMA FULMINANS). SEROUS CHOROIDITIS would seem to be a disease not far removed pathologically from serous cyclitis (page 206), the effusion from Collins' glands and probably from the congested veins running an acute course, and producing rapid increased intra-ocular pressure. The more rapid the effusion the greater the tension and the difficulty of the escape of lymph from the eyeball, the result being symptoms which have commonly been described as acute glaucoma. The following cases, published in 1868, illustrate the nature of the disease:—

CASE I.—K., aged thirty-five, came under treatment on the 22nd of January. Until within the last five years his eyesight had been perfect; he was then at Lahore, and was suddenly seized with a violent pain in the left eye, which became red and inflamed; he speedily lost the sight in it. The pain in the eyeball continued for some two or three months, and then gradually passed away. He came to consult us about the right eye, which had been healthy, and the

sight perfectly good, until within the last three days, when he was attacked with violent pain in it, extending over the side of the head. The patient was led into the hospital; indeed, he could only just distinguish light from darkness; the tension of the globe of the right eye was T + 2, the pupil was dilated, and the lens and vitreous were hazy, the former being pushed forward so as almost to touch the cornea, which was dull and insensible; there was considerable congestion of the vessels of the sclerotic and conjunctiva.

The veins of the retina were congested, the retina itself was oedematous, and the optic disc cupped; the retinal vessels, after passing over its edge, were evidently on a plane anterior to the one they had occupied when crossing the optic disc. The pulsation of the arteries was well marked. The hexagonal cells of the lamina vitrea were destroyed, and the vessels of the choroid could be plainly seen through the retina; and as the appearance of the pigment-cells of the stroma was almost entirely lost, we concluded that the capillaries, as well as the larger vessels, were deeply congested. Towards the ora serrata, there were numerous small patches of extravasated blood in the choroid; they did not, however, extend inwards towards the axis of vision.

Iridectomy was performed on the 22nd of January at 9 A.M., the patient was then almost blind, and in the most intense agony. At 2 P.M. he was comparatively free from pain, had slept well during the night, and was free from pain; on opening the eye he could distinguish objects. His vision continued to improve till he left the hospital, when the sight in the right eye had become as good as it had ever been; the tension of the globe was normal and the conjunctival and sclerotic congestion had entirely disappeared; the optic disc and retina were healthy.

Before proceeding to make any remarks on this case, it may be well to cite another of a similar nature, but unfavourable termination, but which conveys an important lesson when contrasted with the case above detailed.

CASE II.—I., aged forty, was admitted into the Ophthalmic Hospital on the 5th of November. He had good sight up to within four days of his admission, when he was seized with a violent pain in the right eye, and in a few hours the sight became so dim that he could only see a short distance in front of him. He came to the hospital four days after the commencement of the attack. The conjunctiva and the sclerotic

were much congested ; the tension of the eyeball was T+3 ; the pupil was dilated, and did not respond to the stimulus of light ; the lens and vitreous were too opaque to allow of the retina or optic disc being distinctly seen ; the lens was thrust forward, and it required care to avoid wounding it in making the necessary incision for iridectomy. There could be no doubt that the proper plan of treatment consisted in the performance of this operation, and the patient was therefore placed under the influence of chloroform ; but before we had completed the requisite opening in the anterior chamber he commenced vomiting, and the operation was thus delayed. As the man was constantly belching and retching the anæsthetic was discontinued, lest by these straining efforts, the congested vessels should be ruptured, and destructive hæmorrhage take place into the choroid ; and, consequently, only a small portion of the iris was excised without taking sufficient care to draw it from its attachments.

In the evening the pain in the eye had not diminished, and the eyeball still felt somewhat full, though not nearly so tense as in the morning. The patient, however, suffered from excruciating pain during the following three days ; and as the tension of the eyeball was then great, a larger portion of the iris was excised. This was effectually done, and care taken to pull it away from its attachment ; in fact, the operation of iridectomy was now performed, and not the mere removal of a portion of the iris as on the previous occasion. From this time the pain and tension of the eyeball gradually subsided ; but, unfortunately, the three days' delay between the first and second operations had been fatal to the patient's vision, extensive detachment of the retina having occurred. It is not sufficient in these cases simply to excise a portion of the iris, but the part must be removed from its attachment, in order to ensure the full benefits which the operation is capable of affording. It is a mistake to put off the operation an hour longer than is necessary, but during this time apply eserine to the eye frequently.

The question naturally arises, how can iridectomy effect such marked benefits as we see following its employment in cases of this kind ? The space included between the sclerotic and lamina vitrea is occupied by the structures of the choroid and ciliary body. If the nozzle of a fine syringe be inserted beneath the sclerotic, this sac can readily be injected to such an extent as to make the globe of the eye

very tense. In practice, we find that this may be done, and yet not a particle of the injected fluid will escape through the elastic lamina.

Suppose, for instance, we inject some of Beale's blue fluid into the choroid of a Bengalee's eye which has been recently removed, and then slice off the cornea, not a vestige of the fluid will be seen till the black hexagonal cells of the lamina vitrea have been removed, when the blue fluid will be noticed behind this lamina, extending from the ciliary body to the optic disc. If this space has been carefully and fully injected, so as to make the eyeball of stony hardness, and if a needle be then passed into the anterior chamber, in front of the iris, and its point made to press back the pillars of the iris, and puncture the ciliary body, the coloured fluid will immediately pass out into the anterior chamber; and as the needle is withdrawn from the eye, and the aqueous humour escapes, its place will be occupied by the injected fluid from the choroid.

It seems to us that, although cases of acute serous choroiditis are characterized by increased tension of the eyeball and cupping of the optic disc, nevertheless they should not be classified under the head of glaucoma. Dr. Alt remarks of cases of acute serous choroiditis, that the "accumulation of serous fluid within the eyeball, especially when its means of exit are pathologically altered, may so increase the intra-ocular pressure, that we find, later on, the symptoms of glaucoma, including cupping of the papilla." On referring to the description of the lymphatic system of the eye, we can understand the circumstances of acute serous choroiditis (Chapter XI). For if sudden effusion of serous fluid takes place between the lamina vitrea and the sclerotic, the escape of venous blood and lymph from the eye must be greatly impeded (Figs. 44, 45). At the same time, if under these circumstances a free opening is established (by means of an iridectomy) from the ciliary body into the anterior chamber, the excess of serous fluid can then drain away through Fontana's spaces and the anterior lymphatic channel.

SUPPURATIVE CHOROIDITIS is most frequently the result of a wound or a foreign body lodged within the eyeball. For instance, in India, where the operation of reclination for the relief of cataract is commonly practised, with dirty instruments by the natives, we frequently meet with instances of

suppurative choroiditis. Intense inflammation, commencing in the choroid, speedily extends to the contents of the sclerotic, and suppuration of the globe occurs. We have seen suppurative choroiditis on several occasions in patients suffering from pyæmia.

Symptoms.—In cases of suppurative choroiditis the conjunctiva is red and œdematous, the eyelids of brawny hardness and swollen. The aqueous chamber soon becomes filled with turbid fluid mixed with pus. The cornea and lens become dull, and the former infiltrated with matter; an irregular sloughing ulcer forms in it, through which the contents of the globe escape. The patient, during the suppurative stage of the disease, suffers from acute pain, generally of a throbbing character, in the eye, extending to the head and side of the face. There is often considerable constitutional disturbance, and utter inability to obtain rest, in consequence of the severity of the pain.

In by far the majority of instances of abscess of the eyeball, the cornea suppurates and the contents of the globe escape, relieving the tension and the patient's sufferings.

Treatment.—The treatment of suppurative choroiditis is most unsatisfactory (iced compresses should be constantly employed, and morphia is necessary to relieve the pain). The pain is sometimes relieved by hot belladonna fomentations. By puncturing the cornea with a broad needle, so as to allow the aqueous to escape, we may relieve the tension of the globe, and afford the patient relief. If this operation gives the patient ease, it may be repeated in the course of thirty-six hours; but if, after once tapping the anterior chamber, the pain in the eye is increased, it should not be again attempted.

Sympathetic ophthalmia need seldom be feared as a result of purulent choroiditis either in its acute stage or when atrophy of the globe has followed, so that excision of the globe is unnecessary; in such cases choroiditis is occasionally met with as the result of meningitis, the inflammatory action having extended from the covering of the brain along the sheath of the optic nerve to the choroid. If the patient recovers from the head affection he remains totally blind, the globe shrinks, and on examination we find the iris atrophied and pressed forwards to the cornea. The periphery of the iris is often retracted, and through the lens which remains clear, a white mass may be seen in the vitreous. The tension of the

globe is diminished and there is total and helpless blindness. The history of the case will generally lead us to a clear diagnosis in diseases of this description.

Tubercle of the Choroid is met with in two forms, chronic tubercular choroiditis and miliary tubercle. The chronic tubercular variety may be primary or associated with tuberculosis of the brain, the disease is somewhat insidious in character and usually affects only one eye. With the ophthalmoscope the masses of tubercle present a pale yellow or rose coloured appearance with ill-defined margins, usually situated near the optic disc. This condition might be mistaken for sarcoma, but the raised, flat, and somewhat uneven surface of the tuberculous masses, together with its general appearance should render the diagnosis easy. As the disease advances the function of the choroid becomes impaired, the vitreous gets opaque, rendering further changes in the fundus indistinct. Miliary tubercle of the choroid is much more common than the above variety, and is usually a part of a general tuberculosis; both eyes are commonly attacked, the tubercles are numerous, and vary much in size, some of the large patches being equal to the size of the disc; they are slightly prominent and have a characteristic appearance with soft looking irregular edges, they cause no pain or discomfort and at first but little impairment of vision; they sometimes only make their appearance in a very advanced stage of the general tuberculosis.

SARCOMA OF THE CHOROID, like similar abnormal growths in other parts of the body, is characterized by a preponderance of cellular elements, of a stellate, spindle-shaped, or round form, resembling those of certain embryonic tissues. These cells differ materially from those of connective tissue, in that they are incapable of passing into the stage of perfect development. They are, however, in combination with leucocytes, prone to form a relatively firm, vascular, and coherent structure. In sarcoma we find the cellular elements not only preponderating, but often containing a quantity of dark pigment, assuming the melanotic form of sarcoma.

Symptoms.—Sarcoma of the choroid commences as a slight elevation or patch in the choroid; the iris is soon seen to bulge forwards towards the cornea, the pupil is dilated, and a greyish projection may be observed through it, growing from the fundus of the eye. As the tumour advances forwards a collection of fluid takes place between it and the opaque

retina; the latter forms an undulating projection, vibrating with every movement of the eye, and clearly recognizable in the vitreous chamber by aid of the ophthalmoscope. The intra-ocular tension is increased, and the patient usually suffers from pain in the eye and over the corresponding side of the head. A sarcoma in this situation increases rapidly, but may be interrupted by periods of inactivity. As the sarcoma grows, involving more of the choroid, the lens, vitreous, and at a later period the cornea become opaque.

As the disease advances, a protrusion may appear in the ciliary region. The sclerotic is perforated, and the sarcoma grows through the opening as a dark fungating mass. Sarcoma of the choroid is apt to extend along the course of the bloodvessels backwards into the orbit; metastasis may take place, growth commencing in other organs, especially the liver.

Treatment.—In the early stages of sarcoma of the choroid, and as long as the growth is confined within the globe, we should attempt to remove the disease by excising the eye. Subsequently, when the tumour has burst through the sclerotic and involved the parts around, it is questionable if we are justified in attempting to remove it with the knife. We may diminish the patient's sufferings by means of anodynes, and the vapour of chloroform applied to the surface of the growth; but beyond attempting to relieve pain little can be done.

WOUNDS AND INJURIES OF THE CHOROID.—It is evident from the protection the choroid receives from the parts around it, that it cannot be wounded easily unless the sclerotic or other external structures of the eye are injured. In incised wounds through the sclerotic, hernia of the choroid seldom occurs, in consequence of the intimate connection which exists between these structures. Occasionally the choroid is ruptured; the rupture takes place in the posterior part of the eye; it is usually circular in shape with the concavity towards the disc; when a recent case is first seen, the rupture is generally more or less covered with blood, from the torn choroidal vessels, later the scar becomes white with some scattered pigment about its margins. The retinal vessels may be seen passing over the scar in the choroid. The extent of injury to vision in cases of this kind depends on the position and extent of the rupture. If close to the macula

it may interfere greatly with vision; but it sometimes happens that the sight after an injury of this kind improves in the course of time. When the retina gives way with the choroid the vessels are torn across, there is more hæmorrhage and the loss of sight is greater; the retina is often detached to a considerable extent in these cases.

Blows inflicted on various parts of the eye are, by no means unfrequently followed by a rupture of some of the bloodvessels of the choroid. If the effusion of blood is considerable, it bursts through the retina, and infiltrates the vitreous, probably finding its way into the anterior chamber. Cicatrices of wounds in the choroid, following contusion of the eyeball, have been noticed during life by means of the ophthalmoscope. In other cases a clot of blood may form in the choroid, and may be seen with the ophthalmoscope, the retinal vessels crossing over it. In more severe cases, the patient may completely lose the sight of the injured eye from the instant the accident has occurred, though he may suffer from little or no pain. On examining the eye we may find that the anterior chamber is full of blood; or it may happen that the hæmorrhage has not reached so far forwards, but that on dilating the pupil and examining the eye with the ophthalmoscope, we find the vitreous opaque, and infiltrated with blood. In some instances of injuries to the eye the hæmorrhage is limited, and the patient only complains of haziness of vision, depending upon a displacement of the retina forwards by a clot of blood in the choroid.

Prognosis.—This will vary according to the apparent nature of the lesions; if the hæmorrhage has been considerable, it is impossible to ascertain the extent of the damage done to the eye until the blood has become absorbed; but it rarely happens that hæmorrhage of this kind takes place within the eye without breaking down the attachments of the retina, or otherwise damaging the eye as an organ of vision. In the less severe cases, the clot of blood may be absorbed in the course of a few days, and the functions of the eye will be perfectly restored.

Hæmorrhage from the choroidal vessels is evidently more apt to follow an injury to the eye if the choroid is diseased. We meet with instances of the kind among persons suffering from myopia consequent on extensive posterior staphyloma. The imperfection of vision from which such patients suffer, renders them less able to guard themselves

from injuries to the eye than other persons ; and, at the same time, their eyeballs are often prominent. Moreover, the diseased state of the choroid renders its vessels more liable to be ruptured by a blow on the eye. We have met with several instances of this kind, where the accident has been followed by hæmorrhage into the vitreous ; and it has been subsequently discovered that extensive detachment of the retina had occurred. Even where the retina escapes, the blood in these cases oozing into the choroid, may damage its structure, and it subsequently becomes extensively atrophied ; this state of things is often followed by opacity of the lens and vitreous.

Treatment.—If the accident has only recently occurred, it is advisable to apply ice to the eye, and keep the organ at rest, so as, if possible, to stop any further hæmorrhage. But if the accident has taken place some time before we see the patient, we should keep the eye at rest with a pad and bandage until the effused blood has become absorbed. In cases of extensive hæmorrhage from the choroid the result of gun-shot, or an incised wound of the sclerotic, supposing the patient's sight is absolutely destroyed, it is advisable to remove the eyeball as soon as possible, in order to save the sound eye from an attack of sympathetic cyclitis.

We occasionally meet with cases of hæmorrhage into the choroid resulting from an engorged state of its vessels, as in glaucoma, or after over-exertion of the eye. The effused blood presents a uniform dark crimson appearance, varying in shape and size, the hæmorrhage being on a plane posterior to the retina. The retinal vessels passing over the clot can be clearly recognized with the ophthalmoscope. The extent and situation of a clot of blood will, under these circumstances, lead us to a prognosis ; small spots of hæmorrhage, if near the ora serrata, may become absorbed and leave the eye, as regards vision, comparatively uninjured, and this may be the case even with large effusions in the axis of vision, but scotomata more commonly result, and the hæmorrhage is apt to return.

DETACHMENT OF THE CHOROID from the sclerotic may occur as the result of an injury or from disease, as, for instance, the growth of a tumour in the choroid. With the ophthalmoscope we may observe the rent made in the choroid, and through it the white and glistening sclerotic can be seen. In

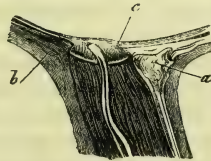
these cases the retina is detached with the choroid, and the sight of the eye is therefore irrevocably lost at the seat of injury.

In some rare cases the choroid is only partially detached from the sclerotic, by a collection of blood or serous effusion forcing its way immediately within the sclerotic, and tearing the choroid from its attachments, bulges it forward, together with the retina, into the vitreous chamber; the most characteristic symptom is the appearance of the choroidal vessels and intra-vascular spaces lying close beneath the retina. The protuberance thus formed may be seen by focal illumination, and might be mistaken for a malignant tumour springing from the choroid; but in such instances, the history of the case and the absence of other symptoms indicative of malignant disease, will lead us to a correct diagnosis.

FIG. 38.

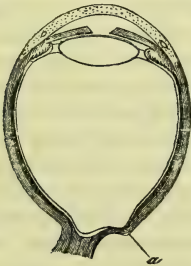

FIG. 39.



POSTERIOR STAPHYLOMA, SCLERO-CHOROIDITIS POSTERIOR.—The sheath of the optic nerve is divided into two parts (Figs. 38, 39); the outer (*b*) runs into the sclerotic, and the inner (*c*) envelops the trunk of the nerve as far as the choroid; the two are separated by loose connective tissue (*a*). In cases of posterior staphyloma the choroid becomes atrophied to a certain extent round the optic disc, and the sclerotic bulges backwards at this point. This fact is confirmed by the condition of eyeballs affected with posterior staphyloma; after removal, such eyes are found to project backwards (Fig. 38, *a*), to a greater or lesser extent, round the margin of the optic papilla, and the choroid lining this projection or staphyloma is found to be atrophied, the sclerotic itself being attenuated at this spot.

In myopes the convergence is called into play to a greater extent than in emmetropes, and the higher the myopia the greater the convergence. This, together with the stooping position myopes are so liable to take up, produces a condition of venous congestion and softening of the tissues at the back of the eye, and causes bulging of the point of least resistance, that is, the part outside the optic nerve entrance or between that and the macula. The choroid being stretched at this point undergoes consecutive atrophy, and in many instances inflammatory action is set up, producing choroido-retinitis, and complications involving the vitreous.

Cases of posterior staphyloma may be divided into two classes : the first, in which the disease is stationary, and the second, in which it is advancing.

Stationary Form.—In this form the patient suffers from myopia, which may not have been noticed until he has reached the age of twelve or fifteen years. The defective vision may first be discovered upon a boy's attempting to decipher words or figures on a blackboard at a distance of thirty or forty feet. Under these circumstances, on examining the eye, we not unfrequently find that it appears to be more prominent than natural, in consequence of its being elongated from before backwards. The patient complains of a feeling of fulness and pain in the eye after long-continued work. With the ophthalmoscope, at first sight the appearance of the optic disc is characteristic ; it is surrounded to a greater or less extent by a white crescent, which has formed usually on the outer side of the disc. The crescent may vary much in size from a small white arc to a large zone, and extends perhaps all round the disc, embracing even the region of the yellow spot, its greatest extent usually being in the latter direction. This crescent is due to thinning and atrophy of the choroid over the part affected, so that the glistening sclerotic shines through it, producing the appearance above described. Small retinal vessels can often be traced over the white background formed by the sclerotic. The outer border of the crescent is well defined, beyond which the fundus of the eye appears healthy.

Treatment.—The abnormal condition above described may remain stationary for years, and in fact for life ; but, on the other hand, active changes may at any time occur, and we should explain this fact to our patient, informing him that if the eye begins to trouble him, if he gets an aching pain

over the brow after exerting it, or if the glare of the sun is felt to be particularly dazzling and uncomfortable, the sight becoming somewhat hazy — that these symptoms indicate advancing mischief, and should be at once attended to. Supposing, however, no such complications occur, we may content ourselves with ordering the patient a pair of concave glasses to correct his myopia, and that in reading and writing he has the advantage of a good light, and is not allowed to stoop over the object he is working at.

Progressive Form.—The symptoms which characterize progressive posterior staphyloma are as follows:—A patient affected with myopia complains of a gradual but increasing impairment of vision with aching pain in the orbits, extending to the temple, and more or less intolerance of light; the glare of the sun is trying, and induces an uncomfortable aching feeling in the eye, and photophobia. He may have suffered from repeated attacks of this kind, lasting for a month or six weeks, and then passing off, reappearing, however after unusual exertion of the eyes, or derangement of the general health. Each attack causes the sight to become more impaired, the myopia increasing rapidly.

If an eye affected with this disease be examined with the ophthalmoscope in its early stages, by the direct method, the fundus may appear healthy, with the exception of a portion surrounding more or less of the disc, where, usually on the outer side, a patch of choroiditis will be observed (see Plate I in Chapter XXIII on Myopia). The alteration in the colour of this patch will be most marked near the disc; from thence, passing outwards, a number of white spots are often noticed in the choroid; these gradually coalesce into a white crescent, with deposits of black pigment over its external margin. In fact, in progressive posterior staphyloma, owing to the choroiditis going on in the part, the line of demarcation between the diseased and sound tissue is indistinct, and inflammation is apt to extend until a considerable portion of the choroid is destroyed. As degeneration of the choroid advances the sclerotic loses its power of resisting the intra-ocular pressure, and a large posterior staphyloma may result. This, however, is by no means the only ill-effect likely to follow progressive posterior staphyloma; opacity and fluidity of the vitreous, and detachment of the retina are unfortunately too frequently the direct result of this form of disease. The former affection will be recognized at once; on examining

the eye with the ophthalmoscope, a number of black, flocculent-looking shreds will be noticed floating in the vitreous, and will be best observed by the direct method of examination; they are to be seen whisking about in all directions upon the slightest movement of the eye, causing the patient the greatest annoyance. The state of the choroid may often be observed through the fluid vitreous even at this stage of the disease, and the history of the case indicates the nature of the affection; we should also examine the other eye, and the chances are that a posterior staphyloma will be detected in it; and thus we may be able to form a safe conjecture as to the cause of the fluid vitreous in the diseased eye. During the progress of this affection, detachment of the retina is likely to take place; for, as the staphyloma projects backwards, one of two things must occur: either the retina will be stretched and torn across in following the sinuosities of the choroid; or else, bulging backwards into the staphyloma, it will be dragged away from its attachments, either at the optic papilla or else outwards. If the dioptric media are sufficiently transparent, we may watch these changes with the ophthalmoscope; frequently, however, the vitreous becomes so hazy that the retina cannot be seen, though we may be pretty well assured of its disorganized condition by the almost complete loss of vision from which the patient suffers. And lastly, secondary glaucoma may supervene at any stage of the disease. In neglected cases both eyes are sooner or later affected in this way.

Treatment.—It is necessary that we should do all in our power to stop the progress of the staphyloma in its early stages. If, therefore, we meet with a case presenting features such as we have described, and learn that there has been any recent aggravation of the symptoms, we should make careful inquiries regarding the patient's employment, habits, and general state of health, with a view to correcting whatever may be wrong. Overwork is almost always the exciting cause of these changes; under any circumstances we must enforce absolute rest of the eye while symptoms of choroiditis are present. The cold douche may often be used with advantage, morning and evening. In addition to these general measures, if active changes are going on in the eye, apply two leeches to the temple for three consecutive nights, fomenting the part well afterwards. The patient should be

kept in a dark room until symptoms of pain and intolerance of light have passed away; he may then be permitted to take exercise in the open air, wearing a pair of neutral tint or peacock blue glasses when exposed to the glare of the sun, or lamp-light; but he must not be allowed to resume his work until the choroiditis has disappeared. Small doses of bichloride of mercury, continued for some time, are sometimes useful in these cases.

In many instances, however, attention to the state of the general health, together with the cold douche and rest, will be the chief curative means at our disposal. By a judicious plan of treatment of this kind, the symptoms indicating active changes in the choroid will gradually subside, and the patient may then be allowed to use his eyes, though he cannot be too careful not to overwork them. If these precautions are strictly observed, we may with confidence hope to preserve our patient's sight; taking care, whenever the uneasiness or pain in the eyes returns, to have recourse to a system similar to that above described, so as to prevent the destructive changes from making further progress. But we need hardly remark, that when degenerative changes have taken place in the choroid, retina, or vitreous, our prognosis must be guarded; we can only expect to preserve the amount of vision that exists, and not to restore that which is lost.

Lastly, it is above all things necessary to supply the patient with proper concave glasses, so as to correct his myopia, and thus prevent the increased convergence of the eyes which it renders necessary. (See Chapter XXIII on Myopia.)

COLOBOMA OF THE CHOROID is a congenital defect due to arrested development, it is frequently, though not always, associated with coloboma of the iris, and may occur in one or both eyes. The coloboma is always downwards, extending usually from the optic disc forwards to the ciliary bodies.

The retina is either absent or imperfectly developed over the coloboma, so that a large scotoma is the result.

With the ophthalmoscope a large, white, sharply-defined patch can be seen, which is of course the bare sclerotic, over this the retinal vessels may pass, and sometimes a considerable bulging of the sclerotic is present corresponding to the defect.

OSSIFICATION OF THE CHOROID occasionally takes place in

blind shrinking eyes, and is probably due to ossification of the exudation which has taken place between the layers of the choroid, sometimes a complete cast of the posterior part of the eye is formed, perforated with an opening for the optic nerve. It is safest to remove such eyes, as they may at any time produce inflammatory mischief which may set up sympathetic trouble in the other eye.

Colloid Diseases of the Lamina Vitrea.—It may be that, on examining eyes which have been subject to frequent attacks of inflammation, small yellowish prominences are noticed on the inner surface of the lamina vitrea. These minute excrescences resemble those seen in the membranes of the brain, and, like them, they undergo calcification, so that they effervesce on the application of a strong acid, and when cut, the edge of the knife grates against them. These colloid bodies are most abundant near the equatorial region of the eye, but always at some distance from the papilla; they are at times detached from the lamina vitrea, and become imbedded in the retina. In cases of colloid degeneration of the lamina vitrea the fundus of the eye appears to be sprinkled over with minute dots, either with, or independently of evidence of choroiditis.

CHAPTER IX.

DISEASES OF THE VITREOUS.

Anatomy—Hyalitis—Muscæ—Opacities—Sparkling Synchysis—Hæmorrhage—Entozoa—Foreign Bodies—Pseudo-Glioma—New Vessels.

The Vitreous Humour.—The vitreous is not a secreted fluid like the aqueous, but an embryonic product of mesoblastic tissue, which enters the hyaloid cavity through the choroidal fissure at a very early stage of foetal life. It can therefore never be restored. When a portion escapes from the eye its place is filled by serum, which, fortunately, having a similar refractive index may not cause any sensible loss of vision.

The anterior surface presents a cup-shaped cavity, the patellar fossa, in which lies the lens in its capsule. The vitreous is enclosed in a capsule, the hyaloid membrane. The capsule is closely applied to the membrana limitans interna of the retina throughout its whole extent from the optic nerve to the ora serrata. From this point it loses its hyaline character, and becomes thicker and fibrillated. It does not cover the patellar fossa of the vitreous, but passes forwards from the apices of the ciliary processes to the anterior part of the margin of the lens, thus forming the anterior wall of the lymphatic canal known as the canal of Petit; Iwanoff, Schwalbe, Robin, Henle, &c., deny the existence of the hyaloid altogether, and maintain that the vitreous is in immediate contact with the membrana limitans interna of the retina. This latter portion of the hyaloid membrane is known as the *suspensory ligament of the lens*, or *Zonula of Zinn*. It is by far the strongest and thickest portion of the hyaloid, and its hyaline matrix is strengthened by bundles of thin, stiff elastic fibres. It is now admitted by the best

authorities that the triangular space encircling the margin of the lens, and known as the canal of Petit, has no posterior lining membrane, the vitreous extending right up to the suspensory ligament, at least only leaving room for a microscopic lymph space between; and that the triangular canal is really due to the shrinking, and consequent recession of the vitreous after death. The surface of the vitreous becoming condensed at this part, has led to the further mistaken idea of a posterior lining membrane to the cavity.

The vitreous very closely resembles fresh white of egg, both in appearance and consistence, and tends to get slightly more fluid as age advances: its index of refraction is 1.337, the same as that of the aqueous. If a small circular wound be made in the sclerotic of a healthy eye the vitreous will not pour out, but will protrude as a small glistening button of sufficient consistence to be snipped off with a pair of scissors. Minute lymph clefts, arranged in a concentric manner towards the periphery, and in a radiating manner towards the centre, can readily be made out by staining the surface of the vitreous with a colouring fluid in a fresh eye divided through the centre. Round, fusiform, and stellate cells, with long branched processes, also exist throughout the vitreous, especially towards its surface. They undergo amoeboid movements. A minute canal—the canal of Stilling—lined by a thin involution of the hyaloid membrane, extends from the optic papilla to the back of the lens capsule; this canal served during foetal life to convey the hyaloid artery, which passes forward from the optic disc, to the posterior surface of the lens, where it breaks up into a plexus to supply nourishment to the lens; this vessel should begin to disappear between the fifth and sixth month of intra-uterine life, leaving a transparent central canal, which is probably an important lymph channel; occasionally some remains of the vessel may be left which can be seen with the ophthalmoscope as a cord stretching from the centre of the optic disc to the back of the lens.

The vitreous contains no bloodvessels or nerves and derives its nutrition chiefly from the ciliary processes. Two lymph currents exist, an anterior one passing through the circumlental space into the aqueous, thence into the canal of Schlemm, and the surrounding spaces of Fontana; and a posterior one surrounding the optic nerve.

HYALITIS, OR INFLAMMATION OF THE VITREOUS, may be induced by the presence of a foreign body purposely passed through the vitreous chamber. In instances of this kind, Donders describes changes occurring around the foreign substance, similar to those noticed in other parts of the body during inflammation. These pathological alterations may occasionally be traced when a foreign body, such as a piece of gun-cap, has accidentally passed into the vitreous. From proliferation of its cells, and those of surrounding structures, the vitreous becomes hazy, the foreign body being enveloped in a greyish layer of opaque material, and branching out from this centre of irritation opaque streaks may be observed. Subsequently, the connective tissue breaks down, and the vitreous having become fluid, thread-like fibres may be seen floating about in it. These instances, however, must be rare, for in the majority of cases the choroid and retina become involved, and it is then impossible to determine how far the changes observed in the vitreous are due to extraneous sources.

Pus doubtless collects at times in the inferior part of the vitreous chamber, especially after the operation of reclinacion of the lens, forming what is called a posterior hypopyon; but we are not disposed to admit the existence of such a disease as idiopathic suppurative hyalitis; in fact, with Dr. H. Pagenstecher, we doubt the correctness of those who describe inflammatory changes under these circumstances. Doubtless we meet with instances in which the vitreous becomes clouded, rendering the details of the fundus of the eye indistinct, or it may be invisible: but these conditions without question are due to inflammatory products poured forth from one of the contiguous structures.

MUSCÆ VOLITANTES.—*Muscæ volitantes* to the patient appear as dark bodies, under various forms, floating about in the field of vision; they are often very annoying, but, unlike scotoma, they do not interfere with the perfection of vision. The patient sees them as slender rings, which appear to ascend from the lower part of the field of vision and then to fall down again. In other cases they take the form of pearly strings, which twist and twine about in all directions, or they may be seen as fine bands hovering about in the visual field. They are most distinctly noticed when the patient looks at some clear bright object, as, for instance, at the sky or a white

wall; in a dim light they are probably not visible. After overworking the eye the dark bodies are very troublesome, particularly if the digestive organs are out of order.

These various appearances are due to the presence of minute pale cells, or of granular shreds in the vitreous humour, the shadows which these cast on the retina are the direct cause of the *muscæ volitantes* noticed by the patient in the field of vision. In some few instances it appears that opaque globular spots, situated among the fibres of the lens, may, by intercepting the rays of light falling on the retina, produce the appearance of *muscæ volitantes*.

Muscæ, therefore, are by no means a symptom of any great consequence, and are often observed in persons whose eyes are otherwise healthy. The cells and filaments of *muscæ volitantes* are transparent and not to be seen with the ophthalmoscope, and are thus distinguished from opaque membranes floating about in a fluid vitreous, which may be detected without any difficulty with the ophthalmoscope, and which are invariably pathological products. Short-sighted persons are very apt to suffer from *muscæ*, in consequence of the increased circles of diffusion cast by the minute bodies on the retina; we may comfort such patients with the assurance that the *muscæ* are not a symptom of serious disease.

Treatment.—It will often be found that *muscæ* depend on gastric derangement, or at any rate occur when the stomach or liver is out of order; and attention bestowed on these organs will do much towards removing the *muscæ*. In other cases, rest and a tonic plan of treatment are of service. *Muscæ* sometimes remain stationary for years, and then disappear of themselves. Tinted glasses are sometimes useful to patients suffering from this affection.

Opacities of the Vitreous may be detected with the ophthalmoscope, they vary considerably in shape, size, number, and position, they may be fixed or floating; in some cases they are so exceedingly fine, that they may easily escape detection, and produce only a slight blurring of the details of the optic disc, somewhat resembling the commencement of papillitis, for which it may easily be mistaken; these fine opacities can best be seen by using a plane mirror in the ophthalmoscope with a + 8, D, behind the sight hole, and employing only a feeble illumination; in other cases the opacities may be both large and numerous, preventing any part of the fundus from being seen between these two types of the disease, every variety

may be met with ; sometimes the opacities are membranous, more or less fixed at points ; sometimes they are in the shape of shreds moving rapidly on any movement of the eyeball, or somewhat like the wings of insects ; when the opacities are floating the rapidity with which they move may be taken as an index of the consistency of the vitreous. These opacities may be either ; (1) inflammatory products from one of the surrounding vascular tissues ; (2) blood, from rupture of one of the vessels of the retina, choroid, or ciliary processes ; (3) or coagulation of some of the elements of the vitreous.

The most common cause is acquired or inherited syphilis, when the opacities are probably secondary to mischief going on in the choroid, they are then frequently very small and numerous (dust-like). Excluding this class of cases, and hæmorrhage the result of a blow, opacity of the vitreous is most commonly seen among patients suffering from progressive myopia.

If depending on inherited syphilis, the changes in the vitreous usually take place slowly, and the structure may at any time gradually clear and become transparent ; on the other hand, if the degenerative process continues, it may lose its consistency, and pass into a fluid state. Flocculent masses will then be seen floating about in it ; while, from the loss of the support which, under ordinary circumstances, the vitreous affords the retinal vessels, these may give way, and the effused blood passing into the vitreous adds to the floating bodies which it contains. The disease is accompanied with no pain in the eye, and the patient complains of no inconvenience beyond the gradually increasing loss of sight, which is most marked after sunset. We should be guarded in our prognosis ; it is more than probable that in such cases, when the vitreous clears, we shall discover further mischief to have taken place behind it, in the retina or choroid.

When the opacities are membranous, they may stretch across the vitreous like a thin veil, completely obscuring every part of the fundus, new vessels may sometimes be traced on to them. The position of this membrane may be estimated with the ophthalmoscope by finding the strongest convex glass through which its details may be clearly seen, remembering that for every 3 dioptries we have a difference of 1 mm., the amount of parallax obtained on moving the ophthalmoscope may also give us an indication of the position of the membrane. This condition has sometimes been mis-

taken for detached retina. Professor Von Graefe has operated on cases of this kind by passing two needles into the vitreous and tearing the membrane across in the same way as one treats opaque capsule after cataract operations; usually the condition of the vitreous renders such an operation, however skilfully performed, of little value.

Treatment.—Where the opacities are large and move quickly, showing degeneration and fluidity of the vitreous, no treatment is usually of much avail; in recent cases where the opacities are fine, a course of mercury and iodide of potassium, especially when there is other evidence of syphilis, may do great good. Subcutaneous injections of pilocarpine have also proved useful, the patient should have one injection a day, commencing with the $\frac{1}{6}$ of a grain and gradually increasing the dose to $\frac{1}{2}$; it is necessary to continue this treatment for at least four weeks; the injection should be given between meals, the patient should be in bed and remain there till the profuse diaphoresis has passed off; it will be understood how few patients can spare the time to undergo this treatment. Cases are sometimes met with in young women with some disturbance of the uterine functions; here the treatment must be directed to this organ.

SPARKLING SYNCHYSIS.—A remarkable condition of the vitreous, called sparkling synchysis, is occasionally seen, depending upon the presence of innumerable particles of cholesterine and tyrosin floating about in it. With the ophthalmoscope, they appear like a multitude of grains of gold-leaf, whisking about in all directions when the eye is turned quickly from one side to the other.

This condition generally arises from degenerative changes taking place in the vitreous, occasionally also from degeneration of a dislocated lens; a great part of the lenticular matter becoming absorbed, the insoluble cholesterine is left in the vitreous chamber. Among the natives of India these appearances are sometimes seen, in consequence of the lens having been thrust down into the vitreous, in the operation of depression or reclination for the cure of cataract. We not unfrequently have patients applying for relief at the Ophthalmic Hospital under these circumstances, suffering from atrophy of the retina and choroid, together with sparkling synchysis.

HÆMORRHAGE INTO THE VITREOUS.—It is by no means

uncommon to meet with cases in which an effusion of blood into the vitreous has taken place, in consequence of a blow, or from rupture of diseased vessels of one of the ciliary processes, the choroid, or retina. For instance, a person is struck on the eye, and he finds that he cannot see clearly, the field of vision being obscured by a reddish haze. With the ophthalmoscope no fundus reflex may be obtained, or the vitreous appears of a diffused, bright scarlet colour, the optic disc being dimly seen through it; spots of ecchymosis will probably also be observed in the retina.

If the effused blood is small in quantity it may be rapidly absorbed, and the vitreous return to its normal state of transparency; but if the hæmorrhage has been at all profuse, a clot may form in the axis of vision, rendering the patient more or less blind. The fibrine of a clot of this kind usually undergoes fatty degeneration, and gradually becomes absorbed; but hæmorrhage into the vitreous may lead to opacity and further degeneration, and consequent fluidity of that structure; on this account we should be guarded in giving a favourable prognosis in such a case; moreover, the clot may remain *in situ*; and should it even disappear, we may subsequently discover that considerable injury has been done to the retina, and that its functions have become permanently impaired.

There can seldom be any difficulty in forming a correct opinion with respect to the nature of a lesion of this kind; for if the hæmorrhage has occurred in consequence of an injury, the impairment of vision will have originated at the time the blow was inflicted; but if from the effects of disease, the history and symptoms, together with the ophthalmoscopic appearances of the part, will sufficiently determine the diagnosis. It is possible that a malignant growth in its earliest stages, or a separation of the retina from the choroid, might be mistaken for a clot of blood in the vitreous chamber; a little care, however, bestowed on the inspection of the part, will speedily remove any doubt there may have been on the subject. If the case should be one of malignant tumour, the aspect of the excrescence can hardly be mistaken, the pain and tension of the eyeball, combined with the ophthalmoscopic appearances indicating the serious nature of the mischief going on in the eye. By means of the focal method of illumination, the tumour may generally be defined as soon as it projects slightly beyond the plane of the fundus of the eye.

ENTOZOA IN THE VITREOUS.—Cysticerci are occasionally found in the vitreous chamber, the cyst in which they grow being attached to the retina or choroid. Dr. Liebreich states that the entozoon is first developed behind the retina, and having perforated it, enters the vitreous chamber. A contracting and elongating movement of the cyst may be clearly observed, though the parasite itself cannot be distinctly seen, on account of the opaque sheath in which it is contained. After a time the cyst bursts, and the head and neck of the creature may then be defined. It is, however, remarkable that, up to this stage of the disease, the parasite appears to cause no inconvenience beyond the shadow cast by the wavy motion of the cyst in front of the patient's retina; there is no pain or irritation in the eye. Dr. Liebreich relates a case of a cysticercus in the vitreous, which he not only diagnosed, but removed: passing a pair of canula forceps into the vitreous, he seized the parasite and withdrew it from the eye. During the operation he contrived to illuminate the vitreous with an ophthalmoscope which he fixed to his forehead, enabling him to use both his hands, and thus accomplish the necessary manipulation. Cases of a similar kind have from time to time been recorded; in some the lens was first extracted, and subsequently the parasite removed; these operations, however, have not been very successful.

These cases are much more frequently met with in Germany than in this country.

FOREIGN BODIES.—The entrance of a foreign body into the eye is one of the most serious accidents that can happen to this organ; vision may be at once destroyed, or inflammation of a destructive character may be set up ultimately leading to loss of vision; further than this the sight of the second eye may be eventually compromised by sympathetic mischief excited by the injured eye. Occasionally the foreign body may become covered with lymph and remain quiet for years, the eye retaining perfect vision; such a result is, however, of very rare occurrence and cannot be relied upon.

All sorts of bodies have been driven into the eyeball, fragments of needles, chips of metal, pieces of percussion caps, shots, particles of glass, or stone, splinters of wood, &c., sometimes the penetrating body passes through the vitreous and becomes fixed in the sclerotic, occasionally it passes through the sclerotic and lodges in the orbit, leaving an injured tract through the eyeball. The body most frequently

passes through the cornea and lens, damaging these tissues, and possibly also injuring the iris and ciliary bodies; in about one case in five the perforation takes place behind the ciliary region, then one of the lids may or may not have been injured. When the foreign body is small, the sclerotic perforation may be difficult to find, then the ophthalmoscope will be of the greatest assistance in enabling us to detect and estimate correctly the position of the perforating particle in the vitreous, especially if the case be seen early before any effusion has taken place around it.

Occasionally the foreign body carries with it into the vitreous a bubble or two of air, which the observer might easily mistake for the body itself unless aware of this possibility; air bubbles are round, reflect light from their centres and have dark margins, whereas the reflex from a chip of metal is chiefly from its margins; the foreign body may be more or less surrounded with blood. When nothing can be detected with the ophthalmoscope, and yet the evidence seems to point to the presence of a foreign body, something may be gained by noticing if any particular part is very sensitive to the touch; and in the case of a chip of iron or steel, an electro-magnet applied outside the eyeball may attract the particle of metal and so produce a sharp pain; or if the electro-magnet be held over the closed lids for a short time so as to magnetise any possible piece of metal within the eye, then a sensitive magnetic needle suspended over the eyeball, may give an indication of such presence by causing it to deflect.

Perhaps the most common accidents used to be from the old percussion gun cap, which was very liable to splinter; since the invention of the hammerless gun such accidents are almost unknown.

It is impossible to lay down special rules in treating accidents of this kind, so much depends upon the track of the perforating body and the injury it has inflicted on its way; in many cases nothing can be done but eviscerate, or remove the injured eye. In less serious cases, especially when the foreign body is a chip of iron or steel, the electro-magnet may help us to extract it. The one introduced by Mr. Snell is small, strong, and convenient; it consists essentially of a cylinder of pure soft iron around which is wound a coil of copper wire; one end of the magnet is connected with a galvanic cell, while the other end is fitted up with a

suitable point or blunt needle; this needle may be made in various sizes and shapes to suit different cases; the attracting power of this magnet is very great and is capable of lifting many ounces, though the length and size of the terminal used will make considerable difference in its lifting power, the longer and finer it is, the less attractive power will it possess.

When, however, the foreign body is supposed to be steel or iron, and can be seen either by focal illumination or by means of the ophthalmoscope, the needle of the electromagnet may be passed through the perforation in the sclerotic or cornea in the direction of the piece of metal; this may suddenly be attracted to it with a perceptible click; the needle must be most carefully withdrawn, so that the object of our search may not be rubbed off the magnet by the edges of the wound; if necessary the original wound may be enlarged or a fresh incision made. When the piece of metal cannot be seen, then the vitreous must be very carefully explored with the terminal of the magnet, in the hope that it may come sufficiently near the offending particle to attract it.

Almost every instance we meet will require some peculiar manipulation, and we must exercise our own judgment, ingenuity, and mechanical skill in contriving the most appropriate means for accomplishing our purpose. With the ophthalmoscope, a foreign body may usually be defined, if sought for soon after it has penetrated the vitreous chamber; but after remaining there for some time, it is likely to become hidden by a covering of false membrane.

In India, we constantly meet with instances of a foreign body in the vitreous in the shape of a dislocated lens, for the uneducated native practitioners usually operate for the cure of cataract by reclination. Suppose a patient is brought to us in great agony, with his eye violently inflamed from a recently performed operation for depression. On examination, we see the opaque lens bobbing about behind the iris, and it is necessary to decide at once as to the treatment to be pursued under the circumstances. If the lens has been depressed within a week or so, and the patient has still some perception of light, we should attempt to save the eye, removing the lens by linear extraction. We may experience some difficulty in accomplishing this, on account of the adhesions which will probably have formed between the iris and the lens. If the dislocation has existed for more than

fourteen days, and the patient is suffering from considerable pain in the eye, and has lost all perception of light, it is better to excise the eyeball at once; any palliative treatment we may adopt must expose the patient to the risk of losing the other eye from sympathetic irritation; and there is no chance of the diseased one being in future anything but a source of annoyance and pain, so that the sooner it is removed the better.

Pseudo-Glioma is a term applied to a condition in which the vitreous has become solid and opaque, probably the result of exudation from the choroid; this condition has frequently been mistaken for glioma of the retina, hence the name. Cases met with are usually in young children, who have just recovered from meningitis, the inflammation having probably extended directly to the eye along the sheath of the optic nerve; one or both eyes may be affected, the disease leading to shrinking of the globe, but never to suppuration; when one eye only is affected, there is no fear of sympathetic inflammation attacking the other. All sight is lost in the eye attacked, the vitreous becomes converted into a solid, whitish, opaque mass, pressing the lens and iris forward in the centre, while at the periphery retraction takes place; the iris looks muddy and posterior synechiæ may be present, as shrinking goes on, the intra-ocular tension becomes diminished. In glioma of the retina the tension except in the very early stage is increased, the iris retains its normal lustre, and is with the lens pushed forward including its ciliary border, frequently vessels can be traced on to the growth. In cases where there is any doubt, it is safer to remove the eyeball.

New Bloodvessels are very occasionally to be seen in the vitreous; they are no doubt developed as a result of previous inflammation.

CHAPTER X.

DISEASES OF THE OPTIC NERVE.

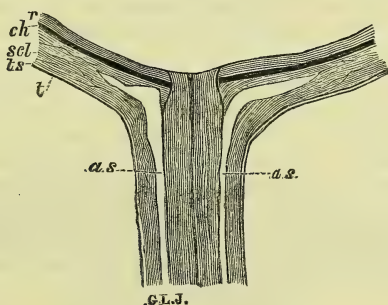
Anatomy—Hypercæmia of the Optic Disc—Optic Neuritis—Syphilitic—Malarial Rheumatic Papillitis—Neuritis the result of Lead Poisoning—Suppression of Menses—Edema of the Optic Disc—Atrophy of the Disc.

ANATOMY.—The optic nerve is invested by three sheaths, which are respectively prolongations of the dura mater, arachnoid and pia mater. The external, or dural, is a firm, tough sheath identical in structure with the dura mater, it joins the nerve at the optic foramen and passes forward into the sclerotic; its inner surface is lined by a layer of endothelial cells, numerous blood vessels and nerves. The middle, or arachnoidal sheath, consists merely of a network of fine connective tissue fibres, in the meshes of which are endothelial cells. The internal, or pial sheath, is a continuation of the pia mater, which follows the nerve from the chiasma to the lamina cribrosa which it helps to form. Its outer part contributes the sub-arachnoid (inter-vaginal) trabeculæ, which fill the inter-vaginal space. From its inner part a strong trabecular framework of fibro-cellular tissue is derived, which forms a dense network throughout the optic nerve, ensheathing and supporting the nerve-bundles and giving off thin septa of connective tissue which surround each individual fibre. This framework also carries the bloodvessels and capillaries which supply the nerve. Surrounding the external dural sheath of the nerve we have the supra-vaginal.

Between the external and middle sheaths is a lymph-space, which opens into the arachnoid cavity of the brain, but does not communicate either with the peri-choroidal space or the sub-arachnoid cavity of the nerve, it ceases just behind the

commencement of the choroid. Between the middle and internal "pial" sheath is a constant, well-defined space—the sub-arachnoid or inter-vaginal space (Fig. 40). This space is permeated by trabeculæ of connective tissue; it is continuous with the sub-arachnoid and sub-dural spaces round the brain and covered with an endothelial membrane. Near the insertion of the nerve into the globe the space dilates into an ampulla, which extends a short distance under the choroid in a conical form, separated only from the latter by the pial sheath, and terminates more or less abruptly. At the level of the lamina cribrosa it anastomoses with the lymph-spaces between the pial sheath and the nerve-bundles by means of

FIG. 40.



Diagrammatic Sketch of the sub-arachnoid space and sheaths of the Optic Nerve. The trabeculæ and arachnoid sheath are omitted. *r*, retina; *ch*, choroid; *scl*, sclerotic; *sa*, sub-arachnoid.

lymph-canalicular clefts in the pial sheath, and at its termination under the choroid it communicates with the perichoroidal lymph-space above described. Finally, beneath the pial-sheath a lymph-space exists, which is continuous with lymph-channels running through the trabecular framework of the optic nerve, and between the individual fibres. This space does not communicate with the sub-arachnoid space of the nerve.

The optic nerve is pierced, near, or just at its axis, by a small amount of delicate loose connective tissue, in which the central retinal artery and vein are embedded; these connective tissue elements pass with the vessels into the

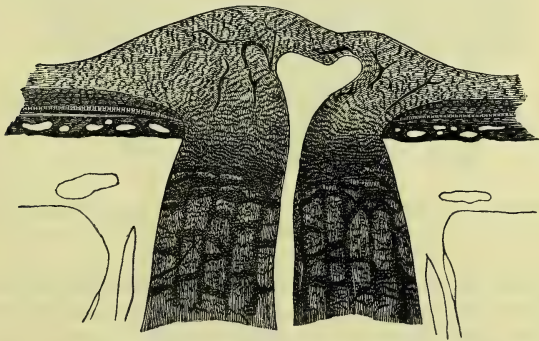
eye, the latter being distributed to the inner-fibre layer of the retina. The bloodvessels of the optic nerve are derived from those contained in its internal sheath, which is continuous with the pia mater of the brain, and also by returning branches of the short ciliary arteries; the nerve also receives vessels from the central artery. At the lamina cribrosa the capillaries derived from these sources are augmented by vessels from the choroid.

The colour of the optic disc or papilla as seen with the ophthalmoscope, is due to the reflection of light from the glistening fibrous structure of the lamina cribrosa, and the capillary network of vessels distributed to the transparent nerve tissue. We have previously described the appearances presented by the healthy papilla (page 20), and it is obvious that either a diminution, or distention of the capillaries of the papilla with blood, must cause a deviation from the natural colour of the optic disc. At the same time the colour of the papilla is liable to considerable variations consistent with perfect health, being influenced by any conditions which alter the capillary circulation through the vessels contained in the papilla. The tint of the disc is deepest where the nerve fibres are most numerous, that is on its inner half. The side of the central physiological depression, when it exists, is steep on the nasal and shallow on the temporal side, in consequence of the inequality of the distribution of the nerve fibres.

HYPERÆMIA OF THE OPTIC PAPILLA is characterized by the papilla assuming a bright scarlet colour and velvety appearance, together with a slight amount of effusion, so that its outline is somewhat obscured, especially its choroidal border; the retinal vessels are usually unchanged. The colour of the healthy papilla varies, however, in different individuals, and even in the same person under various circumstances; the bright light thrown into the eye by the ophthalmoscope is probably sufficient to excite increased vascularity. It follows, therefore, that it requires considerable experience to enable us to determine if hyperæmia is present or otherwise. However, there can hardly be a mistake in those cases in which the disc is of a persistent bright rose colour, with a softened or cloudy edge, a condition not unfrequently met with among patients who strain their eyes to overcome some error of refraction from which they

are suffering. In such cases the acuteness of vision may be perfect; but in the majority of patients suffering from persistent hyperæmia and consequently some serous effusion into the papilla, there is dimness of sight, headache after work, and pain in the back of the eye. A condition of marked hyperæmia, and occasionally of serous effusion into the papilla, is also occasionally met with among girls suffering from menstrual troubles; or it may depend upon disorders of the alimentary canal. In some instances the irritation caused by decayed teeth in the upper jaw has led to persistent congestion of the papilla. Whether from errors of refraction or whatever the cause of the hyperæmia, it must be rectified, if possible, and the affected eye kept at rest for a time. Persistent hyperæmia borders so closely upon papillitis that the line of demarcation between the two conditions is slight and demands careful attention.

FIG. 41.

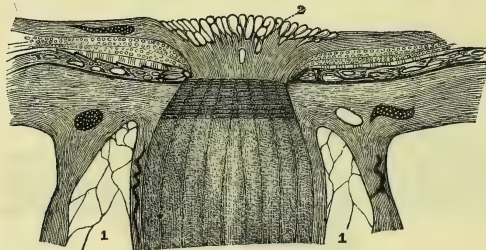


OPTIC NEURITIS (PAPILLITIS).—Considering the intimate relations that exist between the brain and the optic papilla, we shall be prepared to accept the statement that seventy-five per cent. of cases of bilateral neuritis are the result of intracranial disease. On the other hand, the nerve-elements of the papilla and its connective fibres being prolonged into the retina, it follows that optic neuritis can hardly exist for any length of time, without compromising the integrity of the retina, and so causing a neuro-retinitis.

Pathologically optic neuritis may be divided into three classes:—(1) Interstitial; (2) Fibrinous and Purulent; (3) Medullary. But as it is doubtful if inflammation ever commences in, or is confined to, the purely nerve elements, we shall not attempt to describe “medullary optic neuritis.”

Interstitial Optic Neuritis is the most frequent form of inflammation affecting the optic nerve. It is essentially a disease of the neuroglia and interstitial connective tissue of the nerve; the connective tissue trabeculæ separating the bundles of the nerve, and which are derived from its inner or pial sheath, are found crowded with lymphoid cells. The optic papilla is much swollen, and contains numerous newly-formed blood-vessels, and frequently small hæmorrhages (Fig. 41). The vessels of the optic nerve are surrounded

FIG. 42.



1, 1. Inter-vaginal space of nerve. 2. Spaces in optic papilla filled with serum.

by layers of round cells; but the nerve-fibres are only slightly affected, unless in the advanced stages of the disease, when they undergo fatty degeneration. As the new cell-elements become developed the trabeculæ increase in thickness, and at the same time the vessels are compressed, and ultimately dwindle away to fibrous cords. It often happens that first one part of the nerve, and then another is affected in this way. Changes in the elements of the papilla occur precisely similar to those in the nerve. The retina becomes thin, and in the later stages of the disease perivasculitis and interstitial retinitis are observed.

Fibrinous and Purulent Neuritis as a rule depend on an extension of similar forms of inflammation from one or other of the

meninges of the brain. There is congestion of the vessels contained in the sheath of the optic nerve. The inter-vaginal spaces or sheath of the nerve is distended with serous fluid (Fig. 42). Rapid proliferation of the endothelial cells takes place, and the lymph spaces soon become occupied by connective tissue, so that the inter-vaginal spaces are obliterated. During these changes the optic papilla is intensely congested, hæmorrhages are frequently found among its elements; its connective tissue becomes hypertrophied and the nerve elements disappear.

The purulent form of neuritis is comparatively rare, and is caused by suppurative meningitis or by inflammation of the contents of the orbit extending to the optic nerve.

The results of the various forms of optic neuritis, in addition to the dangers already referred to, are atrophy of the papilla and alterations in the retina. So that in some specimens we find the elements forming the papilla have entirely been removed, and the optic disc consists of the hypertrophied trabeculæ of the lamina cribrosa; the vessels of the disc and retina have almost disappeared, and atrophy of the nerve-fibre layers of the retina is marked. The vitreous body in proximity to an inflamed papilla often becomes infiltrated with round cells, subsequently nodules of connective tissue form, and project into the vitreous chamber. New tissue thus produced occasionally fills in the excavation otherwise found in the atrophied optic papilla.

Symptoms of Papillitis.—In the early stages of optic neuritis, if the eye is examined by the direct ophthalmoscopic method, the disc will be seen of a rose-red colour; it is swollen and cloudy from effusion, so that its margin is more or less indistinct, by the indirect method this cloudiness may not be perceptible. In the less severe cases the arteries are not altered, but the veins are more or less engorged. This condition of the papilla may entirely disappear and the disc resume its natural appearance. If the inflammation, however, is acute, the outlines of the optic disc are completely obscured by the exudation and swollen nerve elements.

The papilla is frequently so much swollen as to project forwards beyond the retina, and it is then necessary to alter the strength of the lens in order to focus accurately the papilla and the retina. In consequence of the inflammatory exudation the bundles of nerve fibres crossing the disc

become prominent, and produce a striated appearance of the swollen papilla which extends into the retina. The calibre of the central artery is diminished, but the veins are tortuous and engorged, both sets of vessels are obscured as they pass into the effusion covering in the optic papilla. Hæmorrhages are not uncommonly seen over the papilla and in the retina. If the papillitis has been acute or of some duration, it too frequently happens that as the products of inflammation pass away we find that the nerve elements of the papilla, and retina are seriously compromised, and atrophy of the papilla follows.

Patients suffering from optic neuritis often complain of loss of sight which they describe as coming on suddenly; on the other hand we meet with cases in which there is evidence of effusion into the papilla, with but little impairment of vision. So that it is unsafe simply from the appearance of the optic disc to form an opinion as to the amount of vision which a patient possesses. In some instances there is marked contraction of the field of vision; in others a scotoma exists with impaired colour sense. The field of vision is generally contracted more on the nasal than on the temporal side. In all cases there is a diminution of the normal standard of light sense.

Etiology.—The most frequent cause of double optic neuritis is some form of intra-cranial disease, including meningitis and various morbid growths in the brain, abscess, hydrocephalus; certain constitutional maladies such as renal disease, glycosuria, syphilis, malaria, and rheumatism; pregnancy, menstrual disorders, anæmia, septic and lead poisoning. Papillitis may be met with in any of these conditions, but in none of them does it present any characteristic features which would enable us, from the appearances presented by the inflamed optic disc, to arrive at a conclusion as to the cause which had produced the papillitis. Beyond this, there is no constant relationship between inflammation of the optic nerve, and the seat of intra-cranial disease. It follows, therefore, that the presence of papillitis affords us but little assistance in our efforts to form a correct diagnosis, in obscure cases of cerebral disease; and in all cases of optic neuritis we shall have to rely upon other symptoms than those presented by the papilla, to enable us to form an opinion as to the nature of the conditions, which have given rise to the products of inflammation in, and around the optic

disc. It is true that not less than 75 per cent. of cases of double optic neuritis occur in patients suffering from intra-cranial new growths, including gummata, but the presence of neuritis does not assist us in localising the tumour. One of the most recent cases of the kind under our care illustrates this fact. The patient was suffering from total loss of sight, and among other symptoms had marked double neuro-retinitis, and long standing purulent discharge from the right ear, with great tenderness behind the ear. A central abscess was diagnosed, and the skull was opened, but no pus could be found. The patient subsequently died, and no trace of disease could be discovered in the cerebrum or its membranes, but the right portion of the cerebellum was found to be occupied with caseous tubercular nodules. The relationship between neuritis, and injuries to the skull and its contents, are equally ill-defined. If the injury has given rise to meningitis it commonly leads to papillitis, as we should expect from the connection that exists between the coverings of the brain and those of the optic nerve; but in cases of this kind the meningitis will probably have produced its characteristic symptoms, before the symptoms of inflammation of the optic disc are noticed. Fractures of the roof of the optic foramen usually give rise to optic neuritis, especially if the injury has led to hæmorrhage into the optic nerve. Effusion of blood into the sheath of the nerve from a contusion will, however, not unfrequently lead to papillitis. With reference to fractures of the base of the skull, optic neuritis is most commonly found in those of its posterior part, especially if the brain has also been lacerated.

Optic neuritis occurring in connection with intra-cranial injuries or disease, often depends upon an extension of the inflammatory process from its primary seat, to the optic nerve and papilla, along the connective tissue elements of the inner sheath of the nerve. In addition to inflammatory changes of this kind (descending neuritis), which spreads from an intra-cranial focus of irritation along the connective tissue of the nerve to the papilla, there is good reason to believe that matter possessing highly irritating qualities may pass from a central source of inflammation to the optic nerve, and papilla, by means of the fluid contained in the sub-arachnoid cavity, which communicates with that of the sub-vaginal space surrounding the nerve, and so to the

lymphatics of the optic papilla. (Fig. 42.) Moreover, anything which increases the amount of the sub-arachnoid fluid beyond its normal quantity, and consequently, that in the sub-vaginal space, may by pressure mechanically impede the flow of fluid through the blood-vessels, and lymphatic channels of the nerve and papilla, and so induce a faulty condition in the nutrition of the tissues constituting the optic disc. We may refer to syphilitic neuro-retinitis as illustrating the changes, and symptoms of an interstitial neuritis, and to malarial and rheumatic papillitis as examples of peripheral neuritis, in which the contents of the sub-vaginal space becomes affected. Optic neuritis may occur from the extension of erysipelatous inflammation of the contents of the orbit to the optic nerve, or from tumours or other disease of the orbit affecting the nerve in its passage from the optic foramen to the eye; it is also caused by the passage of septic organisms, from a diseased or injured eye to the papilla of the other eye (page 212).

The following clinical varieties of optic neuritis or neuro-retinitis are among those which require special consideration:—syphilitic, malarial, and rheumatic.

SYPHILITIC NEURO-RETINITIS.—This form of disease must be determined from the previous history of the case and symptoms, and not from any characteristic appearances presented by the papillitis; it is frequently complicated with diseases of the choroid and iris. Syphilitic neuro-retinitis commences with hyperæmia and swelling of the disc, and venous congestion of the retina, the arteries being diminished in calibre; the course of the retinal vessels is frequently marked by a greyish film, which runs along the outside of the vessels, gradually shading off into the healthy retina. The optic disc is swollen and hazy, the haziness extending beyond its circumference to a variable distance over the retina. This greyish film on the retina is seldom uniform, particularly near the axis of vision, where punctiform opacities of the retina are not unfrequently noticed. If the abnormal action continues, further changes in the retina become developed, for as the exudation becomes organised the tissues involved grow opaque, and the nerve structure of the retina is destroyed, a white glistening patch appearing in the place of the originally inflamed tissue. Hæmorrhages are not of common occurrence in this form of retinitis; but

the vitreous contains numerous dust-like particles, and subsequently flakes of opaque material.

Syphilitic neuro-retinitis is in many cases preceded by iritis, and irido-choroiditis, so that we may expect to meet with evidence of pre-existing mischief in these structures; nevertheless, this is not always the case. In any circumstances syphilitic neuro-retinitis having commenced, the patient complains principally of impairment of vision, it may be in one or both eyes; the diminution of sight may be sudden or may creep on slowly; it not uncommonly has periods of amendment, and then becomes worse than ever. The field of vision presents patches of almost total blindness, dependent upon the localised action of the poison on certain parts of the optic nerve, or of the retina, and thus compromising definite areas of the visual field.

In cases of syphilitic papillitis, if we find no marked changes in the retina or choroid, our prognosis may be favourable, even to the hope of restoring sight; but the disease being a constitutional one is apt to recur, unless the patient is placed under a long-continued course of mercury. When opaque patches have formed, we can entertain no hope of recovery in that part of the retina after continued or serous syphilitic papillitis; atrophy of the disc commonly supervenes.

Treatment.—We would refer the reader to the remarks already made regarding the treatment of syphilitic iritis; a long-continued, and carefully managed course of mercury in combination with full doses of iodide of potassium, should be the foundation of our treatment in cases of this description.

Inherited Syphilitic Neuro-Retinitis generally comes on in infancy, and, unfortunately, there are no external symptoms to mark the progress, or even the existence, of this formidable disease; it is only as the child grows older that his vision is discovered to be defective. Should indications of syphilitic inflammation exist in the papilla, we must resort to mercurial inunction, or the administration of the iodide of mercury.

Malarial Neuro-Retinitis.—In the *British Medical Journal* for March 8th, 1890, p. 540, we published cases illustrating the histories, and symptoms of patients affected with malarial optic neuritis. Instances of this description are perhaps more common in this country than is generally supposed, and in places where malaria prevails, cases of loss of sight in connection with malarial fever are certainly met with.

We have notes of a considerable number of cases of affections of the eye arising from this cause, but selected the cases referred to, because the patients came under observation at an early stage of the disease, although it is quite possible the neuritis may have existed for some time before the sight became impaired. We referred to cases of this description as far back as 1866, in the *Indian Medical Gazette*, and again in 1872. In the former of these communications, intermittent hemicrania with neuritis, in connection with malaria was discussed; and in the second, neuro-retinitis, the result of malarial toxæmia. Our idea was, that these affections of nerves in cases of malarial fever were the effect of peripheral neuritis, an idea referred to by Dr. B. Todd, who was under the impression, that periodical neuralgic affections were frequently due to the determination of some poison to a particular nerve, as the paludal poison, or some matter generated in the system, gouty or rheumatic. Dr. Todd thought that "there was no reason why such morbid matters should not affect a motor nerve as they affect a sensory nerve, causing paralysis in the one case and neuralgia in the other." He adds, "Sir W. Bowman has met with several cases of distinctly rheumatic paralysis of the portio dura, and also of some of the nerves of the orbit, at the Ophthalmic Hospital, Moorfields."

Among the patients whose cases we published, there was an entire absence of symptoms indicating either meningeal or cerebral disease; they all regained complete power of vision; they were not suffering from marked anæmia although they had enlargement of the spleen; there was no indication of serious renal mischief, nor was there any evidence of syphilis, or of rheumatism among them. Each of these patients was under the influence of malaria when they developed symptoms of neuritis, affecting the distribution of the optic nerve in both eyes. They all recovered their sight, but this is by no means the ordinary course of malarial neuritis or of neuro-retinitis, for if the fever continues, atrophy of the optic papilla and total blindness too often occurs. In the cases to which we have referred, the neuritis passed off gradually, because we were able to administer drugs, which destroyed for the time the influences which produced the fever.

After carefully watching cases of this kind, we incline to the idea that the inflamed state of the optic papilla is due to a **microbe** which becomes planted in the affected tissues, and

growing there produces ptomaines, which in their turn cause irritation of the tissues, engorgement of the vessels, and the transudation of serum and leucocytes into the retina and optic papilla. This effusion probably increases the already impeded circulation through the retinal veins, by pressure exercised upon them as they pass outwards through the discs. We may repeat that, whatever the direct cause of the changes observed in the optic papilla and retina, it had an intimate connection with the cause inducing the fever from which these patients suffered, for unless the fever could have been checked, the neuritis would have gone on to produce atrophy of the disc. In one of the cases above referred to, other nerves besides the optic were implicated, probably through analogous changes to those which had been observed in the distribution of the second nerve. Dr. A. G. McHattie, of Antigua, has published some interesting cases of malarial neuro-retinitis.

It has been suggested that the effusion and subsequent papillitis of malaria might depend on intra-cranial effusion, or perhaps to lightened arterial tension consequent on the ague fit; but in two out of the four cases referred to, the papillitis did not appear during or immediately after the ague; there were no symptoms of effusion on the brain. Moreover, if the neuritis depended on temporary alteration in the arterial tension, it would probably have cleared up with the removal of the cause which had produced it in place of remaining for weeks after the ague had disappeared.

The idea we have referred to, regarding the pathology of malarial neuritis as it affects the optic nerve is strengthened by the observations of Dr. Kipp on "Malarial Keratitis," published in the *American Ophthalmological Society's Report for 1889*. Dr. Kipp has had 120 cases of this kind under his care, and he states, that when the affected eye is carefully examined within a few hours of the commencement of the pain, photophobia, and circumcorneal congestion, that "not far from the margin of the cornea, a number of small greyish opaque elevations may be seen extending in a line towards the centre of the cornea. The following day the elevations give place to a narrow serpiginous ulcer, which extends superficially from without inwards," thrusting out branches in its progress, and reminding one of the fungoid growth which erodes the surface of our microscope lenses in India.

Dr. Kipp states that the duration of these ulcers of the

cornea depend on that of the malarial fever which is always present in cases of this kind. He remarks that "until the fever is cured, the affection of the cornea continues in spite of treatment." In fact, as in certain questionable syphilitic cases, we may be able to clear up the diagnosis by watching the effects of anti-syphilitic remedies on the disease, so in these malarial cases the beneficial action of quinine, arsenic, and strychnine are indicative of the nature of the affection from which the patient is suffering. In the optic nerve, and also in the distribution of the nerves of the cornea, it would appear that whatever the nature of malaria may be, it is sometimes capable of fixing itself on these structures, and, by producing irritation in the part may lead to destructive inflammation of these delicate tissues.

Rheumatic Neuritis and Neuro-retinitis.—It seems to us, that as in persons affected with malaria, the paludal poison may affect the structures constituting the optic papilla, so also, and for a similar reason, rheumatic people may suffer from optic-neuritis. The course of cases of malarial neuritis have a close resemblance to those of rheumatic papillitis; in the one set of patients the inflammation of the peripheral distribution of the nerve commencing in a person who for the time is under the influence of the paludal poison, while in the other he is under the influence of something which causes rheumatism. In the *British Medical Journal* for May 3rd, 1890, p. 1007, we have given the details of cases of rheumatic neuro-retinitis. It would be easy to multiply instances of this description from our own notes and from those of other surgeons, and it is remarkable they should have been almost overlooked until M. Parinand drew attention to them in his article published in the report of the French Ophthalmological Society for January, 1884. In the majority of such cases the patient's history points to inherited rheumatism, and he has himself suffered from this disease; exposure to damp and cold is generally described as the direct cause of the attack of pain in the eye and the loss of sight. The pain in these cases is stated by the patient to be deep seated in the orbit, and to extend from thence over the forehead and side of the head; it is worse at night, and is increased on pressure applied over the globe of the eye; dimness of vision and frequently total loss of sight is present, together with conjunctivitis and sclerotic congestion. The appearance of the inflamed papilla differs in no respect from that produced by malaria or other

causes, and although we seldom meet with double rheumatic papillitis, it is not uncommon to find first one disc and then the other involved in the disease. After the inflammation has passed away, although the patient's sight may be restored, the optic disc assumes a whiter appearance than that of a healthy eye.

When discussing the subject of malarial neuritis, we referred to a form of ulceration of the cornea described by Dr. Kipp, Dr. Von Millinger, and other authorities, and we meet with affections of the cornea which likewise appear to be connected with rheumatism, the ulceration, like that of malaria, being produced by a fault in the functions of the nerves supplying the cornea. This kind of corneal ulcer is described by W. Mackenzie, in his admirable treatise on *Diseases of the Eye*. He states that among rheumatic patients, especially those advanced in years, after exposure to cold it is not uncommon to find one of the patient's eyes affected with "a peculiar kind of ulcer—which is apt to spread over the surface of the cornea—at first it looks as if a portion of the surface of the cornea was loose and raised up, apparently through the intervention of fluid: the ulcer often cicatrizes without leaving any opacity, the cornea remaining merely irregular, as if part of it had been hacked off with a lancet; vision is disturbed by altered refraction." In these rheumatic affections of the cornea, as in the case of neuritis, we have a history of rheumatism and of deep-seated pain, usually worse at night, and increased by pressure or by movement of the globe; the epithelial layers of the cornea become detached by the effusion of fluid beneath, which, as in herpes, is the result of faulty nerve action; the ulcer extends slowly, and if allowed to run its course may last for weeks; but if treated by salicine, and subsequently with iodide of potassium, the pain and other symptoms speedily subside. The local application of a solution of eserine to the eye is often of service in cases of this kind. The patient's bowels must be kept freely open and his diet carefully attended to. And so in instances of rheumatic optic neuritis, if treated by the means above referred to the papillitis disappears, and the patient in all probability will recover his sight; on the other hand, if neglected, or if the disease in spite of treatment continues, atrophy of the optic papilla and permanent loss of sight too often result. In such a case the other eye will probably, sooner or later, be affected with papillitis of a similar character.

We have described in the first and subsequent editions of this work a form of neuro-retinitis with hyalitis occasionally met with among young males addicted to the practice of masturbation. An instance of this kind was lately under our care, and we are indebted to Mr. O'Kinealy, House Surgeon of the Royal Westminster Ophthalmic Hospital for the following notes:—"C., aged 15, of fairly healthy appearance, states that up to five weeks ago he had been able to see perfectly well with both eyes. He then suffered from some slight pain in the left eye, especially on looking to the left side, the eye was tender on pressure, and on closing the right eye he found that the sight in the left was very dim. He was therefore brought to the hospital, the left eye looked perfectly healthy and its tension was normal. The patient had always had excellent health, and his parents were alive and well; there was no history of either gout or rheumatism, but the lad stated that for three years he had been accustomed frequently to practise masturbation, he had a long foreskin which could not be drawn back over the glans. The left eye was tender especially on pressure, $V = \frac{6}{\text{nil}}$, the vitreous was very hazy, neuro-retinitis existed, and at the yellow spot there was a deposit of pigment in the retina which was opaque all round this area. Circumcision was performed, and the lad warned of the consequences unless he entirely abandoned his evil practices. Beyond this no treatment was adopted. On the 20th June the vitreous had begun to clear and the patient's vision was $\frac{6}{60}$, in a month's time it was $\frac{6}{36}$, and gradually improved; in November he read small type, and the hyalitis and neuritis had passed away, leaving a small black deposit near the macula; otherwise the fundus of the eye appeared normal." Cases of this kind are probably due to disturbance in the vasomotor centre controlling the blood supply, and so the irritation of the tissues implicated. The prognosis in such cases is favourable provided the patient will abandon his evil habits. So far as our experience extends the disease in these cases is, as a rule, confined to one eye.

Lead Poisoning.—We have at the present time an extremely well marked case of neuro-retinitis under our care in the Royal Westminster Ophthalmic Hospital, the result of lead poisoning. This patient has no albumen or sugar in his

urine, he has a deep lead line along his gums, and other indications of lead poisoning. The patient is a painter by trade. In both eyes there are hæmorrhages and white spots round the macula, together with extensive effusion into the papillæ and surrounding retina, both eyes are equally affected, and the patient's vision is practically nil.

Optic neuritis is met with among women suffering from *arrested menstruation*, we have seen cases of this kind which pointed conclusively to the relation that existed between the cessation of the menses and the dimness of sight produced by optic-neuritis. In such cases if the menstrual discharge is re-established, the papillitis clear up, provided the effusion into the disc has not existed for any considerable time, in which circumstances atrophy of its nerve elements is liable to occur.

CEDEMA (ANÆMIC) OF THE OPTIC PAPILLA is usually an acute affection, and is commonly the first stage of neuritis. From the anatomical relation that exists between the sheath of the optic nerve and the sub-arachnoid space it is evident that, if the contents of the cranium are augmented by the growth of a tumour, the arachnoid fluid may be forced along the sheath of the nerve into the optic papilla. Cœdema of the papilla may be produced in this way, and also by an excess of fluid in the arachnoid cavity, the inter-vaginal space of the optic nerve being frequently distended with serum. The fibrous stroma of the optic papilla is directly continuous with the sheath of the nerve through the lymphatic spaces. In this way we find that, if the sheath of the nerve is over-distended with serous fluid, numerous cells or cysts form in the papilla, from the pressure exercised by the effusion on the surrounding tissues (Fig. 42). It is evident, if changes of this kind can be effected in the connective tissue of the papilla, that its delicate nerve elements and vessels may likewise be injuriously pressed upon by an accumulation of serous fluid in the part. But optic neuritis is by no means a common result of serous exudation into the papilla. In cases of malarial fever, cœdema of the papilla is met with independently of neuritis. For instance, T., aged thirteen, was admitted into the Calcutta Ophthalmic Hospital, on January 24. On November 9 she was attacked with quotidian intermittent fever, to which she had been subject for some years past, as well as to enlargement of the spleen. The ague continued for a week, and then disappeared under the influence of such simple remedies as she had been accustomed to employ under similar circum-

stances. Immediately after the fever had left her, numbness and inability to move the right arm and leg came on; the left leg on the following day was affected in the same way, so that she entirely lost the use of her lower extremities, without the existence of tingling pain or other abnormal sensations in the limbs to mark the advent or progress of the disease. As the paralysis increased, she experienced advancing dimness of vision. There was no evidence of her having been affected by inherited or acquired syphilis. At the time of her admission into hospital, on January 24, she had completely lost voluntary power over her lower extremities and the right arm. The sensation in these limbs, though blunted, was not destroyed; marked reflex action existed in her legs; the muscles of the affected limbs were flaccid, and hung down precisely as though they had belonged to a dead body. The patient possessed feeble though decided voluntary power over her left arm. Her pupils were dilated and insensible to light, and she was almost completely blind, being only able to recognize the existence of a bright light held before her face in a dark room.

On examining the eyes with the ophthalmoscope we found the optic papilla swollen and hazy (woolly); evidently a considerable amount of serous effusion had taken place into its nervous structure, and also into that of the retina immediately surrounding the papilla; but with the exception of this œdematous state of the parts, the fundus of each eye was healthy. There was an entire absence of other symptoms of optic-neuritis or inflammation of the retina. Her voice and mental faculties were unimpaired. There was no paralysis of the muscles of her face, of respiration, or, in fact, of any part of her body, with the exception of those above indicated, nor was there evidence of disease of the heart or kidneys; her spleen was enlarged; the catamenia had appeared, and, though scanty, were regular.

The patient was ordered a generous dietary, and a mixture containing strychnine, arsenic, and iodide of potassium. She continued this treatment throughout her stay in hospital.

A week after admission some improvement had taken place in her condition, and, without going into details, it may be mentioned that she gradually regained the use of her limbs, her eyesight was restored, and she left the hospital absolutely cured. Within five weeks of her admission she could see to run about the ward, the haziness of

the optic papilla had entirely cleared away, and the fundus of her eyes was healthy.

This is an example of a class of cases by no means of uncommon occurrence among the natives of India, and depending apparently upon anæmia, the result of miasmatic influences. The symptoms presented by our patient at the time of her admission into hospital pointed to intra-cranial effusion similar to that noticed in the optic papilla, the pressure thus caused on the nerve centres interfering with the volition of the patient over the affected limbs. Reflex action was only slightly impaired, and the patient had complete control over her bladder; the functions of respiration and deglutition were perfect, so that, as far as the trunk was concerned, she simply suffered from inability to move some of her limbs, the centres of volition, but not the will, evidently being affected. The patient, however, was absolutely blind; the pupils were widely dilated, the functions of the retina being destroyed for the time being. The ophthalmoscope showed the cause of the loss of vision, by revealing to us the existence of extensive serous effusion into the optic papilla and retina immediately surrounding it, but there was no evidence whatever of hyperaction in the part; the circulation through the central artery and vein of the retina was unaffected; there was no hæmorrhage or indication of structural change, so that we were able to form a favourable prognosis, not only as regards the recovery of vision, but also as to the paralysis. The condition of the optic papillæ, and the history of the case, lead us to conclude that the loss of voluntary power over the affected limbs depended upon a similar cause to that which induced the loss of power in the retina, and hence to arrive at the conclusion above indicated as to the seat of the effusion in the brain, and from thence into the sheath of the optic nerve and papilla. Dr. V. P. Gibney, of New York, has published the results of some very interesting cases of intermitting spinal paralysis of malarial origin. Although the presence of œdema of the papilla is not referred to in these cases, nevertheless, in some respects they are of the same character as those above referred to. Dr. Gibney remarks:—"Let me state, too, on the strength of cases that I have not reported in this paper, because they were not intermittent, or relapsing, if this term be preferable, that there may be spinal paralysis affecting one side or a single member, clearly

traceable to malarial poisoning. They are not numerous, however, and the history will generally enable one to exclude a polio-myelitis anterior. If nervous diseases are increasing, as many authorities claim, may we not expect to find the cerebro-spinal axis the more readily and the more frequently influenced by malarial poisoning, just as we find now the nerves so commonly affected?"

We have met with cases of serous effusion into the optic papilla among young women suffering from amenorrhœa and other menstrual disorders. In instances of this kind the patient usually complains of headache and impaired sight, which increases periodically, and on examining the eye, distinct evidence of effusion into the optic papilla may be detected. Cases of this description are to be treated rather with reference to the state of the patient's general health than to the condition of the optic disc.

ATROPHY OF THE OPTIC DISC. — Atrophy of the optic papilla, as we have before stated, may occur after neuritis; it is then described as consecutive atrophy. But by far the greater number of cases of bilateral optic atrophy which we meet with in practice result from changes in the central nervous system, and are known as *primary atrophy* of the papilla. When the optic disc has become completely atrophied, it may be impossible from the appearance presented by the papilla, to determine the nature of the cause which has led to this change; nevertheless, we may be able, in no inconsiderable number of cases, to form a fairly good idea on this subject; and it may be important to do so, as an aid to diagnosis and prognosis in doubtful cases of disease.

The colour of the optic disc, as seen with the ophthalmoscope, depends on the reflection of light from its vessels and the lamina cribrosa, the nerve elements of the papilla being almost transparent. It is obvious, therefore, that if the structures forming the optic papilla are the seat of severe or of long-continued inflammation, that this process is likely to lead to the growth of cicatricial tissue in the part, which, as it contracts, must destroy, to a greater or less extent, the delicate nerve tissue and the capillaries of the disc. In consequence of changes of this description frequently confined to one eye, the papilla loses its natural colour and becomes of a white or greyish appearance, and the central vessels, especially the artery, is much diminished in calibre,

so as often to appear as a fine red streak passing over the white disc. The retinal vessels are not uncommonly marked with white borders, the result of peri-vasculitis. In advanced cases of consecutive atrophy the edge of the papilla is irregular, and marked with a zone of pigmentation with some choroidal atrophy. The disc is filled in by cicatricial tissue so that the mottled appearance of the cribriform fascia cannot be distinctly made out, and the papilla is of a uniformly grey colour, the central artery being contracted; in many cases there is distinct evidence in the retina and choroid of pre-existing inflammation. There is usually marked failure of the colour sense, but it presents many irregularities in the way in which the colours disappear; and so also with regard to loss of the field of vision it may be central or peripheral, according to the extent and area of nerve structure, which has been compromised by the inflammatory product.

In primary atrophy the natural rosy colour of the disc most frequently begins to fade on its outer side, but as this part of the papilla is paler than on its inner side, the change will hardly be noticed. If, however, the natural tint of the nasal half of the disc assumes a greyish or greyish-white colour, and at the same time there is increasing amblyopia, the circumference of the disc being regular and well-defined, we have to do with atrophy depending on some changes in the central nervous system. The appearance of the disc, however, alone, does not afford us conclusive evidence as to the nature of these central changes. In these cases the calibre of the retinal vessels may not be much altered, but there is excavation of the papilla, the cribriform fascia being on a plane posterior to the retina, and the nerve elements and vessels which fill up the healthy papilla having disappeared; the mottling of the cribriform fascia is marked, and the vessels from the retina as they pass over the edge of the disc curve backwards to their point of exit from the eye. In attempting to form an idea as to alteration in the colour of the disc, we must bear in mind the fact that its tint varies much in different people, and probably in the same person in different states of health. It is desirable in making an ophthalmoscopic examination in cases of this kind to employ a weak illumination, and to use the direct method of observation.

It seems almost superfluous to remark that atrophy of the

nerve fibres of the papilla must induce corresponding changes in the retina, and so lead to more or less impairment of vision, but it by no means follows that the whole of the papilla is always equally involved in the degenerative changes going on in the disc or optic nerve. Limited atrophy may not be detected by means of the ophthalmoscope, but the contraction of the field of vision indicates the existence of some serious lesion in the nerve apparatus, there being no abnormal changes to be seen in the fundus of the eye to account for the loss of sight. In all such cases it is necessary to be careful to eliminate errors of refraction as causes of impairment of vision. In the early stages of primary atrophy of the papilla there is diminished acuity of vision; both eyes are affected, but the loss of sight is generally more pronounced in one eye than in the other, and limited at first to the margin of the field of vision, from whence it advances concentrically; it frequently progresses more rapidly on one side of the field than on the other. In some cases a central scotoma marks the commencement of the failure of sight, but instances of this description are usually due to toxic influences, such as tobacco, alcohol, and lead. (See Chapter XV. on Central Scotoma.) Another constant symptom of commencing primary atrophy of the disc is loss of the colour sense; proceeding from the centre of the field outwards, we find that the patient loses the power of recognizing first green, then red, blue and yellow. In complete atrophy of the papilla whether primary or consecutive, the patient is totally and hopelessly blind.

Tabetic Optic Atrophy frequently comes under the observation of the ophthalmic surgeon in consequence of impairment of vision in both eyes, this condition being present in not less than thirty-five per cent. of persons affected with locomotor ataxy. It is probable that in cases of this kind abnormal disturbance in the vaso-motor centre interferes with the nutrition of areas of distribution of the optic nerve, and leads to progressive sclerosis of the connective tissue of the part, and so to atrophy of the papilla. In the early stages of these changes in the optic disc the patient complains of increased sensibility to light, he sees sparks and muscæ volitantantes before his eyes. The light sense becomes impaired, and the colour sense is disturbed; at first the perception of green, then of red, yellow, and blue are lost. At the same time the visual field contracts, sometimes in one direc-

tion, at other times in some other direction, but it closes from without inwards; and unless in cases complicated with alcoholism, lead poisoning, or tobacco, there is seldom a central scotoma. The pupils are generally small, they often vary in size in the two eyes, and are not unfrequently elliptical in shape; in the early stages of the disease they may react to light, but immediately they have dilated, there is a peculiar vacillating movement of the free margin of the iris. After a time the pupil fails to respond to the stimulus of light although they act in accommodation (the Argyll-Robertson symptom). Ultimately this power is lost, and the pupil remains motionless. In the early stages of tabes, hyperæmia of the optic papilla exists, being marked on the nasal side of the disc, its outer side at the same time becoming of a uniformly grey colour; the lamina cribrosa becomes well defined as the elements of the papilla undergo degeneration, the papilla is also excavated. If sclerosis of the connective tissue elements continues to advance, the central artery and vein are compressed, and they may become much contracted, but not unfrequently retain their normal calibre in cases of tabetic atrophy. Deposits of black pigment sometimes surround the margin of the papilla, especially on its nasal side. These changes in the disc as a rule take years to run their course; the degenerative process sometimes remains stationary for a considerable time. In some instances, however, especially when the papilla presents a soft, grey, gelatinous appearance, rapid degeneration of its structure occurs, and white atrophy of the disc and total blindness follow in a comparatively short period.

Congenital Anomalies of the Optic Disc.—Dr. De Beck, of Ohio, in the American Ophthalmological Monographs for October, 1890, has drawn attention to the fact that the optic disc is not unfrequently the site of congenital anomalies, due principally to defective obliteration of the canal of Cloquet and the hyaloid artery. About the sixth month of gestation this artery begins to contract, its branches passing to the lens disappear, the posterior end of the vessel and its canal thus forms a pyramidal process its base covering the optic nerve and projecting a short distance into the vitreous. This projection under normal development rapidly disappears, but at almost any stage the process may be checked, and there remains through life vestiges of these foetal structures. Dr. De Beck arranges these anomalies of

development into twelve groups of which there are several well recognised forms—rudimentary strands attached to the optic disc passing forward for a greater or less distance and terminating by an end which floats free in the vitreous; instances of this kind are familiar to ophthalmic surgeons. The origin of the strand can usually be traced to the central artery of the retina; it may sub-divide but not infrequently terminates in a knob-like swelling, or in fibrillæ; it may be symmetrical in both eyes or unilateral. In some cases of this kind we observe on the posterior pole of the lens a small opaque spot indicating the former attachment of the hyaloid artery to the posterior capsule. In a few instances the remains of the obliterated artery is found as a small rounded cyst upon the disc. Dr. De Beck refers to the records of eleven such cases, and to no less than twenty instances in which irregular clumps of tissue upon the disc were attributable to remnants of an imperfectly obliterated hyaloid artery. These cases in their less pronounced form are seen as little grey or bluish patches which obscure the exit of the retinal vessels, and perhaps extend slightly over the physiological cup. When larger these bands form a glistening white membrane covering in the entrance of the retinal vessels, and extending to a greater or less extent over the surface of the disc; they may be mistaken for pathological changes. This conclusion is more apt to be arrived at because in all such cases there is impaired vision. In some cases we find upon the optic disc small shreds or bands of connective tissue which may be so thick as to hide those parts of the vessels over which they extend. These little bands of glistening tissue are also remnants of the obliterated hyaloid artery and its canal; they have also been mistaken for pathological changes, but as a rule there is normal vision in this class of cases, or rather no evidence of neuritis past or present. Errors of refraction have commonly led to an ophthalmoscopic examination of the eye, and then the appearances referred to have been detected.

CHAPTER XI.

GLAUCOMA.

*Anatomy—Excavation of the Optic Disc—Glaucoma—
Pathology—Symptoms—Treatment.*

*Anatomy of the Angle of the Anterior Chamber and the Lymphatic System of the Uveal Tract** (Fig. 43).—The angle of the anterior chamber is the space bounded by the iris behind and the endothelium covering Descemet's membrane in front. At a distance of one millimètre from the angle, Descemet's membrane becomes suddenly attenuated and connected with a number of elastic fibres which interlace and become more numerous as they pass outwards, expanding towards the angle into a reticulated tissue. The trabecular part of this tissue is not only connected with the marginal ring of the membrane of Descemet, but also form the anterior root of the iris, the ligamentum pectinatum iridis. The spaces formed by the above trabeculæ are lymph channels, and are called the spaces of Fontana, which are bounded in front by the junction of the cornea and sclerotic and the canal of Schlemm, behind by the anterior root of the iris; internally it is separated from the endothelium by the marginal ring of Descemet's membrane, and externally it is connected with and bounded by the fibres of origin of the ciliary muscle.

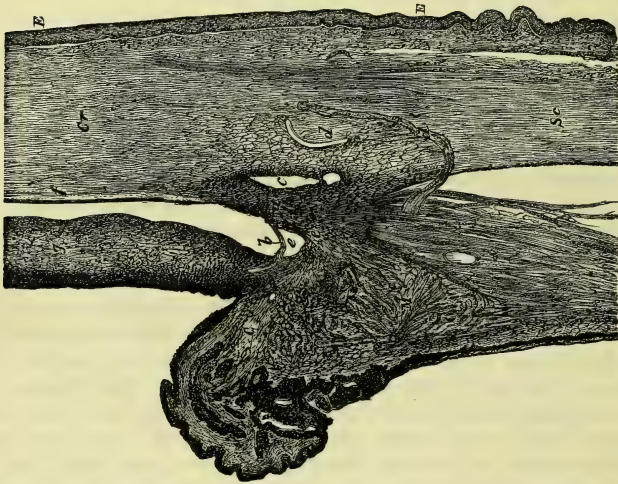
The canal of Schlemm encircles the fore part of the eye; it is situated in the sclerotic, close to its junction with the cornea, and only separated from the anterior chamber by the

* See previous edition of this work, Chapter i, on Anatomy of the Eye, by Dr. G. L. Johnson.

ligamentum pectinatum (with which it lies in contact), and Descemet's ring and endothelium. The canal communicates with the spaces of the ligamentum pectinatum and through them with the anterior chamber; and also with the adjacent inter-fascicular lymph-spaces of the sclerotic.

As bloodvessels are more or less opaque, it becomes a matter of necessity for uninterrupted vision, that the media of the eye through which rays of light pass to the retina

FIG. 43.



Horizontal Section through the Tissues around the Angle of the Anterior Chamber.

- | | |
|----------------------------------|-------------------------------------|
| <i>a.</i> Ligamentum pectinatum. | <i>b.</i> Prolongation of the Iris. |
| <i>c.</i> Canal of Schlemm. | <i>d.</i> Bloodvessels. |
| <i>e.</i> Spaces of Fontana. | <i>f.</i> Descemet's Membrane. |

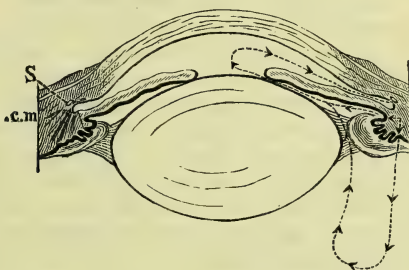
C, ciliary body; I, iris; M, ciliary muscle; Sc, Sclerotic;
E E, Epithelium.

should be nourished by means of colourless lymph. Any disturbance in the circulation of this lymph, either by affording an increased or diminished flow, or by obstructing its escape, is immediately followed by an alteration in the tension of the globe, and if considerable or prolonged, will

lead to structural changes in the eyeball itself. The lymph formed in the tissues of the eye is discharged from them along three different paths. That portion which is secreted by the iris and ciliary processes finds its way to the angle of the anterior chamber, and thence percolates through the spaces of Fontana to the canal of Schlemm, and so on (Fig. 44). This constitutes the anterior lymphatic system.

All those parts of the globe situated behind the ciliary body and outside the vitreous chamber discharge their lymph in one of two ways—that from the choroid and sclerotic escaping along the sheath of the *venæ vorticosæ*, that from the retina by a tract within the optic nerve. The two last-

FIG. 44.



G.L. Johnson.

View of the Anterior Part of a Healthy Adult Human Eye divided horizontally through the middle, and intended to show the normal shape of the angle of the anterior chamber and the comparative size of the different parts in health. The dotted line shows the path of lymph from the ciliary body to Schlemm's canal.

named tracts constitute together the posterior lymphatic system.

The iris and ciliary body form the chief sources of lymph supply for the nourishment of the vitreous and lens. The lymph, after circulating through the vitreous passes into the canal of Petit, and thence through a series of fine fissures which exist in the zonula ciliaris, close to the border of the lens, into the posterior chamber. From this it passes between the iris and the capsule of the lens into the anterior chamber. Under normal conditions the iris rests against the lens so closely as to form a kind of valve, which only allows of a current in a forward direction, any pressure in the

anterior chamber only shutting the valve the closer; nor can this resistance be overcome except by a change of form of the globe of the eye, as results from increased intra-ocular pressure which may be artificially produced by injections into the anterior chamber.

The lymph of a large portion of the ciliary body and iris is secreted directly into the posterior chamber, and accompanying the former current passes forwards through the valve to meet a third stream, which finds its way into the anterior chamber through the meshes of the ligamentum pectinatum. Minute fissures exist in Descemet's membrane and endothelial covering in the neighbourhood of the angle of the anterior chamber, by which communication is established. The lymph in the anterior chamber discharges itself into the canal of Schlemm through similar meshes near the point of constriction of Descemet's membrane, and thence into the anterior ciliary veins. The lymph returning through the canalicular spaces of the sclerotic and cornea also joins the main stream at the canal of Schlemm.

The manner in which the canal of Schlemm is connected with the veins in its vicinity is still unknown. In all probability certain valvular arrangements exist which prevent the passage of venous blood into the canal of Schlemm under the normal conditions of pressure. Were the lymph of the anterior chamber to empty itself directly into the lymphatics, so rapid an outflow would occur that the sluggish transudation of fresh fluid into the chamber could not be possibly compensated for, and the cornea would collapse. This, however, is avoided by the intervention of the canal of Schlemm, which does duty as a regulator between the two. The fact that in the small veins the pressure is always higher than in the corresponding lymphatics, and the resistance which the trabecular meshes offer to the outflow, also tend to equalize the two streams. Injections into the anterior chamber can be readily made to pass into the anterior ciliary veins in the above manner. The anterior chamber does not communicate directly with the peri-choroidal space, or Tenon's space, or with the lymphatics of the conjunctiva—but it does so indirectly through the communications of the spaces of Fontana with the canalicular system.

Lastly, there is a current of lymph from the vitreous which enters the substance of the lens through the external layers of its posterior half.

The lymphatics of the choroid and sclerotic pass directly into a lacuniform space situated between the sclerotic and choroid throughout their whole extent from the ciliary body to the optic nerve. (Fig. 45, *pch.*) This space is not patent, as in the diagram, but its walls are held together by a trabecular tissue, composed of numerous flat lamellæ made up of elastic fibres and branched nucleated connective-tissue corpuscles. The lamellæ are covered with an endothelium like that of ordinary lymphatic canals, and are separated from one another by more or less continuous lymph spaces. On the outer side of the sclerotic is another very similar lymphatic channel, Tenon's space. The blood of the choroid is removed by four large veins—the venæ vorticosæ which, piercing the sclerotic obliquely at a point midway between the optic nerve and the cornea, open directly into the ophthalmic vein. A peri-vascular lymphatic sheath communicating with both the above spaces, surrounds each vein in its passage through the sclera, and hence the lymph flows readily from the perichoroidal to Tenon's space. At the posterior pole of the eye around the entrance of the optic nerve, Tenon's capsule forms a covering for the external sheath of the optic nerve; between these two, therefore, is the continuation of Tenon's space (supra-vaginal space), which opens directly through the canalis opticus into the arachnoid cavity of the brain.

FIG. 45.

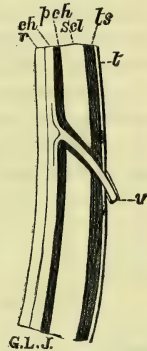


Diagram showing the Communication between Tenon's Space and the peri-choroidal Lymph Channel. *r*, retina; *scl*, sclerotic; *ts*, Tenon's space; *t*, Tenon's capsule; *v*, vena vorticososa; *pch*, peri-choroidal spaces. (Copied from Schwalbe, in Stricker's Handbook.)

EXCAVATION OF THE OPTIC DISC.—In this condition of the papilla, if the direct ophthalmoscopic method be employed, and the vessels at the margin of the excavated disc are accurately focussed, their continuation over the papilla cannot be distinctly seen till the accommodation of the observer's eye is altered, the vessels on the disc being on a plane posterior to those of the retina. By the indirect method, in

deep cupping of the optic disc, the floor of the pit can be seen below the level of the fundus by moving the objective lens slightly from side to side. The margin of the disc will move in the same direction as the lens at a greater rate than the floor of the disc, and will present the appearance of actually moving to and fro over it.

Excavation of the optic disc may result from increased intra-ocular pressure, as in glaucoma; from congenital malformation; and from atrophy of the optic nerve.

In glaucomatous excavation the whole of the disc is involved, the sides of the depression are steep, sometimes even overhanging, because the border of the disc is smaller than at the level of the choroid. (Fig. 46.) The vessels at

FIG. 46.

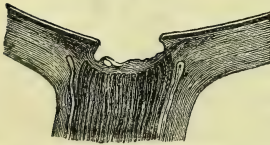
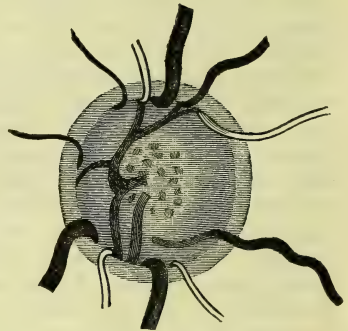


FIG. 47.



the margin of the disc terminate, as it were, in hook-shaped extremities as they dip down into the hollow, formed by the protrusion backwards of the lamina cribrosa; they reappear on the floor of the excavated disc where they have a lighter shade. (Fig. 47.) The colour of the disc is of a greenish-grey or white, and it is surrounded by a white rim of partially exposed sclerotic. In long-standing or neglected cases of glaucoma, not only is the disc excavated, but the optic papilla is atrophied.

In cases of excavation of the papilla arising from congenital malformation (physiological cupping), the whole of the disc is seldom involved; but we have seen congenital cases in which the entire disc was cupped, with the exception of a narrow border at its circumference. Physiological excavation

as a rule does not involve much of the nasal side of the disc, and over this part the vessels can be followed; it may extend over the greater part of the temporal half. When large the excavation is funnel-shaped, so that the vessels can usually be followed down the side of the depression. With the exception of this depression of a portion of the optic disc the fundus of the eyes may appear normal. Physiological cupping is a matter of little importance as it leads to no pathological changes in the eye.

In excavation of the disc arising from complete atrophy, the lamina cribrosa presents a uniformly greyish-white colour, and appears to be depressed in consequence of the nerve elements which naturally cover it having disappeared. The vessels from the retina as they cross the disc to their point of entrance or exit from the eye are on a plane behind the retina, so that the vessels on the disc will be indistinctly seen if those coursing over the retina are accurately kept in focus.

Glaucoma is characterized by increased tension of the eyeball, page 23. It commonly attacks both eyes either at the same time or consecutively, and, for clinical purposes, it may be conveniently described under three heads: *Glaucoma*, *Glaucoma Simplex*, and *Secondary Glaucoma*.

1. *Glaucoma* depends on some impediment to the normal escape of lymph from the eye, and is probably due sometimes to neurosis of the vaso-motor nerves, and an abnormal secretion of fluid within the eye; in other cases, to either persistent or temporary obstruction in the lymphatic spaces at the angle of the anterior chamber. Section of the fifth pair of nerves is followed by diminished tension of the eye; irritation of these nerves causes increased intra-ocular pressure by augmenting the amount of serous fluid within the eyeball. Suffering excitation of the fifth nerve to occur, and, in consequence of the increased intra-ocular pressure thus produced, the lymph channels at the angle of the anterior chamber are pressed outwards and closed, it follows that so long as this abnormal pressure exists lymph cannot freely leave the eye, and so increased tension of the globe is maintained. Further, the lymphatics and veins of the choroid and ciliary body leave the eye by means of a few large branches which pierce the sclerotic obliquely, page 273. The consequence is, that augmented intra-ocular pressure, not only interferes with the passage of lymph outwards from the

eye through the anterior, but also through the posterior lymphatic system. Intra-ocular pressure, therefore, once established tends to increase, and it forces outwards the weakest part of the outer case of the globe, that is the lamina cribrosa, which becomes in this way cupped or excavated.

We occasionally meet with hypermetropes beyond the middle age of life, and some younger, who have naturally a shallow anterior chamber, and this condition is found among several members of the same family; it appears to be hereditary. People with a considerable amount of hypermetropia often work on for many years, depending on the aid of their ciliary muscle to help them over their defective vision. Constant and excessive exertion of this muscle, however, leads to hypertrophy and induration of the structures in the ciliary region, and so to an abnormal state of the tissues immediately outside the spaces of Fontana (Fig. 43). Beyond this, as these people advance in life, they are liable to spasm of the dilator pupillæ; the pupil thus becomes habitually somewhat dilated, and fails to respond to the stimulus of light. This state of things may continue without any material change, but at any moment, some exciting cause, as for instance, neglect to wear the proper correcting glasses, exposure to a cold wind, or fog—overwork, or trouble, seems to convert the passive into active spasm, the pupil dilates, and the iris shrinks against the angle of the anterior chamber and blocks the lymph spaces in that locality, the surrounding tissues having undergone changes, such as those above referred to, in consequence of the prolonged overwork to which the ciliary muscle has been subjected. A combination of influences of this description, may interfere to such an extent with the anterior lymphatic system of the eye (Fig. 44, page 271), as to prevent the free passage of lymph through the spaces of Fontana and the canal of Schlemm, increased intra-ocular tension results, and the greater the tension the more complete must be the obstruction of the passage of lymph from the eye. We can thus account for the symptoms present in the early stages of glaucoma; and while this state of things lasts, at any moment the flow of lymph outwards may become completely obstructed, and an attack of acute glaucoma supervenes, with engorgement of the deep episcleral vessels, and consequently further alteration in the nutrition of the tissues included in the ciliary region. Supposing the causes above referred to act in the manner de-

scribed, we can readily understand the beneficial action which eserine exerts on the disease, by contracting the pupil, and so drawing the iris from its unnatural position against the angle of the anterior chamber. In the same way we can account for the disastrous action of atropine in cases of incipient glaucoma, for this drug increases the pressure of the iris against the lymph spaces of the anterior chamber. We can by the aid of this theory, also comprehend why glaucoma is so often met with in neglected cases of hypermetropia, and is seldom seen in uncomplicated myopia. It should be clearly understood that we by no means advance this idea as being *the* cause of all cases of glaucoma, for any other conditions which obstruct the natural flow of lymph outwards from the eye, may be equally capable of exciting an attack of this disease.

Mr. Priestley Smith explains that glaucoma may depend either on increase in the size of the lens (senile), or upon an affection of the ciliary body by which the circumlental space is diminished, so that the passage of fluid from the vitreous to the aqueous chamber is interfered with, and glaucomatous symptoms result. Mr. Priestley Smith remarks that, if the circumlental space is obstructed, "the escape of fluid from the vitreous chamber is retarded, the vitreous chamber becomes over-filled, the lens and its suspensory ligament advance, pushing the ciliary processes against the periphery of the iris, the periphery of the iris applies itself to the posterior surface of the cornea, the angle of the anterior chamber (Fig. 43) is closed, and glaucoma is established. Then, as the pressure rises, a passive hyperæmia is set up, in a manner which is explained by Dr. A. Weber," who holds that the ciliary processes, becoming swollen from various causes, push the iris forwards, and so start the glaucomatous state. With reference to this theory, one is disposed to inquire why glaucoma is not more frequently found among aged people, supposing it depends upon senile increase in the size of the lens.

Recent anatomical and pathological researches have done much to demonstrate the importance of the lymphatic structures at the angle of the anterior chamber of the eye; and in some specimens taken from glaucomatous eyes Fontana's spaces and Schlemm's canal have been found occluded, and so it is assumed the escape of fluid through this channel had thus been prevented. Supposing that the anterior lymph

path had been only partially closed, from the effects of inflammation extending from the iris or ciliary body, the escape of lymph from such an eye would be retarded, increased tension of the globe would probably follow, and so augmented pressure and obstruction to the lymphatic and venous circulation from within the eye outwards might occur. In these conditions, in a case of passive glaucoma a slight excess of effusion would give rise to a paroxysm of acute glaucoma. With reference to these ideas, however, we are not as yet in possession of a perfectly satisfactory anatomical explanation as to the cause of the symptoms, to which we apply the name, glaucoma.

Symptoms.—Glaucoma frequently commences with transient attacks of dimness of vision, during which, if the patient looks at a bright light, he observes a halo surrounding the luminous object; there is uneasiness in the eye, amounting in some cases to supra-orbital pain so long as the cloudiness in the field of vision continues; and at such times there is increased tension of the eyeball. An attack of this kind may last for an hour or so, but often continues for several days and then passes away, leaving the patient's sight perfectly clear. Symptoms of this description are usually excited by causes such as those to which we have referred. In the course of time these symptoms become more pronounced, the attacks more frequent, and the *tension of the eye-ball becomes decidedly and constantly augmented*. The field of vision is found to be contracted, especially from the nasal side; the colour and light sense are both diminished. The pupil in the affected eye is dilated, and does not respond to the stimulus of light; the anterior chamber is shallow. The optic disc is cupped, and the retinal veins engorged, the pulsation of the artery may often be seen. The supra-orbital pain increases and extends to the head and side of the nose. The pain and other symptoms referred to may, after a time become less severe, and in part pass away, to return, however, commonly with increased violence within a short period. As the disease runs on, the tension of the eye continues to increase; the cornea assumes a hazy appearance, the iris is blurred, and some large and engorged episcleral vessels are seen passing over the sclerotic.

In some cases of glaucoma, symptoms such as those referred to, but of increased severity, set in from the commencement of the attack. Without any obvious cause the patient is

seized with severe pain in the affected eye; its tension is considerably increased, there is extreme cloudiness, amounting almost to loss of vision; the pupil is dilated; and the iris muddy. The cornea looks dull and may be anæsthetic; there is engorgement of both the small and also the larger episcleral vessels. In cases of this kind, from the early stages of the disease, if the patient can bear the light and the media are sufficiently clear, we find the optic disc is cupped, the retinal veins are engorged and tortuous; hæmorrhages into the retina are not unfrequently met with. Acute attacks such as this may last for a week or ten days; in the more chronic cases for months, or even a year and upwards, but unless properly treated the result is the same in all cases of glaucoma—the globe becomes excessively hard, the cornea hazy and anæsthetic, the pupil is dilated and the lens appears opaque and of a greenish colour—the patient's sight is completely destroyed in the affected eye. Although glaucoma may be confined to one eye at first, it sooner or later appears in the other eye. The disease having run its course, the pain usually subsides, but the patient is left totally blind.

Glaucoma Simplex.—In these cases there is little, if any, episcleral congestion, or in fact any marked external features of disease in the affected eye. It is in consequence of the absence of any prominent symptoms that cases of this kind are apt to be overlooked in their early stages. There is little, if any, pain in the eye, but there is gradual contraction of the field of vision, dimness of sight, and increased tension of the eyeball. This impairment of sight is not improved by glasses, and on examining the eye we find the optic disc is cupped, and of an abnormally white colour; the pupil is dilated, and responds but slowly to the stimulus of light. Both eyes are frequently affected, and the disease progresses in this insidious manner until the tension of the eyeball is much increased, and the patient's sight passes from dimness to darkness. The termination of this form of glaucoma, which may take several years to run its course, is stony hardness of the globe, cupping of the optic disc, dilated pupil, opaque lens, hazy and anæsthetic cornea, and complete loss of sight.

Secondary Glaucoma may follow various diseases of the eye; as, for instance, cases of cyclitis, occlusion of the pupil, diffuse keratitis, and anterior staphyloma of the sclerotic. It occasionally occurs after wounds of the lens, or from irritation induced by the presence of a dislocated lens in the vitreous.

Lastly, we sometimes meet with secondary glaucoma, supervening in cases of retinal or choroidal hæmorrhage. Cataract, and high conditions of myopia are occasionally complicated with glaucoma, usually in one eye; these cases run the same course as in ordinary instances of this disease; in the hæmorrhagic variety, however, iridectomy must be avoided.

Treatment.—With regard to the treatment of glaucoma, unless in certain cases to which we have referred, a large iridectomy (page 201), if practised sufficiently early, may arrest the further progress of the disease. In performing iridectomy in cases of glaucoma it is as a rule advisable to administer an anæsthetic, for a solution of cocaine cannot be relied upon to relieve the pain during the operation, especially if there is congestion of the conjunctival and other vessels of the eye; beyond this cocaine, like atropine, may cause sudden and dangerous increase in the intra-ocular tension.

In cases of glaucoma, therefore, unless in the hæmorrhagic form, in which the symptoms are well developed, a solution of sulphate of eserine, gr. ij to the ounce, should be applied to the eye several times in the course of a few hours, and then an iridectomy should be performed. On the other hand, if the symptoms of glaucoma are subacute, and the patient's anterior chamber is shallow, there being marked hypermetropia, we should order eserine to be applied to the eye perhaps twice a week or oftener, according to the urgency of the symptoms. Above all things, carefully correct the error of refraction by means of proper lenses; in such cases, if glasses are *constantly* worn, the glaucoma may be arrested, especially if a weak solution of eserine (gr. $\frac{1}{2}$ to gr. j to the ounce) be applied to the eye whenever the patient's sight becomes cloudy, or he sees a halo round a bright light. The same remark applies to glaucoma in cases of advancing posterior staphyloma. In chronic glaucoma (simplex) correct the hypermetropia which is often found in such cases. Iridectomy cannot be relied upon; in fact, we know of no treatment which we can trust to relieve the symptoms in these cases, eserine is useful, and should be always employed, but the disease will probably advance in spite of our efforts to stay its progress. In the majority of such cases we must bear in mind the fact, that the operation of iridectomy is not without its attendant evils. In the first place, in spite of all we can do, a tag of the iris may become entangled in the wound, and set up irritation in the other eye. Beyond this,

experience teaches us that, after performing iridectomy for the relief of glaucoma in one eye, the other eye becomes more disposed than it otherwise might be to glaucoma. On this subject we cannot do better than refer to the opinion of Dr. D. Webster, of New York. He remarks:—

“An operation for the relief of acute glaucoma in one eye may quickly be followed by an attack of the same disease in the other. Von Graefe, who first performed the operation of iridectomy for the cure of glaucoma, also first observed and described the complication of which we speak. In his experience the fellow-eye was attacked within fourteen days after the operation on the first, in about thirty per cent. of the cases in which the operation was done for primary inflammatory glaucoma; it sometimes occurs after an operation for chronic glaucoma. The patient invariably attributes the attack in the second eye to the operation upon the first, and, if not informed beforehand of the possibility of its occurrence, will be very likely to blame the surgeon for withholding his knowledge of such liability. It is now very generally conceded that the attack of glaucoma excited in the fellow-eye, in such cases, is not a true sympathetic inflammation. It is believed rather that anxiety of mind, the excitement attendant upon an operation, the hyperæmia of the eyeball, caused by the administration of ether, and the shutting up of an eye with a bandage, are sufficient to awaken an acute attack in an eye already predisposed to glaucoma. And it is fair to infer that an eye which has shown no glaucomatous symptoms, subjective or objective, is *predisposed* to the disease if the fellow-eye is so affected.”

The risk of iridectomy, therefore, being by no means considerable, the question arises as to any less serious operative means by which we can relieve the symptoms of glaucoma. Supposing a patient suffering from subacute glaucoma, although under the influence of eserine continues to suffer from attacks of circumorbital pain, and that his field of vision steadily diminishes, it may seem advisable to perform *Sclerotomy*.—This operation is strongly advocated by M. De Wecker, who remarks: “I have had sclerotomes made, varying in breadth from two to four millimetres, with lance-shaped points. With this instrument at a distance of one millimetre from the margin of the cornea, I transfix the anterior chamber, but in such a way that the edge of the sclerotomy shall form a tangent to the inferior or superior

extremity of the vertical diameter of the cornea, and that it shall, as it passes through the anterior chamber, incise the angle of the iris in its whole extent." But the iris is likely to become entangled in the wound, and cause an attack of sympathetic cyclitis in the other eye.

In cases of hæmorrhagic glaucoma, iridectomy must not be attempted; the same remark applies to instances of complete glaucoma. The reason is that in hæmorrhagic glaucoma the sudden relief of tension would probably lead to extensive extravasation of blood into the globe of the eye. In cases of complete glaucoma, the risk of inducing sympathetic irritation in the other eye is so great after iridectomy, as to lead us to advise the removal of the diseased globe, if it causes the patient pain or irritation rather than run the risk of an iridectomy.

Atropine should never be applied to the eyes of patients suffering from glaucoma or a suspicion of increased tension of the globe of the eye; in not a few cases, the use of this drug in these circumstances has been followed by an attack of acute glaucoma. Patients having a fair amount of vision have had a solution of atropine applied to the conjunctiva; in the course of two or three hours pain and increased tension of the eyeball has followed, lasting probably three or four days, and ending in complete loss of sight in the affected eye. We have seen an attack of acute glaucoma follow the application of cocaine to the eye. In any such cases an iridectomy must be performed as soon as possible.

CHAPTER XII.

DISEASES OF THE RETINA.

Anatomy—Hyperæmia of the Retina—Retinitis—Retinitis Albuminurica—in Pregnancy and Diabetes—Retinitis Pigmentosa—Hæmorrhage into the Retina—Retinitis Apoplectica—Embolism of the Central artery of the Retina—Detachment of the Retina—Opaque Nerve Fibres—Glioma of the Retina.

THE RETINA.

ANATOMY.—The retina is the internal tunic of the globe, and is a membrane composed of delicate nerve fibres and cells, capable of perceiving and transmitting to the brain through the optic nerve the images of external objects formed upon it. The retina is in contact and intimate relation by its outer surface with the choroid, it lines the whole of the posterior part of the eyeball and extends forwards to the commencement of the ciliary processes, where the nerve elements cease in an irregular margin, the ora serrata, the more external part of the retina, *i. e.*, the epithelial portion extends forwards to take part in the formation of the ciliary bodies ending on the posterior surface of the iris.

In structure, the retina consists of nerve-fibres and cells, arranged in well-defined, sharply demarcated layers, running parallel to the surface and supported by a remarkable framework of connective tissue, the fibres of Müller. From without inwards the following layers may be recognised: 1. The pigmented epithelium. This forms a single layer of nucleated polygonal cells, forming an hexagonal mosaic pavement on the surface of the lamina vitrea. The inner

portion of each cell is prolonged into a brush of densely pigmented processes, in which the rods are imbedded. The outer parts of the cells have little or no pigment. 2. The layer of rods and cones. 3. The limitans externa. 4. The outer nuclear. 5. The outer molecular. 6. The inner nuclear. 7. The inner molecular. 8. The ganglion layer. 9. The layer of nerve fibres; and lastly, 10. The membrana limitans interna. The nuclear layers are recognised at once by their large cells and deep staining. The molecular layers are known by their fine granular appearance and inaction to logwood and carmine. The ganglion cells and nerve fibres in their respective layers require special methods of treatment to bear the least resemblance to pictures of them in modern text-books.

In the axis of the eye 2.5mm. to the outer side of the optic papilla, is the macula lutea, which with the ophthalmoscope appears somewhat darker than the rest of the fundus, shading off gradually into the surrounding colour; the spot is about the size of the disc and is marked in the centre with a depression, the fovea centralis; the macula is the region of most acute vision; over this part the rods of the retina are absent but the cones are numerous, large and well developed. It is pink in health, the yellow appearance being due to post mortem changes. The large blood vessels of the retina pass above and below, but never across the yellow spot. Minute vessels pass directly to it from the papilla, terminating at the border of the fovea by means of capillary loops, so that this last is quite destitute of vessels. The retinal vessels are surrounded by peri-vascular lymph spaces similar to those of the iris. The large arteries and veins are all situated in the nerve-fibre layer of the retina, the other layers, as far as the inner granular layer, being supplied by minute loops from the arteries. The external granular layer and the rods and cones are, like the fovea centralis, destitute of vessels.

Where the optic nerve perforates the lamina cribrosa all the nerve-fibres lose their medullary sheaths, and the delicate axis cylinders, which alone remain, pass round the margin of the shallow optic depression and form the internal layer of the retina.

We are ignorant as to the mode in which stimulation of the retinal elements is effected, but it is remarkable that if an animal is killed in the dark the retina has a purple colour

which at once disappears on exposure to light. If an animal is killed at the moment an image is formed on the retina, and the membrane is placed in a solution of alum, the image may be found and seen on the retina. Mr. Lloyd Morgan believes, that the discharge of the colour of the retinal purple may be regarded as the sign of chemical change, affected by the impact of the light relations. But in the yellow spot there seems to be no visual purple. It is indeed developed only in the rods, not in the cones. Here, probably chemical or metabolic changes occur, without the obvious sign of the blanching of retinal purple. In the dusk-loving owl the retinal purple is well developed, but in the bat it is almost absent. ("Animal Life and Intelligence.")

Hyperæmia of the Retina.—We frequently meet with patients suffering from inability to continue using their eyes, in consequence of pain caused by any prolonged effort made to see near objects. On examining the fundus oculi of such persons we may find the optic disc of a uniformly bright red colour, but its margins are distinct, and the retinal vessels of their normal size. It is difficult to appreciate changes of this description, on account of the great physiological differences which may exist in the colour, and appearance generally of the vessels of the retina in different people. But there can be no doubt that among persons suffering especially from low degrees of refractive errors, the increased effort of accommodation necessary to overcome such errors, produces hyperæmia or congestion of the vessels of the papilla and retina. In the same way watchmakers and other persons engaged for many hours on minute objects, tailors, especially, if working in a bad light, by constantly straining their eyes may induce a persistent congestion of the retinal vessels, and an extremely irritable and painful state of the eyes. This state of things can only be relieved by correcting the cause, whatever it may be, which necessitates the over-straining of the eyes.

Passive congestion of the veins of the retina, together with pulsation, may be caused by anything which interferes with the passage of the blood outwards from the eye, such as the intra-ocular pressure of glaucoma; pulsation, however, in the retinal vein does not necessarily indicate any pathological condition. On the other hand arterial pulsation of the retinal artery points to either increased cardiac action or to augmented intra-ocular tension.

Ischæmia of the retina has been noticed to occur in the paroxysms of whooping cough; from overdoses of quinine; and in embolism of the central artery.

Retinitis.—In consequence of the intimate relations that exist between the choroid, optic papilla and the retina, it follows that inflammation is seldom confined to any one of these structures. And in practice we find that neuro-retinitis or retino-choroiditis is more common than retinitis. Nevertheless we meet with instances of retinitis, generally the result of syphilis, or other constitutional affections. Persons having disease of the kidney, diabetes, septicæmia, leucæmia, and malaria are apt to suffer from retinitis.

The ophthalmoscopic signs of retinitis are, loss of the normal transparency of the retina, fulness and tortuosity of the vessels, with flame-shaped hæmorrhages and exudation.

RETINITIS ALBUMINURICA.—Interstitial retinitis occurs from time to time among patients suffering from Bright's disease of the kidneys, the neighbourhood of the macula lutea being chiefly implicated. In these cases of kidney disease, the retina presents certain elements which are variously combined in different cases. These are:—1, Diffuse slight opacities and swelling of the retina, due to œdema of its substance. 2. White spots and patches of various size and distribution, due for the most part to degenerative processes. 3. Hæmorrhages. 4. Inflammation of the intra-ocular end of the optic nerve. 5. The subsidence of inflammatory changes may be attended with signs of atrophy of the retina and nerve.

These changes are due to œdema, and patches of increased growth of the elements of the connective-tissue fibres of the retina; these fibres become thicker, presenting an almost glistening whiteness when seen by the ophthalmoscope. Sections made through the diseased portions of the retina, demonstrate the existence of peculiar club-like swellings of the nerve fibres; these thickened fibres refract light strongly. The diseased structures are infiltrated with granular matter, white blood corpuscles, and cells which appear round or semi-lunar, with one or more offsets and a shining round nucleus. There is not unfrequently a layer of granular cells beneath the membrana limitans, so that this membrane protrudes into the vitreous body. In both the inner and outer layers of the retina, cavities form containing peculiar branched cells.

Detachment of the retina to a greater or less extent is by no means uncommon in cases of albuminuric retinitis. A considerable number of hæmorrhages are found in the retina caused by pathological changes noticed in the walls of the bloodvessels. The condition of the retinal arteries in the class of cases we are considering, are similar to those noticed in the kidney, and other parts of the body, consisting of a thickening of all their coats, especially of the sub-endothelial layer of the interna. The diameter of the vessel is increased, while its lumen is diminished. There seems evidence leading to the inference, that the changes in the walls in the arteries precedes those in the stroma surrounding them. The optic nerve undergoes somewhat similar changes to those observed in the retina, although the alterations in its arteries are not so well marked.

Symptoms.—The appearances presented by examination with the ophthalmoscope will vary in different cases of nephritic retinitis, according to the part of the retina involved and the stage of the disease. In most cases the first changes observed, are clusters of small white spots in the substance of the retina near the macula, at first they are soft-edged and rounded, and as they get larger, they become irregular in form. These white spots generally appear round the macula lutea, arranged in a radiating manner; the larger spots can be distinctly seen, but the smaller ones are only to be recognized by careful direct examination; after a time they run into one another and form glistening white patches. Striated hæmorrhages are almost always present—"mares' tails," at other times they are linear, and not unfrequently the extravasations are more or less flask-shaped; when large they are irregular in form, and occupy the deeper layers of the retina. These changes may advance so as to involve a large part of the retina without symptoms of neuritis; but in most cases the margins of the papilla are blurred and swollen.

In other cases of nephritic retinitis we find from the commencement of the affection, that considerable swelling of the retina occurs, the papilla being completely obscured. The vessels, especially the arteries, are concealed in the swollen tissues. The veins are engorged and tortuous; large blotches and also striated hæmorrhages are present; numerous soft white patches are apparent; as the disease subsides evidence of atrophy in all the previously affected tissues are visible.

In the slighter forms of nephritic retinitis the patient's

vision is hardly affected. In serious cases impairment of sight without marked limitation of the field of vision or colour-blindness exists. Sight is rarely altogether lost. The course of this disease will vary according to the condition of the kidneys, but it is quite possible that extensive detachment of the retina may occur at any period. With the exception of detachment of the retina, it is not uncommon to see the other changes affected in the retina clear away for a time. The hæmorrhages and white spots may gradually fade away, generally to recur, however, before very long.

In cases of Bright's disease, it is hardly necessary to say that the retinal affection is as incurable as the principal malady, and no improvement can be looked for.

It is well to bear in mind the fact that disease of the brain may produce appearances in the retina similar to those of nephritic retinitis. For instance, a patient under our care, aged twenty-three, exhibited in both eyes the appearances which belong to the most complete picture of retinitis albuminurica, but she had no albumen or other evidence of kidney-trouble, and not until a short time before death had she any symptoms to cause suspicion of brain-disease. The autopsy disclosed a tumour in the region of the septum lucidum. In a second case, that of a girl aged fifteen, the ophthalmoscopic appearances were identical, but the patient suffered from Bright's disease, which caused her death, and allowed of microscopic examination of the retina and optic nerves.

The features common to both cases, in the ophthalmoscopic picture, were great swelling of both optic papillæ, redness and infiltration, its outline being indistinct and vessels swollen—in the case of tumour there was ecchymosis over the right papilla; near both discs opaque white patches, with dotted edges such as those seen in nephritic retinitis, were present; at the macula there were the usual radiating figures, and extravasations of blood in various places.

In the case of tumour, the ocular lesion was confined strictly to the eye—the optic nerve trunks, close up to the globes, possessed a normal structure as seen by the microscope. The lesions in the retina in both cases were extremely alike, making any distinction between the two by the microscope almost as impossible as by the ophthalmoscope. There were in both cases sclerosis of the fibres of the optic-nerve layer—the ganglion cells atrophied or sclerosed—the granular layers studded with or almost transformed into fat molecules—

hypertrophy of the connective tissue of the nerve and retina, and the choroidal tissues were somewhat sclerosed. The only difference in the two cases was that, in the patient with cerebral tumour, the swelling of the retina belonged more to hypertrophy of the inner retinal layers and papilla, while in the patient with Bright's disease the swelling affected principally the radiating fibres of the external granular layer.

The outcome of the matter is, that we cannot assert the infallibility of our diagnosis of Bright's disease with the ophthalmoscope. Many good observers have denied the possibility of mistake, but the retinal pictures may be completely simulated by neuro-retinitis from cerebral tumours, or from diabetes mellitus, malarial poisoning, and perhaps from alcohol.

We are therefore compelled to examine the urine as well as the eye, and to study the signs of cerebral disturbance, however obscure they may be in some cases. But it remains true that the retinal lesions above described belong in the large majority of instances to Bright's disease.

Albuminuric Retinitis of Pregnancy.—It is a remarkable fact that in some cases of pregnancy attended with albuminuria, the patient suffers from almost complete loss of sight, and presents all those ophthalmoscopic appearances which have been described in previous sections as characteristic of nephritic retinitis. There is, however, an important clinical difference between the retinitis of Bright's disease, and that of pregnancy; in the former the impairment of vision is progressive from bad to worse, but in the latter affection, if premature labour is brought on, or the child is born within a few weeks of the appearance of albumen in the urine, the patient's vision improves, and as in the following case may be completely restored. This patient was under the care of Dr. B. Potter, of the Westminster Hospital; she was a healthy young person, and within a few months of her marriage became pregnant; up to the third month she appeared to be doing well, but then observed great swelling of the labia, and a considerable quantity of albumen was found in her urine. Within a week or two she was seized with violent convulsions; Dr. Potter, therefore, brought on labour, after which the albumen ceased to be passed in her urine, and she speedily regained her health. Some eighteen months after this the patient again became pregnant, and in the fourth month gradually lost her sight so that she could only count fingers held up before her face; albumen was found in considerable

quantities in her urine, and on examining the eyes we found well-marked appearances of albuminuric neuro-retinitis. Dr. Potter, a second time brought on a premature confinement; after this albumen ceased to be passed, and the patient's sight improved; she now, some three years after the last attack, sees $\frac{6}{6}$, and Snellen No. 1.; the retinae have almost completely cleared, small white patches only remaining near the macula in both eyes. In a case of this kind it would be unnecessary to bring on a premature labour if the retinitis had manifested itself about the seventh or eighth month; but the retinitis will not subside until after child-birth, and it cannot be allowed to continue for several months without running the risk of destroying the delicate nerve structures involved, and so premature labour must be brought on. Mr. Loring, of New York, has described a case in which each of three pregnancies was accompanied with failure of sight, the first two in the outer half of the field of vision; the last in the outer half of each, with general impairment of vision.

Retinitis in Diabetes Mellitus.—Affections of the fundus oculi, recognizable with the ophthalmoscope, are in cases of diabetes of rare occurrence; cataract is frequently met with in this disease. There can, however, be no question as to the fact that persons suffering from diabetes, especially in its later stages, occasionally experience dimness of vision, and it may be great impairment of sight in consequence of retinitis, which in appearance much resembles that seen in albuminuria. In these cases hæmorrhages are conspicuous in the deeper layers of the retina; and the blood passing forwards produces opacities in the vitreous, white patches of an irregular shape are also seen in the retina, sometimes surrounding the macula as in albuminuric retinitis. It appears that the vessels of the retina pass through peculiar changes in cases of this description, they not only undergo hyaloid degeneration, but the capillaries present numerous pouches, or aneurisms as they are called. These changes in the vessels account for the hæmorrhages which are so constantly found in cases of diabetic retinitis.

RETINITIS PIGMENTOSA is an exceedingly chronic disease affecting both eyes; it commences in early life and gradually progresses to almost, or complete blindness. It consists of a slow inflammatory and degenerative change, commencing in

the epithelial layer of the retina, and involving the adjacent tissue of that membrane as well as the choroid, leading to sclerosis and atrophy of the retina, with secondary atrophy of the optic disc. The pigment set free from the epithelium proliferates and passes forward into the retina, where it may be seen with the ophthalmoscope, resembling in shape large bone corpuscles as seen under the microscope; when the spots are close together the appearance is something like black lace, the pigment is usually found in front of the retinal vessels, proving that it has reached the anterior part of that membrane. Dr. A. Alt remarks that during the progress of this disease the pigmented cells frequently enter into and extend along the peri-vascular sheath of the retinal bloodvessels; nevertheless the primary disease is not one of the vessels as has been stated by some authors. The disease commences in the peripheral part of the retina, usually affecting a complete zone round the optic disc, approaching nearer to it on the nasal side than on the temporal; beyond this zone the retina may be fairly healthy, the defect in the field of vision taking the form of a ring scotoma. As the retinal epithelium undergoes destruction, the deeper layers of the choroid come into view; in some cases the whole of the vessels of the deep layer are extremely distinct and give it the most characteristic appearance. Some syphilitic cases of choroido-retinitis, are not to be distinguished from retinitis pigmentosa except by their history.

The amount of pigment does not necessarily bear much relation to the loss of vision; some patients with very little pigment in the retina see very badly, while others with a large amount of retinal pigmentation see better than might be expected.

Retinitis pigmentosa is said to be most commonly met with, among the offspring of persons nearly related to one another; but this can hardly be the cause of the disease among the natives of India, as they are scrupulous in observing the restrictions they place upon the intermarriage of relatives; and yet we have seen a considerable number of instances of this disease among native patients. It is common to find this affection in several members of the same family.

Symptoms.—As we have before stated, although retinitis pigmentosa is a disease which commences in early life, it may long escape notice. It runs its course, in fact, without the

slightest pain, and the external appearance of the affected eye is probably healthy. The symptom first complained of is a gradual loss of sight, most marked after sunset, or when the patient is subjected to a dim light. The central portion of the retina may continue unaffected after its outer parts have been destroyed; direct vision, therefore, remains comparatively good, while objects immediately around the central portion of the visual field are hazy, or even imperceptible. For this reason a patient suffering from this malady may be able to read small type, but cannot walk about with safety in a crowded thoroughfare. The colour vision usually remains unaffected. As the disease progresses the field of vision steadily contracts, and ultimately the patient's sight is almost lost. Notwithstanding this, until an advanced stage of retinitis pigmentosa the pupil, though contracted, responds to the stimulus of light. Opacity of the vitreous is rare in this disease, but the lens is more often affected, and then, usually, at its posterior pole.

On examining the eye with the ophthalmoscope in the early stages of the disease, the optic disc and retinal vessels are of normal size; towards the ora serrata irregular patches of black colouring matter may be noticed, having the characteristic retinal appearance. These patches grow from the epithelial layer and extend into the retina, spreading along the walls of the vessels.

With the further progress of the disease, the black irregular pigment spots continue to increase in the retina, spreading gradually from the periphery to the axis of the eye; the retinal vessels become mere streaks, and ultimately, when the patient has nearly lost his sight, the eye presents the following appearances:—Optic disc of normal size, and of a pale rose colour, looking flat, with no choroidal margin to be seen; the retinal vessels have dwindled away to mere threads, extending, probably, only a short distance beyond the margin of the disc; the fundus of the eye has a mottled appearance, and a number of black, spider-shaped bodies are scattered over it; these are particularly distinct towards the ora serrata.

Prognosis.—We do not remember to have met with a case, in which a person, under forty years of age, has been rendered completely blind from the effects of this form of disease. It usually takes years to advance from the stage characterized by the symptoms of hemeralopia to that of

general impairment of vision ; but its progress, though slow, is sure. We have tried every means to stop it, but have never succeeded in doing so, the increase of the pigment in the retina continuing in spite of our best efforts. We must, therefore, give an unfavourable prognosis to patients suffering from retinitis pigmentosa ; but we may console them with the fact that its development will be slow, and may possibly be arrested for several years at any stage ; but no reasonable hope can be entertained of improvement.

HÆMORRHAGE INTO THE RETINA.—Effusions of blood into the retina are of frequent occurrence, and have been observed after injuries through concussion, or direct wounds ; or in the course of those changes which tend to impede the passage of blood through the optic disc (as glaucoma, inflammation of the papilla, and the adjoining retina), or through the orbit, especially when the cause is situated close behind the eyeball, or at the *fissura orbitalis superior*. A condition favouring hæmorrhage, and connected with diminished power of the vascular walls, is that of hypertrophy of the left ventricle, or insufficiency of the aortic valves. It is frequently met with in Bright's disease, diabetes, anæmia during pregnancy, and in women weakened by lactation. Sudden closure of the jugular veins on both sides has occasioned hæmorrhage into the retina, or effusion of blood may occur in the course of changes within the eye (as tumours, retinitis), which give rise to hyperæmia of the retina and choroid, with atrophy. Hæmorrhages into the retina vary much in size, number and position. They may be very small, or three or four times the diameter of the optic disc. There may be one or numerous extravasations covering the fundus. Their shape and aspect depends much on their position in the substance of the retina.

It is hardly possible to mistake extravasated blood in the retina for any other condition of the parts. If examined soon after the hæmorrhage has occurred, its colour is quite characteristic ; subsequently this alters, and the hæmorrhagic effusions become darker, and are broken up into small patches. The larger extravasations may gradually soften down, and are converted into a yellowish fatty substance, which may ultimately become absorbed ; but in many instances the hæmorrhage destroys the elements of the retina into which it has occurred. A circumscribed retinitis

follows, leading to a cicatrix and blind spot; if the clot formed is large, to detachment of the retina.

We frequently meet with cases of hæmorrhage in the retina unconnected with neuritis or any objective symptoms. These extravasations may be divided into three principal groups. First, effusions of blood, in which the hæmorrhage assumes a flammiform appearance, following the course of the nerve fibres. These hæmorrhages generally disappear rapidly; they are similar to those seen in cases of scurvy and petechial typhus.

Secondly, hæmorrhages take place from the retinal vessels, and passing backwards, the blood causes a certain extent of detachment of the nerve layer from the choroid. A clot formed in this situation is apt to coagulate, its colouring matter sinks down to the most dependent part, the serum remaining fluid above, and the extravasation presents various shades of colour. Hæmorrhages of this kind seldom disappear without leaving some trace of their existence, either in the shape of disturbed pigment, detached or otherwise damaged retina, and if these changes have occurred in the axis of vision, the patient's sight may be permanently impaired.

A third variety of hæmorrhage is that met with usually among patients advanced in life; the extravasation occurs from a vessel of the papilla. We have a case of the kind now under treatment. This old lady is in good health, and the only point in her history at all bearing on her present condition is, that formerly she suffered rather frequently from epistaxis. Some ten days before we saw her she discovered that she had lost the sight of her left eye. We found that, extending from the edge of the papilla as far as the macula lutea, there was a clot of blood; neither the arteries nor veins were perceptibly altered in size; there were no other hæmorrhages. In the course of time the hæmorrhage extended, the vitreous had become full of opaque flakes, and the patient's sight was destroyed. In cases of this kind the extravasated blood may become absorbed, but it too often happens that repeated hæmorrhages occur, and the eye is lost.

There is another class of cases described by Mr. H. Eales, of Birmingham, as "Primary Retinal Hæmorrhage in Young Men." He remarks that the hæmorrhages are usually multiple, often cause complete opacity of the vitreous, and

when quite recent are of a venous colour. Though occurring at all parts of the fundus, they are most common at the extreme periphery of the retina. They are not associated with any evidences of retinal disease, and are roundish, diffused, and not fan-shaped. They constantly recur; they are generally found in close proximity to the branches of the retinal vein, which are often lost in them, or a venous trunk is directly continuous with an opacity in the vitreous caused by the hæmorrhages, the calibre of the retinal vessels are unusually large in both eyes, the veins especially being dark, large, and tortuous. Vision often appears to be impaired only in proportion to the opacity of the vitreous; in some cases, the recovery is so complete that between the attacks no trace of the previous disease is found.

The patients are young males, the youngest of Dr. Eales' patients being aged fourteen, and the eldest aged twenty. All were previously, and while under treatment, troubled constantly with constipation, and occasionally with epistaxis, especially during the summer months. Two were very subject to headaches, three were habitually lethargic and indolent, and complained of depressing feelings and want of energy. In one case, there was evidence of mitral incompetence. In the others, the heart presented no anomaly. The pulse, in each case, was below 60 at the time they first came under observation. The aortic second sound was accentuated in only one case. Pulse-tracings in three cases showed low tension, but they were taken some months after the hæmorrhages occurred; the condition of pulse-tension at the time of the hæmorrhage is therefore still undetermined. In two cases only there was the faintest shadow of albumen in the urine, and in no case were any casts found. It is necessary always to be careful, in cases of sudden loss of sight in the central field of vision, to look to the condition of the macula lutea. We have seen more than once extravasation of blood limited to this spot.

In other cases, described as *Betinitis Apoplectica*, we find that, together with œdema of the optic papilla and retina, numerous ill-defined spots of hæmorrhage are observed. The veins of the retina are dilated, the arteries often of their normal size, but the extravasations of blood are very characteristic. At times the effused blood forces its way into the vitreous chamber, but more often towards the choroid. The clots of blood retain their colour for a considerable time,

and may then gradually become absorbed, but bear a marked tendency to recur. The loss of sight depending on extravasation of blood of this kind, depends much on the locality in which they have formed, but the prognosis in these cases is always serious. This affection generally occurs together with disturbance of the general circulation, due to affections of the heart, liver, or uterus, including pregnancy. Atheromatous degeneration of the coats of the retinal bloodvessels is, however, the most frequent cause of hæmorrhages of this description.

AFFECTIONS OF RETINA IN DISEASE OF THE HEART.—Impairment of sight, depending on disease of the heart, is not of frequent occurrence; transient failure of sight without ophthalmoscopic change is common in heart disease, and may be unilateral and considerable.

1. *Capillary Congestions of the Retina and Venous Varicosities.*—Sometimes there are venous stases in the retina from over-distension of the right heart, but their progress is slow and gradual, so that vision is in no way troubled. It is only in exceptional cases that the venous congestion occasions disorders of vision, either constant or periodical; but then we have no longer simple varices in the principal branches, but capillary congestion of the retina more or less marked.

The venous stases of the retina are to be sought for especially in the capillary branches. An ophthalmoscopic examination with inverted images is not sufficient to make out this capillary stasis; we must have an erect image and a strong magnifying power.

2. *Extravasation of Blood into the Retina and Optic Nerves.*—In heart disease effusions into the retina take place both from the over-powerful impulse of a hypertrophied heart, or what is more common, from the insufficient impulse of the same organ when enfeebled. The rupture of the capillaries is sometimes prepared for by an alteration in the coats of the vessels. Generally only one or two branches are ruptured, and a single eye affected. In effusions of blood into both eyeballs we ought to suspect the presence of albuminuria or diabetes, &c.

EMBOLISM OF THE CENTRAL ARTERY OF THE RETINA.—Embolism of the central artery of the retina occurs usually in people with disease of the heart, the embolus being a detach-

ment from one of the aortic valves, it is recognized by well-defined symptoms. The patient complains of sudden loss of sight in the affected eye. On ophthalmoscopic examination we find that the optic disc is white, and its vessels greatly attenuated. The retinal arteries are recognized as narrow threads, often appearing as white lines. The retinal veins are small and the column of blood in them may be sometimes seen broken up into segments, moving backwards and forwards in jerks; the fundus has a greyish white opaque appearance from œdema of the retina; this is most marked around the region of the macula, but at the macula itself there is no connective tissue, therefore œdema does not take place. Here the normal red of the choroid shows through, the red appearance being intensified by the whiteness of the surrounding parts; this condition is absolutely characteristic, and is often described as the "cherry-red spot of embolism of the retinal artery." The œdema usually surrounds the optic disc, causing considerable blurring of its margin; one or two hæmorrhages are often present. As the effusion clears away, the cherry-coloured spot disappears, the fundus resumes its ordinary colour, the branches of the retinal artery remain very small, some of them being completely obliterated and appear as white lines, and the disc passes into a condition of atrophy. After a time further changes may occur in the eye, the vitreous becoming hazy, the retina and optic disc gradually passing into a condition of complete atrophy.

In some cases an embolus is driven into one of the branches of the retinal artery, and œdema of the nerve structure around it occurs, causing limited impairment of vision, which is confined to that part of the retina supplied by the occluded vessel. The remainder of the field of vision may be normal.

In cases of embolism of the central artery of the retina the prognosis is unfavourable, so far as the diseased eye is concerned. But embolism of the central artery of one eye does not in any way prejudice the other, which may remain perfectly healthy. So that although the loss of sight in one eye is complete, vision in the other eye may continue unaffected for the remainder of the patient's life.

If the case be seen very early the patient may be given an inhalation of nitrite of amyl, in the hope that by relaxing the arteries, the embolus may be driven on from the main

trunk into one of the branches, and so, possibly, save the sight in the other part of the field of vision.

DETACHMENT OF THE RETINA from the choroid is frequently met with, and may be caused by a blow on the eye or by disease, such as high myopia, the effusion of fluid between the retina and the choroid, or a new growth from the choroid.

Detachment from a blow is not very common and occurs more often in myopia; the following case may be given:—The patient had been struck with a racquet ball on the left eye; immediately after receiving the blow he found he had completely lost the sight of the eye. When we first saw this gentleman the pupil was widely dilated; he could only distinguish large objects in certain directions, the injury evidently being in the axis of vision. On examining the eye with the ophthalmoscope, a considerable portion of the retina, extending from the optic disc outwards and downwards was found to be detached, and below this a clot of blood could be seen, over which the retina appeared to hang. The fundus of the eye was intensely congested, as well as the optic disc, and there were several spots of extravasated blood scattered over the retina.

The patient was recommended to keep the injured eye closed and to rest the other one as much as possible. In a month's time his sight had improved, and the congestion and extravasation of blood had almost disappeared; a considerable portion of the large clot noticed in the lower part of the eye had also become absorbed, but the appearance of the detached retina in the axis of vision remained unchanged.

It occasionally happens that the whole of the retina is dragged away from the choroid and assumes a funnel-shaped form, the apex being at its point of attachment to the optic disc. The vitreous, however, must have passed into a fluid condition, to allow of the retina falling forwards in this way.

Detachment of the Retina from Effusion.—Separation of the retina from the choroid, the result of a collection of fluid behind the former structure, is not necessarily accompanied by pain in the eye; but this symptom will, of course, vary with the nature of the cause which has given rise to the effusion. The patient probably complains only of gradually

increasing imperfection of sight; and as only a portion of the retina is usually detached, the field of vision is more interrupted than absolutely destroyed; so that in looking at an object immediately in front of him the patient will lose perhaps half the figure, the rays which fall on the detached portion of the retina not being recognized, and for the same reason objects appear to be bent, or their outlines distorted in various ways. In other cases the patient first notices that the field of vision is cloudy, the cloud having a wavy motion, due to changes of position of the retinal elements which receive and localise the impression of light. Vision is not only distorted but objects under examination are fringed with a coloured ring or halo. If the retina is detached at or near the macula lutea, the impairment of vision will, of course, be far greater than if a more extensive detachment exists at its periphery; but even then, in certain directions, the visual field may still remain tolerably perfect. Under any circumstances the patient complains of coloured or white balls, fiery wheels, flashes of light, and such like phenomena due to excitability of the visual organ.

Detachment of the Retina from Staphyloma and fluid Vitreous.

—Besides detachment of the retina brought about by blows on the eye, and serous effusion between it and the choroid, other causes may produce a similar result. We mentioned one of these when discussing the subject of sclero-choroiditis anterior, observing that, as the sclerotic gradually yielded to the intra-ocular pressure, the choroid being gradually drawn into the staphyloma, may drag the retina after it, thus detaching it from its normal position. A similar result occurs at times in posterior staphyloma, but in this last affection, in addition to the mechanical effects produced by the protrusion backwards of the sclerotic, there is a tendency to general congestion of the choroid, and a fluid state of the vitreous which may itself lead to detachment of the retina.

A like alteration in the consistency of the vitreous, has been known occasionally to follow severe contusion of the eye, and such an accident may therefore give rise to detachment of the retina. Under these circumstances the alteration in the consistency of the vitreous appears to progress with remarkable slowness, so that the fact of the injury may be almost forgotten, but symptoms of gradual impairment of sight and floating bodies in the field of vision attract the

patient's notice, and we find on examining the eye that a fluid state of the vitreous exists with detachment of the retina.

Detachment from a Tumour is usually due to a sarcoma of the choroid growing into the vitreous, and pushing the retina before it; in an early stage it may be difficult to distinguish it from a detachment caused by effusion. As the growth advances it may become somewhat lobulated, the tension of the eye increases, vessels may be seen coursing over it, and sometimes a hæmorrhage may be detected on the growth. The only treatment is early removal of the eye.

Diagnosis.—Detachment of the retina is usually easily detected with the ophthalmoscope. It presents a bluish-grey, floating, wave-like opacity, which is thrown into folds with every movement of the eye; the retinal vessels may be traced up to the margin of the detached portion, where they will be seen to terminate abruptly, or bend back, at the point at which the retina deviates from the plane of the fundus of the eye. The jagged wound in the retina can sometimes be seen with its edges turned in towards the vitreous. When, as occasionally happens, the detachment is small and the retina retains its transparency, the diagnosis is by no means so easy, especially if the vitreous is rendered hazy by floating opacities; here the diagnosis must rest upon the appearance of the vessels, and the variations in refraction of different parts of the fundus; with the direct examination, the vessels on the detached portion of the retina look smaller and more tortuous than those of the other parts, and appear much darker, besides moving with any sudden movement of the eye. The vessels appear darker because they are seen partly by transmitted light, the light returning from the choroid being more or less intercepted by them. The other point, which is of great importance is, that the refraction of one part will be very hypermetropic, whereas the rest of the fundus is emmetropic or myopic, the highest convex glass behind the ophthalmoscope, with which the details of the detached portion can be seen will give us the degree of the detachment, as every 3D represents 1 mm. The fields of vision should be taken with the perimeter as a confirmation of the diagnosis, and as a permanent record of the state of the fields.

When the detachment is very large, it may be seen with focal illumination bulging forward into the vitreous chamber

like a small bladder, its surface relaxed and folded, trembling with every movement of the eye. Though the detached portion of the retina may in the first instance be transparent it usually soon becomes opaque; by degrees, however, the retina undergoes degeneration, and the opacity may extend rather beyond the border of the actual line of the detachment.

Pathology.—It has always been difficult to understand how a simple detachment of the retina takes place, especially when it occurs suddenly and without any increase in the intra ocular tension, but recent observers have thrown considerable light on the subject. It is probable that in all cases there must either be consolidation and shrinking of the vitreous, leading possibly to a separation of this substance from the tunics of the eyeball, or that the capacity of the globe must be increased, as in the case of myopia. The probable explanation is, that as fresh vitreous is never secreted, any increase in the capacity of the globe must necessarily be filled up by the effusion of serum or some other fluid; this serum may become incorporated with the vitreous leading to abnormal fluidity, or the fluid may be effused between the vitreous and retina, then the retina undergoing softening is liable to be torn, and so the fluid getting between it and the choroid causes the detachment.

Separation takes place between the layer of rods and cones and the epithelial layer, the latter remaining attached to the choroid.

Detachment of the retina is usually noticed at its lower part; this fact is explained by supposing that the fluid behind it gravitates downwards, and accumulating in the inferior portion of the retina producing this appearance. Occasionally this fluid contains blood or pus, which will, of course, alter the apparent colour of the detachment. Particles of lime and small plates of bone have been found lining the inner surface of a detached portion of the retina.

Prognosis.—The prognosis of these cases of detachment of the retina is unfavourable; some few cases remain stationary, others have been said to recover; but, so far as our experience goes, the effusion behind the retina increases sooner or later, and leads to loss of sight in the affected eye.

Treatment.—Loss of sight must be the result of an accumulating effusion behind the retina, and its separation from the choroid, unless the surgeon can afford some relief to

his patient. This may be done, as has been proved by Von Graefe and Sir W. Bowman. Their mode of treatment is to pass two needles from without through the sclerotic into the effusion, so as to let the fluid escape into the vitreous, or externally into the choroid. Successful cases of the kind are authenticated.

Before adopting this measure, however, in any particular case, it is necessary to determine whether the retina is comparatively healthy, so as to lead us to hope, in case the effused fluid is got rid of, and the retina restored to its normal position, that our patient will gain some advantage from the operation. We may judge of this pretty accurately by the appearance of the retina; if it looks dull and opaque it is more than probable that its nervous elements have degenerated, and in that case it will be of little use interfering.

Our intention in operating should be to make a free opening for the effusion, so as to allow it to escape into the vitreous chamber; the retina will then fall back into its normal position, and, unless structurally altered, its functions may be restored and the patient regain almost perfect vision. The plan Sir W. Bowman recommends, appears to be the best adapted for this purpose:—The site of the separation of the retina having been carefully studied with the ophthalmoscope, the patient is placed on a couch; and a stop speculum having been introduced to keep the lids apart, the surgeon passes a needle through the sclerotic vertically into the eye, transfixing the retina at its point of separation from the choroid; another needle is then inserted through the same opening, and the handles of the two being separated the one from the other, their points are made to diverge like the blades of a pair of scissors. In this way the retina is torn through, and the fluid behind it escapes into the vitreous chamber; usually a small quantity passes out along the needles, and exudes beneath the conjunctiva; but this is not always the case. After the operation the retina falls back into apposition with the elastic lamina.

In these cases the chief point to attend to is to avoid wounding the lens; but an ordinary amount of anatomical knowledge and skill will prevent this accident; and if we do not touch the lens, we may be sure that no injury will result from passing the needle into the vitreous, even if we do not succeed in effecting a cure. After the operation the only

necessary treatment will be to keep the eye closed for a few days with a pad and bandage. As before stated we have operated in this manner a considerable number of times, the proceeding being followed by temporary relief, but never by anything more favourable.

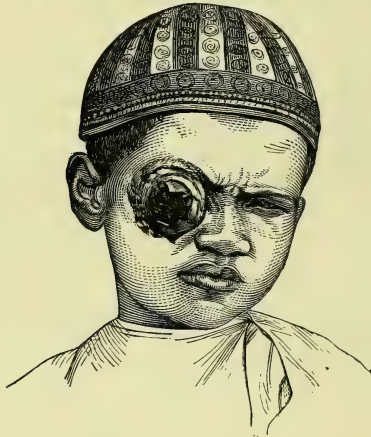OPAQUE NERVE-FIBRES.—We occasionally meet with cases in which the medullary sheath of the nerve-fibres, in place of terminating at the cribriform fascia, are prolonged into the retina. Wherever fibres of this kind exist in the retina, they appear, when examined by the ophthalmoscope, as white glistening streaks or patches, according to their number and position. A condition of this kind is a congenital peculiarity, which may affect the whole circumference of the papilla and retina surrounding it, but more commonly appears in patches extending from the papilla over various parts of the retina. But whatever the form or extent of the opaque nerve-fibres, the area they occupy, especially when seen by the direct method, appears of a pure white colour, the margin of the patch presenting a finely striated appearance, somewhat resembling carded cotton wool. The retinal vessels are sometimes partly buried in the opaque fibres; occasionally they pass over its surface. Patches of this kind may be seen in one or both eyes. We have met with cases of opaque fibres complicated with optic neuritis and choroiditis, but they occur without evidence of any other abnormal condition of the fundus of the eye. The patient's sight is imperfect over that portion of the retina covered by the opaque fibres.

TUMOURS OF THE RETINA: MEDULLARY SARCOMA (GLIOMA).
—This form of sarcoma is most frequently met with among infants and young people. It originates in the connective tissue of the retina. These tumours consist of round cells, about the size of pus globules, embedded in a small quantity of granular intercellular substance. The tumour is usually very vascular. As the morbid growth increases in size, the retina is detached, and the tumour advances into the vitreous chamber. During its growth hæmorrhages frequently take place, and we find patches of blood in the tumour. It is not uncommon to see softened areas in the morbid growth. These sarcomata spread continuously, so that the whole of the retina and the optic disc, in the course of a short time,

are occupied by the new growth, which, if not removed, extends along the optic nerve to the brain; the anterior chamber becomes diminished, the intra-ocular pressure is increased, abscess of the cornea follows, and the sarcoma protrudes outwards.

A., aged six years, was brought to the Ophthalmic Hospital, and presented the following conditions:—General health good; the pupil of the right eye widely dilated, and a yellow reflection from the fundus could be seen, evidently proceeding from a morbid growth which projected into the vitreous chamber.

FIG. 48A.



The removal of the eye was advised, but as the parents would not consent, the child was removed from the hospital. Twelve months afterwards they again brought him, and the right eye then presented the appearance delineated in Fig. 48A. The child's health had fallen off, but the glands of his neck were not enlarged. The eyelids were greatly distended, and a fungating tumour was seen growing from the eyeball and protruding between the eyelids. Its surface was ulcerated, and bled when touched, but was usually covered with a crust of dried blood and matter. We at once removed the morbid growth, and on passing the finger behind the tumour

the optic nerve was felt to be much enlarged; it was therefore divided as near the optic foramen as possible, and then the solid chloride of zinc applied to the bottom and sides of the wound. The child made a rapid recovery and appears to have remained perfectly free from the disease. The tumour, on examination, was found to be a glioma.

We not unfrequently have the opportunity of watching the growth of a tumour of this kind; and may then see through the dilated pupil a glistening yellowish-white reflection from the back of the eye. The ophthalmoscope enables us to complete the diagnosis, and, if employed sufficiently early, demonstrates the fact of the morbid growth being limited to one part of the retina, giving it a thickened and mottled appearance. Subsequently, as the disease involves the whole of the retina, the eye assumes the appearance formerly known as the "amaurotic cat's-eye." The morbid growth advances towards the lens, the globe of the eye enlarges, and ultimately the tumour bursts through the cornea, and assumes the fungoid appearance depicted in Fig. 48. There can be no question as to the necessity of excising the eyeball, and with it the morbid growth, in cases of this form of disease. The operation should be performed so soon as the presence of the sarcoma has been diagnosed; any delay may be attended with the most serious consequences.

Pseudo-glioma might be mistaken for glioma; the subject will be found referred to on page 245.

CHAPTER XIII.

*Colour Blindness—Idiopathic Night Blindness or Hemeralopia
—Snow Blindness—Lightning Blindness—Hemiopia
—Scotoma—Amaurosis and Amblyopia—Micropsia—Ery-
thropsia.*

COLOUR BLINDNESS.—Before considering the defects of colour vision, some attention should be paid to the perception of colour in the normal eye.

The phenomena of light may be explained by the hypothesis that they are produced by wave motion. Sound waves are transmitted by air, but light will travel through space unoccupied by air or any other medium we are able to detect; hence the theory that there exists everywhere a medium able to transmit light vibrations; this medium we call *the ether*. We see a light because the ether surrounding it has been thrown into a state of vibration; this moving layer sets in motion the next, and so on till some of the vibrations reach the retina, to be there received by the terminals of that membrane, where certain molecular changes take place, and the stimulation so produced must be conducted by the optic nerve to the brain for its proper interpretation.

The vibrations of the ether vary much in wave length and in rapidity; when falling on the retina they produce the sensation of different colours. Every colour has a wave length and rapidity of vibration peculiar to itself.

A ray of light falling on a prism made of glass suffers dispersion, *i.e.*, it is broken up into its constituent parts, the series of colours thus produced is called a spectrum; the largest wave which can be perceived by the retina produces the sensation of *red*, the smallest waves, the sensation of *violet*.

Besides these colours of the spectrum, there are other waves at each end; those at the red end are of still greater

height, and are called heat rays, while those at the violet end of the spectrum are smaller waves called chemical rays.

The colours of the solar spectrum then are red, orange, yellow, green, blue, violet. Sunlight consists roughly of the following parts:—

Red	194
Orange	80
Yellow	374
Green	255
Blue	72
Violet.. .. .	25
	<hr/>
	1000
	<hr/> <hr/>

The colours of the spectrum can be recombined as coloured lights so as to form white. Maxwell combined them by painting segments of a disc with the proper proportions of the colours, and then spinning the disc rapidly, the result being the sensation of white.

It is not necessary, however, to combine all the colours of the spectrum to produce white. This can be obtained by combining red, green, and violet; hence these three colours are called *primary* or *fundamental*; as white can be obtained by mixing these three, it follows that to each of these corresponds a colour, the addition of which is necessary to form white, therefore each has a colour which may be called *complementary*, thus the complement of red is a combination of the other two primary colours green and violet—bluish green; the complementary colour of green is a combination of red and green—purple; and that of violet is a combination of red and green—a yellowish green. The importance of these facts will be more apparent when we come to consider the theories of colour blindness, on which our knowledge of colour vision is based.

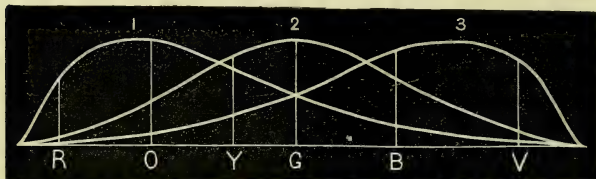
The first case of colour blindness was recorded in 1777, but no proper division was attempted till 1850. In 1800 Dr. Thomas Young propounded a theory to explain colour perception, which remained almost unnoticed till fifty years later, when it was taken up and slightly modified by Helmholtz, who considered that it explained nearly all the phenomena of colour vision and its defects; this is now called the Young-Helmholtz theory.

This theory is based on the three primary colours, and on the supposition that there exists in the retina three kinds of nerve fibres corresponding to these colours; stimulation of the first set of nerve fibres produces the sensation of red, of the second set the sensation of green, and of the third set, violet; stimulation of the three sets of fibres equally produces white.

Had this theory been conceived later, probably colour vision would have been referred not to the retina but to the brain. Stimulation of the retinal elements (possibly the cones) take place as the result of the ether vibrations, but this must be conducted to the particular nerve centre for a proper interpretation to take place, hence the retina and optic nerves may be looked upon as receivers and transmitters only.

In Fig. 49 the colours of the spectrum are arranged in a horizontal row, while the three curves represent the intensity

FIG. 49.



of stimulation of the three kinds of fibres, red (1), green (2), violet (3). Red stimulates chiefly the red perceptive fibres and less the other two; resulting sensation, red. Yellow stimulates moderately the red and green fibres, feebly the violet; sensation, yellow. Green stimulates strongly the green fibres, slightly the red and violet, producing the sensation of green. Blue acts moderately on the green and violet, and feebly on the red; sensation, blue. Violet stimulates strongly the violet and slightly the red and green; result, violet. Equal stimulation of all the fibres produces the sensation of white.

Thus it will be seen that no colour is absolutely pure, since each set of fibres is slightly stimulated by even one of the primary colours, hence we say that no one colour is perfectly saturated, but is partly diluted with white. Additional support is given to this theory by the well-known

experiment, that if a bright colour be gazed at intently for a minute or so, and then the eye be turned towards a white object, an after image will be seen, the colour of which will be complementary to that looked at, that colour, in fact, which, added to the colour looked at, would produce white.

Herring's Theory.—This theory assumes colour vision to be a photo-chemical process, based on the hypothesis that the rhodopsin or visual purple is composed of three distinct parts which are acted on chemically by different colours. Herring considers that one colour acts by decomposition of one of these parts, while the opposite colour takes an active part in building it up again, and he therefore named the colours accordingly, *dissimilation* and *assimilation*; thus of red and green, red would be the dissimilation colour and green the assimilation. One great objection to this theory is that at the macula, where colour vision is most acute, rhodopsin is absent.

Colour Blindness may be either acquired or congenital. The *acquired* form occurs in many morbid conditions of the retina and optic nerve, as well as in cases of toxic amblyopia where the loss of colour vision occurs as a central scotoma; this variety need not be further referred to now, it will be found discussed under the particular diseases in which it occurs.

The *congenital* form is that which now chiefly concerns us; it is found in about three per cent. of males and two per cent. of females; many cases are hereditary. Cases have often been recorded where the defect has been transmitted through several generations.

Congenital colour blindness may be divided into—

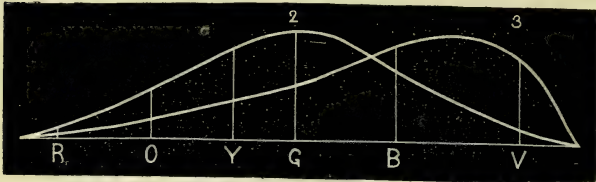
1. Total colour blindness or achromatopsia, in which there is absolutely no colour vision beyond the capability to distinguish between light and dark. This variety is very rare and need not be further mentioned.
2. Partial colour blindness—
 - (a) Complete blindness for one of the primary colours.
 - (α) Complete red blindness.
 - (β) Complete green blindness.
 - (γ) Complete violet blindness.
 - (b) Incomplete colour blindness, in which there is a feeble chromatic sense.

Complete blindness for one of the primary colours requires further consideration. Red blindness is the variety most

frequently met with, while violet blindness is extremely rare.

1. Red blindness as considered by the Young-Helmholtz theory renders it necessary to draw a scheme as Fig. 50, leaving out the curve No. 1. Here the red perceptive curve

FIG. 50.



is absent, only the fundamental colours green and violet being represented, it is obvious that the absence of one of the three primary colours must alter the whole chromatic system. Hence in the case under consideration red will slightly excite the perceptive elements of green and scarcely at all the violet, therefore the sensation of green of low saturation is produced. Yellow will appear as a green, while green will appear as a more intense shade of yellow. White of the red blind consists only of a combination of their two primitive colours and will appear of a bluish grey.

2. Green blindness (Fig. 51) is due to the absence of curve

FIG. 51.



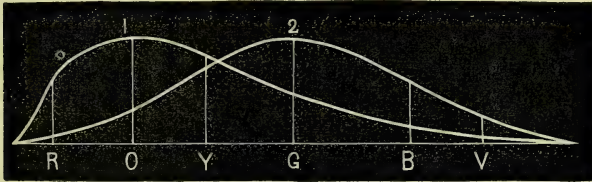
2, which represents the perceptive elements of green; the fundamental colours are red and violet. Bright red stimulates strongly the red element and but slightly those of violet, and will therefore appear as a very saturated red, but more luminous than it would seem to the normal eye. Green

being composed of about equal parts of the two primary colours, will be a whitish grey, the blue an intense violet.

3. Violet blindness (Fig. 52), is due to the absence of the perceptive elements of violet. Bright red will appear as a purer red than to the normal eye; yellow will seem to be grey, due to stimulation of the two fundamental colours about equally. Green is a luminous but whitish green tending to blue, blue is a green strongly saturated, and violet a feebly luminous but saturated green.

Test for Colour Vision.—Holmgren's wool test is easy of application, can be carried out quickly, and is very reliable. It might appear that the best test would be to show the person examined a lantern fitted with different coloured slides, or coloured flags such as are used on the railways, but this is far from being the case, for it is essential that any test

FIG. 52.



should be quite independent of the names of the colours employed. Holmgren's wool test consists of a selection of Berlin wools of various shades—red, orange, yellow, blue, green, violet, pink, brown, grey; these should be spread out on a white table-cloth in good daylight. TEST I, a light but pure green is first taken up and given to the examinee, who is told to pick from the heap, those colours which seem to him to be lighter or darker shades of the same colour. Should the person examined fail to understand what is required of him, there is no objection to the examiner going through the test himself, then mixing the skeins and allowing the examinee to proceed; should he succeed in picking out correctly all the skeins without including any of the confusion colours, then he may be assumed to have a normal colour sense; on the contrary, if he hesitates and shows a tendency to take one or more of the confusion colours, though

eventually rejecting them, he may be assumed to have a weak chromatic sense.

A light green was selected for this test because green is the whitest of the colours of the spectrum and therefore most easily confused with grey. This test separates the colour blind from the normal, but does not tell us the nature of the defect; to enable us to know the kind of colour blindness we must pass on to Test II.

TEST II. A purple skein of medium shade is chosen, and the examinee proceeds to match with it skeins of the same shade; should he select only purple shades although he failed in Test I, he may be put down as incompletely colour blind, but the person who selects with purple, blue or violet, or one of these is *red blind*. Should, however, green or grey be matched with the purple, the examinee may be put down as *green blind*.

TEST III. Is simply a confirmatory test; for this a bright red skein is taken, the *red blind* will select with red, the green and brown skein which appear to the normal eye darker than the test colour; while the *green blind* will select red and brown of lighter shade than the test-skein. Violet blindness is exceedingly rare, it would be detected by a confusion of purple, red, and orange in the second test.

The following "Suggestions as to International Arrangements for a uniform system of Maritime, Coast, and Harbour Signalling, with a view to the safety of life and property," have been recommended by a committee of the Medical Congress appointed for that purpose:—

A. *With respect to Land.*

For admission as *Driver* or *Stoker* is required:—A healthy condition as regards habitual congestion or irritation of the eyes and eyelids; *for each eye*, complete field of vision, normal acuity and refraction, colour-sense at least four-fifths of the normal, total absence of commencing cataract or any other progressive disease.

For admission to other *Railway Service* is required:—A healthy condition as regards habitual congestion or irritation of the eyes and eyelids; *for each eye*, complete field of vision, total absence of cataract, or any other progressive disease; *for one of the eyes*, normal acuity and refraction, colour-sense at least three-fifths of the normal; *for the other eye*, sight of

at least half the normal, as regards both acuity and colour-sense.

B. *With respect to Sea.*

(2.)—That in *ocean-going ships* and in *all steamers*, especially those carrying passengers, there should always be in actual control of the helm a person possessing *with the two eyes together, without glasses*, normal sight, both as to acuity and colour:—and that, *in addition*, in such ships, *at least one* of the persons actually on the look-out should be similarly qualified.

(3.)—That in vessels engaged in the coasting trade, every person liable to take charge of the helm should possess *with the two eyes together, without glasses*, sight equal to at least two-thirds of the normal, both as to acuity and colours.

(4.)—That all persons engaged in marine signalling, ashore or afloat, and all pilots, should have normal sight, both as to acuity and colours, as defined in Article 2.

(5.)—That hypermetropic persons, although satisfying the requirements of Articles 2, 3, and 4, should nevertheless not be admitted, if before the age of eighteen they have a manifest hypermetropia of 1 dioptré or more.

(6.)—That re-examinations should be made at the age of forty-five.

(7.)—That the examinations should be conducted by persons of recognised competency, under the direction of a Central Medical Authority in each country.

(8.)—That an International Commission should be constituted, to fix upon such further measures as to signals as may be necessary for safe navigation, and specially upon the standard colour, and the sizes of the signals which should be employed.

EXPLANATORY REMARKS.

(The numbers refer to the Resolutions.)

A. *As to Land.*

(1.)—The signal service on land, though quite as important, are not so purely an international matter as those having reference to the sea. Many countries have already established legislation in this respect, and others are introducing it by degrees. It is believed that the standards now recommended

may be of general utility, especially in the case of conterminous countries. The mode of examination, for colours especially, is here, as for service at sea, of the highest possible importance.

B. *As to Sea.*

It is obvious that Regulations having an International character become every year more urgently required, from the increasing number, size, and speed of vessels.

In view of the practical difficulties with which all compulsory examinations are attended, it has been sought:—

(a.) To limit the examination in each case to what is strictly necessary.

(b.) To require them only when absolutely indispensable, and of the smallest possible number of persons.

(c.) To simplify the methods as much as possible.

On large ships, many sailors not required for the helm, or to be responsible for the look-out, may be admitted without certificate of examination; but as it will be in the interest of all to be possessed of such a certificate, which would represent a higher competency, it may be expected that many would themselves seek for it, from whom it would not necessarily be demanded, and facilities for obtaining it should at all times be at hand in maritime ports.

(2.)—Good sight *without the aid of glasses* is required, because glasses fail to help just where clear sight is most needed—*e.g.*, in storm, rain, or fog.

Acuity of Sight:—Complete acuity is not more than sufficient, and even scarcely sufficient, having regard to the increasing number, size, and speed of steamers. But it will be practically enough, if at sea, this complete acuity is attained by the use of *both eyes combined*. The number of persons excluded under this rule will be much less than if complete acuity for *each eye separately* is needed.

The acuity is supposed to be determined by viewing letters or signs at a certain distance, under a certain angle, on the principle of the test-types of Snellen.

Colour Sense is supposed to be tested by pseudo-iso-chromatic tables, on the principle of those of Stilling, subject to control by the use of light transmitted through coloured glass, in imitation of signal lights. This control will also aid in detecting central scotoma for colours, in the very rare cases where it might co-exist with the required acuity.

Holmgren's excellent tests have been already extensively adopted. But their use demands more skill in the examiner. Tests well selected on the principle of Stilling might be very well adopted as standards for ascertaining normal colour-sense, as well as definite degrees of colour-sense below the normal. The principle of Stilling has been recommended as affording a quantitative as well as a rapid qualitative test.

(3.)—A lower standard is fixed in the coasting trade (excluding steamers) because the vessels are smaller and the speed less. Moreover, a demand for full acuity, would render it difficult to procure a sufficient number of sailors, as each hand must be liable in small vessels to serve at the helm.

(4.)—It is obvious that the persons here named must have full acuity and colour-sense.

(5.)—Persons having a manifest hypermetropia above that here indicated would not possess, at the age of thirty-five or forty, without glasses, the needful degree of acuity; it is better then, both for themselves and the service, that they should not be admitted at all.

(6.)—The attendant practical difficulties have caused one re-examination only to be advised at the age of forty-five. It has been found that the very great majority of persons, once admitted as having good sight, have retained it up to that age. A great number, no doubt, have been admitted hitherto without sufficient examination. Still, it would not be practicable to institute a general examination of those already in the service. Nevertheless, it would be desirable to examine anew, in the case of passenger steamers, all those responsible as helmsmen and look-out men.

The Congress recommends that surgeons of ships should be qualified to exercise special surveillance as to the sight of those employed in these capacities on board.

(7.)—A central medical authority is requisite to ensure the perfection of the system, and its uniformity. He should propose the examiners, and be responsible for their fitness. They should be men of ascertained competency, and, as far as practicable, qualified as medical specialists.

(8.)—The measures recommended in Articles 2 to 7 should be brought into operation without delay. But an International Commission would still have to determine the precise colour of the glass, securing uniformity in that, as well as in the size and disposition of the signal lights.

NIGHT BLINDNESS, OR HEMERALOPIA.—Cases of hemeralopia occasionally occur without any apparent change in the choroid or retina, and are therefore called idiopathic. The following extract, taken from a work stamped with the authority of Government, gives a remarkable account of hemeralopia. Capt. Smith, R.N., reports that in September, 1801, the “Merlin” captured a Spanish privateer, and having been sent with twenty men to cruise in her as a tender, he thus describes their adventure:—

“In a few days, at least half the crew were affected with nyctalopia. We were chased one calm morning by a large zebec, carrying from eighty to one hundred men, and towards evening she was fast pulling up to us; our people, having been fagging at their oars many hours without any relief. Knowing that night would deprive half of our crew of their sight, it was proposed to try our strength with the enemy while it was daylight; this was answered by three cheers. The oars were run across, and the enemy, by this time, being within gunshot, the action commenced. After a time, to our great relief, she sheered off and pulled away from us: we, in our turn, became the pursuers; but when night came on we took special care to lay our heads from the zebec, and saw no more of her.

“This circumstance put me on devising some means of curing the people affected with night blindness, and I could think of none better than excluding the rays of the sun from one eye during the day, by placing a handkerchief over it; and I was pleased to find on the succeeding night that it completely answered the desired purpose, and that the patients could see perfectly well with the eye which had been covered during the day; so that, in future, each person so affected had one eye for day and the other for night. It was amusing enough to see Jack guarding, with tender care, his night eye from even the slightest communication with the sun’s rays, and occasionally changing the bandage, that each eye, in turn, might take a spell of night duty, it being found that guarding the eye for one day was sufficient to restore the tone of the optic nerve, a torpor of which and of the retina is supposed to be the proximate cause of the disease. I much question whether any purely medical treatment would have been so complete and, above all, so immediate in effect.

“Persons affected with nyctalopia become blind as night

approaches, and continue so till the approach of daylight; the medical treatment is bleeding and purging, blisters applied repeatedly to the temples, close to the external canthus of the eye, cinchona bark, joined with chalybeates, &c., all of which was impracticable by us, having no medicine on board our little vessel. I am aware that this disease frequently attends scurvy in tropical climates, and is sometimes occasioned by derangement of the digestive organs and hepatic system, in which cases our simple treatment would be useless; but in the above instance it was evidently caused only by the sun."

Although bordering on the marvellous, this account is worth recording, more particularly as we agree with Captain Smith as to the cause of hemeralopia, which, in this instance, was due to scurvy and over-stimulation of the retina. Instances of the kind are common in the tropics. In hemeralopia the patient is not only blind at night, but at all times if taken into a room dimly lighted; he can see comparatively well in bright moonlight, or in a well-lit room.

Causes.—This condition is no doubt due to exhaustion of the perceptive elements of the retina either from excessive stimulation or from defective nutrition, probably a combination of these causes is the most prolific source of hemeralopia. A patient, whether from bad food, impure air, or disease, falls into a state of anæmia, and if he be then exposed to the intense glare of a tropical sun, hemeralopia may result; in this way we account for the fact that sailors returning from a long voyage in the tropics, and predisposed to scurvy from ship-diet, are not unfrequently affected with night blindness.

The Treatment of night blindness resolves itself, therefore, into endeavours to restore the nutritive functions by suitable diet, and such means as iron and strychnine, and when required, by anti-scorbutic remedies, giving the eye rest at the same time. If these objects are kept in view, we have never seen a case of hemeralopia that has failed to recover; provided, of course, that the patient has not been suffering from some incurable disease of the liver, kidneys, or other important organs of the body. In making this assertion, we refer to cases of hemeralopia in the limited sense above indicated, and not to cases in which the night blindness depends upon other and assignable causes, such as retinitis pigmentosa.

SNOW BLINDNESS would appear to arise from somewhat the same causes as hemeralopia, the glare from the snow causing over-excitation, and, ultimately, loss of sentient power in the retina. The affection, however, usually passes away after the removal of its cause.

Assistant Surgeon-General Cayley, writes:—

“As I was crossing the ‘Zoji La’ pass from Cashmir to Ladak early in May, I had the opportunity of seeing many cases of snow-blindness, and a brief description of the affection may be of interest.

“The day of crossing the pass, my party were on the move for more than sixteen hours over fresh fallen snow the whole way, and soon after mid-day I noticed some of the servants and baggage coolies stumbling along with their eyes covered and protected as much as possible, and all complaining of intense burning and throbbing in the eyeballs, headache, and dimness of sight. I recommended what I had heard from natives of the mountains, and had myself found to give great relief—viz., the application of a handful of snow on the eyes for a few minutes till the burning was removed, and repeating this at intervals. After the march was over, and during the night, all those whose eyes were affected, consisting of nearly half the party, suffered most acutely from deep-seated pain in the eyes and orbits, with more or less complete loss of sight; and many of the coolies, who were all hill-men, and accustomed to the snow, were sitting out in the cold night air, groaning with pain, but finding their sufferings less than in the smoky huts. The next morning two of the servants, and about twenty-five coolies, were suffering in a greater or less degree from the following symptoms: almost complete loss of sight; they could just see their way about, but some even were quite blind. The most intense intolerance of light; severe deep-seated pain and burning in the eyeballs and orbits, and generally bad headache. The other symptoms were profuse lachrymation, injection of the conjunctiva, and swelling and puffiness of the lids, and contracted and inactive pupils. Acute ophthalmia, in fact, with the symptom of nervous irritation especially prominent. In some only one eye was affected, but generally both, though not always in the same degree. In some the affection commenced after the day’s march and exposure were over, but I think only in those who went into the huts, and were exposed to the irritating smoke of fires of wood and animal

dung. The treatment I employed and which gave great relief, was warm fomentations, and a lotion of equal parts of tincture of opium and water dropped into the eyes, and keeping the eyes covered with a wet bandage. The drops caused smarting for a few minutes, followed by great relief."

LIGHTNING BLINDNESS.—Momentary exposure to a very bright light may induce impairment of vision, by destroying the sensibility of the retina. The captain of one of our coasting steamers consulted us a short time since on account of impaired sight, particularly marked at night. His vision had been perfect until within a few months of the time he was first seen by us; he was then at sea, and one fearfully dark and stormy night suddenly a vivid flash of lightning burst over the vessel: our patient states that for a few minutes afterwards he was perfectly blind, and although he recovered his sight to a great extent, it has since remained impaired. No abnormal appearance could be detected with the ophthalmoscope.

At a meeting of the St. Petersburg Deutscher Aerztlicher Verein, Dr. Magawly read an interesting paper on three cases of double central amblyopia in two men and a boy, caused by looking at an eclipse of the sun (in August, 1887) with unprotected eyes. All three had suddenly become aware of the appearance of dark spots in their visual fields. The condition had remained unaltered till the patients came under Dr. Magawly's observation a couple of weeks later. On examination he found an identical train of symptoms in all the three cases. The vision was $\frac{4}{10}$: there was a fairly

extensive central scotoma for red (the defect having half a foot in diameter at ten feet); no ophthalmoscopic changes were discovered. After a rather prolonged stay in a dark room and subsequent wearing of dark protecting spectacles, a complete and permanent recovery ensued in all the cases. Medical literature contains a fairly large collection of similar curious instances of central scotoma, sometimes associated with retinal hæmorrhage, contracted under similar circumstances. The affection is thought to depend upon the disappearance of the "visual red" under the influence of strong sunlight. In darkness the visual purple is gradually restored. A long stay in a dark place is followed by very abundant formation and accumulation of the visual red, as

direct experiments on animals have proved. The magnesium light, however strong, does not destroy the purple.

The functions of the retina may become similarly injured from prolonged work on minute objects in a bright light, as in the instances of watchmakers and engravers, and yet the fundus of the eye may appear perfectly healthy.

HEMIOPIA signifies half vision, other terms sometimes used to express the same condition are hemianopsia and hemianopia; these both mean half blindness. Defects occurring in both visual fields may be due to lesions of the optic nerves, the chiasma, or the optic tracts. The fibres of the optic tracts meet in the chiasma, those from the outer part of the right tract passing to the outer part of the right retina, and those from the inner part of the right tract supplying the inner half of the left retina; the left optic tract in like manner supplies the outer half of the left retina, and the inner half of the right retina. In consequence of this relation of the fibres of the optic tracts, mechanical causes, such as a clot of blood, or a tumour, interfering with the integrity of either optic tracts, may produce blindness confined to the inner half of one and the outer half of the other eye, while the remainder of both retinae may be healthy, this is called HOMONYMOUS HEMIOPIA.

Homonymous hemiopia is the most common variety of the disease, it may be produced by a lesion anywhere between the cortex of the occipital lobe and the chiasma. If the disease is confined to one side of the brain, the limitation of the field of vision is often clearly defined, and should the history of the case point to the formation of a clot as the cause of the affection, we need hardly fear that the impairment of vision will extend; but the majority of these cases depend on tumours involving the chiasma, in which case both tracts are gradually implicated and the patient's sight hopelessly destroyed; the line of demarcation separating the healthy from the affected part of the retina is usually directly vertical, the macula being generally included in the normal part, so that the visual acuteness may be fairly good; right homonymous hemiopia is more troublesome to the patient than left hemiopia, on account of the difficulty of reading, as one reads from left to right and in order that one may do so easily, it is necessary to see a little in advance of the word one is reading.

The fields should be carefully mapped out with a perimeter

to enable a correct diagnosis to be made. Other varieties of the disease are *temporal* and *nasal* hemiopia. In *temporal* hemiopia, the out part of each retina is affected and is due to a lesion of the chiasma. It is usually associated with other symptoms, as paralysis of other cerebral nerves, imperfect action of the pupils, &c., here the limitation of the fields are more or less irregular.

In *nasal* hemiopia the inner part of each retina is affected; here we may ascribe the disease to a lesion of the optic tracts; this variety is exceedingly rare and the prognosis very bad, usually ending in complete optic atrophy. One or two cases of monocular hemiopia have been recorded; here the lesion must be between the chiasma and the eye affected, usually the line separating the blind and seeing part of the retina is irregular.

In these cases of destruction of the nerve-fibres, occasioned by disease affecting the optic tracts or the brain, abnormal appearances are not often observed in the optic papilla or retina; it is this fact which distinguishes hemiopia resulting from paralysis, from that impairment of vision in which half of the retina has been detached, or entirely destroyed from an effusion of serum or blood behind it.

Hemiopia sometimes appears as a transient affection, depending upon functional derangement of the retina. Dr. Wollaston's case is an instance of transient hemiopia; he remarks:—"I suddenly found, after violent exercise two or three hours before, that I could see but half the face of a man whom I met; and it was the same with respect to any other object I looked at. In attempting to read the name Johnson over a door, I saw only . . . son; the commencement of the name was wholly obliterated to my view." In this case the affection passed off in about a quarter of an hour. We meet with instances of this kind from time to time in practice; they generally come on with indigestion and headache, and are of little or no consequence, but may cause the patient much unnecessary alarm. On examining the eye with the ophthalmoscope, no abnormal appearance can be discovered, the affection probably depending on loss of power in the nerve-fibres, supplying a portion of the retina of either eye. In some instances of hemiopia there is a marked defect of colour-perception in the sound half of the visual field. In a case of this kind vision was nearly restored, but the colour sense remained defective.

Treatment.—In that form of disease last described, we must direct our attention towards the removal of the source of irritation, which is usually gastric; but, as we have before remarked, the affection is generally a very transient affair, and it will often be unnecessary to prescribe anything for it. In those far graver cases arising from actual destruction of tissue in the optic tracts, or nervous centres, we can seldom do much towards relieving the symptoms. We shall generally have sufficient evidence of the nature of the lesion from various concomitant symptoms, depending upon the disease of the brain, and it is to these our attention should be directed rather than to the state of the retina.

SCOTOMA (constant), signifies a form of partial blindness, in which only a portion of the retina is insensible to light, and this part often appears as a black patch to the patient, particularly when he is engaged in reading or any similar work. In these cases the rays of light fall on certain parts of the retina, which are incapable of appreciating the stimulus of light. In this respect the class of cases we are considering differ from instances of toxic scotoma, as, for instance, that caused by tobacco, and which will be subsequently referred to; in these the scotoma is negative. The form sense, as well as the colour-sense is defective in cases of tobacco poisoning, over a limited area of the retina, but the patient is not aware of the defect, it does not appear to him as a dark patch in the field of vision.

One of the characteristic features of a positive scotoma is, that the patient observes the dark spot to move exactly with his eyes, and not float about before them, as in *muscæ volitantes*; thus, for instance, it will appear to follow the eyes as these are cast along the lines of a book in reading or writing, as it were covering a part of the line; in fact, we may generally detect the presence of a scotoma, by making the patient look through a small aperture at a sheet of white paper, upon which he will generally perceive a black spot projected, if a part of his retina is insensible to light. Scotomata vary much in form and figure, being described as discs, lines, stars, and so on. The position of the scotoma will very much influence its effect on the patient's sight; if at or near the yellow spot it will be most annoying, constantly interfering with the perfection of vision. On the other hand, if the scotoma be eccentric, it may cause but little inconvenience, and hardly any at all in reading or writing;

but, when looking at a distant object, the patient will probably notice a hazy or misty appearance over a portion of the field of vision.

Scotoma may arise from congenital defect, a portion of the retina being imperfect or wanting; but these dark spots are far more commonly the result of damage to the retina from a blow on the eye, from hæmorrhage or inflammation of the retina and choroid. In this case the ophthalmoscope may reveal to us the nature of the disease; it may be that a spot of atrophied retina, or one infiltrated with choroidal pigment will thus be seen, and account satisfactorily for the symptoms from which the patient complains.

In other cases scotoma may be induced by injury, perhaps the result of a clot or plug in one of the vessels of the optic nerve, interfering with the integrity of some of the fibres of the nerve, or destruction of a minute portion of the brain substance, in which case, although the portion of retina supplied by these fibres will be insensible to light, we may be unable to perceive any alteration in the fundus of the eye with the ophthalmoscope. In cases of this description, the scotoma generally comes on suddenly. Should a scotoma have been observed by the patient for some considerable time, it is seldom that the dark spot will disappear. But if the patch has only recently appeared, the case will not be so hopeless, and our prognosis and treatment will be guided by the aid which the ophthalmoscope affords us. No such favourable prognosis can be formed in a case of partial atrophy of the retina, or where its nervous structure has been invaded by pigmentary formations from the choroid. Blood clots are sometimes the cause of a scotoma, and may be detected with the ophthalmoscope; as they are absorbed, the part may gradually recover its functions. The same remark applies to limited serous effusions behind the retina, provided the nervous tissue does not appear to be atrophied, having lost its transparency over the seat of effusion.

Another variety is the colour-scotoma, usually characteristic of toxic amblyopia. Here, of course, the retina is sensitive to light and form, but not to colours.

AMAUROSIS AND AMBLYOPIA.—These terms have frequently been used synonymously; here the term amaurosis will be confined to complete loss of vision, and amblyopia to defective vision, occurring without any visible change in the

fundus. This group is much smaller than formerly owing to the improvements in our methods of examination.

AMAUROSIS.—Blindness without any change in the fundus may occur from disease of the visual centre; when the loss of vision comes on suddenly it may be due to cerebral hæmorrhage, and the prognosis is bad, as it frequently ends in optic atrophy; when occurring in scarlet fever, albuminuria, diabetes, and pregnancy, we may be more hopeful.

The prognosis in cases of loss of sight occurring after embolism, or profuse hæmorrhage, is generally unfavourable, although cases of complete recovery are recorded.

The same remarks are applicable to instances of *complete* loss of sight following over-suckling. In these instances, it may happen the nutrition of the nerve elements of the retina have been so much impaired, that these delicate structures have undergone irreparable changes leading to loss of vision. On the other hand, it is very common to meet with cases of women who are nursing, complaining of loss of sight, which is quickly restored by means of tonics and weaning the child.

In another class of cases of amaurosis, arising apparently from alterations in the condition of the blood, the blindness may be only temporary, such for instance as partial or complete loss of sight after various forms of fever. The blindness usually comes on suddenly, lasting for two or three days, and then returning. But it is remarkable that in many of these instances the pupil responds to the stimulus of light; and this is a significant point as a guide to prognosis, for if the pupil retains its activity, however great the blindness may be, we may, in the above-mentioned cases, offer a favourable prognosis, for the facts indicate that, whatever the cause of the loss of sight, it must be situated between the corpora quadrigemina, and that portion of the brain in which the perception of light is localized.

Cases of a congestive form of amaurosis consequent on disease of the heart may disappear, if the disturbance in the circulation subsides. Intra-cranial overloading of the blood-vessels may lead to a similar result, and will be accompanied by symptoms of cerebral hyperæmia; the loss of sight is often sudden, and may as rapidly recede on the removal of the exciting cause; among such causes may be mentioned, interruption of the menses, mental excitement, excessive vomiting, or muscular exertion.

Unilateral amaurosis may be the result of laceration of the optic nerve from injury or caused by hæmorrhage into the nerve sheath; these cases pass on gradually to optic atrophy, and then become included under that term.

AMBLYOPIA or defective vision without any apparent fundus change is met with pretty frequently and may be divided into:—

Congenital amblyopia.

Toxic amblyopia	..	}	Tobacco. Alcohol. Quinine. Lead. Bisulphide of carbon. Uræmia.
-----------------	----	---	---

Hysterical amblyopia.

CONGENITAL AMBLYOPIA is very common, and frequently escapes detection (when unilateral) for many years, the higher degrees are often associated with nystagmus; in some cases there may be a history of previous inflammation of the eyes or brain, while in others no apparent cause can be found, probably the most common are those unilateral cases occurring with squint, and which it has been customary until lately to put down to suppression of the images.

TOBACCO AMBLYOPIA commences with a gradual failure of sight in both eyes, together with a central colour defect in the field of vision, chiefly for red and green; this defective area is generally oval in shape, extending from the outer part of the blind spot to the inner side of the macula; care must be taken that the piece of colour used as a test object, for detecting the scotoma is not very large; about 8 mm. square is a convenient size, the fields of vision are never contracted peripherally. (Page 8.)

These cases occur chiefly in men over forty, and among those who smoke large quantities of the stronger and cheaper forms of tobacco, especially shag; frequently the patient has smoked for many years, and never thinks of the tobacco as a cause of his amblyopia. It seems somewhat curious that a person should smoke for twenty years or more, and then suddenly develop tobacco amblyopia, the probable reason is that the individual's health has become somewhat run down from dyspepsia, alcoholism or insufficient food, and thus become unable to resist the toxic effect of the tobacco as he previously did. Usually these cases have been described

without ophthalmoscopic signs, but the careful observer may frequently discover slight changes which may be a great help in arriving at a right diagnosis, the disc may be somewhat hyperæmic and have a more or less opaque appearance, with or without some slight blurring of the minute details of the disc; gradually the outside of the disc becomes pale and this paleness may extend slowly all over it, the vessels remain of their normal size, the pupils are usually somewhat sluggish to light.

Cases of tobacco amblyopia occur much more frequently in men, but several cases have been recorded in women who have smoked; with regard to the effect of excess of alcohol in helping to produce tobacco amblyopia, it has a most deleterious influence, especially in cases where deterioration of the general health is produced by its use.

Treatment.—Tobacco must be given up entirely and the general health improved with tonics; most cases commence to improve at once, though where the loss of vision is very great, some considerable time must elapse before complete recovery can take place.

Alcohol, quinine, bisulphide of carbon, have all been credited with producing toxic amblyopia; such cases are, however, less frequently met with than tobacco cases.

HYSTERICAL AMBLYOPIA may either be bilateral or unilateral; it is most commonly met with in young women, the vision may be considerably reduced and in some cases even blindness occurs, when hysterical amaurosis would be the correct name to apply; the amblyopia usually comes on suddenly, exists for many months, and then perhaps recovery takes place all at once; when vision is sufficiently good to allow of the fields of vision being taken, they will usually be found to be contracted peripherally. There is often considerable disturbance of the colour vision, and frequently other hysterical symptoms are present. We were, not long since, consulted by a lady thirty-five years of age, who had for many years suffered from so-called disease or weakness of the spine; she had spent large sums on orthopedic surgeons and instruments, when she was suddenly seized with total loss of sight. The patient's iris in both eyes was sensitive to light and no changes could be seen with the ophthalmoscope. The blindness lasted for nearly two years, being completely cured by a German oculist, who treated the patient by massage.

Simulated Amblyopia.—In former times under the prac-

tically life service of our soldiers, it was not uncommon to meet with men, who, all other means having failed, hoped to procure their discharge from the army by simulating partial or complete blindness; cases of this description are not often met with now, but even in the army and certainly among prisoners, a plea of loss of sight may be put forward as a reason for inability to work. It may be the defect of sight is stated to be either bilateral or unilateral, the latter is most common among soldiers, and if the individual feigns to be only partially blind with one eye, it is by no means easy to form an accurate opinion on the subject, especially if the pretended blindness is only slight. In cases of this kind to detect the imposition we may in the first instance place a prism with its base directed inwards or outwards, in front of the good eye, and notice if a lateral movement of the eye is produced, such a movement almost always taking place in the unconscious desire for the fusion of the two images in binocular vision, provided that the sight of both eyes is good and that the muscles of the eyeball are healthy. Another test is Snellen's coloured letters; these are transparent red and green of different sizes. The patient is first made to read these letters without anything before his eyes. A pair of spectacles having a green glass on one side and on the other a red is then placed before the person's eyes, taking care that the eyes are kept open. Through the green glass the red letters are invisible, and through the red glass the green letters, so that some of the test letters are visible to one eye and some only to the other eye. Any mistake made in reading the letters is in this way detected. If a prism of 12° or so be held with its base upwards or downwards before the eye in which visual power is acknowledged to be retained, and the person who is subjected to the test, on being asked what effect it has on his sight, states that it causes double vision, the simulation is proved, for diplopia could only result by both eyes seeing. If the base of the prism is turned inwards, and the other eye turns inwards, evidently an effort is being made to prevent double vision, and the assertion of blindness in the inverted eye is therefore absurd.

MICROPSIA is a term used to imply a condition of the sight in which objects appear smaller than they really are; it is sometimes a prominent sign in paralysis of the ciliary muscle, and is occasionally complained of in retinitis.

MEGALOPSIA is the opposite condition, objects appear larger than they should.

METAMORPHOSIA is the distortion of objects.

PHOTOPSIA the sensation of light, CHROMATOPSIA the sensation of colour; and ERYTHROPSIA, the sensation of red; any of these may indicate irritation of the retina or of the visual centre in the brain and are symptomatic of hyperæsthesia of these parts. This condition is sometimes met with after cataract extraction, all objects being coloured a bright blood red; which comes on usually some time after the operation, it may be when everything has gone well, and the patient has otherwise good vision.

CHAPTER XIV.

DISEASES OF THE LENS.

Anatomy—Cataracts—Varieties—Operations for—Dislocation of the Lens.

THE CRYSTALLINE LENS is situated immediately behind the iris and is an important part of the refracting system of the eye; it is a transparent, compressible, bi-convex body, having its posterior surface more convex than its anterior; the lens is capable of being acted upon by the ciliary muscle so that its refraction can be increased or decreased, thus adapting the eye for different distances. The density of the lens increases from the circumference to the centre, the central hard part being called the nucleus; its "index of refraction" increases from the peripheral layers towards the centre.

The lens is entirely enclosed in a smooth almost structureless capsule. The front portion of the capsule is as thick again as the posterior part. It is thinnest of all at the posterior pole. The capsule is materially strengthened by the suspensory ligament of Zinn, which, after leaving the ciliary processes, splits up into a number of brush-like fibres to be inserted into the anterior, and partly into the posterior capsule of the lens, close to its periphery, in a peculiar zigzag fashion. The capsule, when torn *in situ*, is very elastic, and rapidly contracts and puckers up. The posterior surface of the anterior capsule is lined throughout, by a single layer of columnar cells with a hexagonal base, the latter part resting against the capsule. These cells are perfectly transparent and homogeneous; but after death the cells become cloudy, and a reticulated nucleus and

stroma can be demonstrated. At the lateral margin of the lens these cells rapidly elongate, and from being vertical incline more and more obliquely on each other, and as they are traced backwards, they become tapered and arch over their predecessors, their distal extremities being in regular succession against the inner ends of the columnar cells mentioned above. As each cell is longer than its neighbour, and the fibres taper rapidly towards the corner of the arch, the fibres appear to run parallel in a horizontal section through the lens. The lens fibres, then, are nothing more or less than enormously elongated ribbon-shaped cells passing through the posterior surface to the anterior, the posterior extremities being in contact with the posterior capsule, anterior with the epithelium of the anterior capsule. Between the two surfaces of the lens, the fibres are arranged in concentric lamellæ. The fibres are narrow and hexagonal in section, and they lie in close contact; a section through the lens parallel to its surface shows a beautiful mosaic. These hexagons are remarkably uniform in shape, and are arranged very evenly; but here and there a fibre fails to fill the area allotted to it, so that a space exists between the contiguous fibres. These spaces are said to be lymph channels, and are intimately connected with the nutrition of the lens and with the changes in accommodation. We have been describing the lens fibres as they would be seen on a flat surface, but as the lens is made up of such planes, the approximation of the ends of successive pairs of such fibres in regular order will give rise, from a bird's-eye view, to more or less stellate arrangement, the number of rays varying with the number of such collections of fibres. These rays or sutures can frequently be seen by means of oblique light in a healthy eye. In the child each surface presents three such sutures, arranged as a Υ in front, and as a Λ behind, each pair enclosing one-third of the circumference. In adults there are secondary rays in between. These sutures contain a semi-fluid homogeneous cement substance similar to that between the fibres themselves. It is along these sutures that those degenerative changes are most prone to commence, which constitute cataract.

The term *cataract*, should be restricted to cases in which there is impairment of sight, in consequence of the substance of the lens having become opaque, and in which there is no evidence of any other disease in the eye.

Capsular Cataracts consist of an opaque condition, of either the anterior or the posterior capsule of the lens. These two forms of cataract may exist together, and either the whole or a limited portion of the lens or of its capsule may have become opaque. Cataracts are classified according to the nature of the changes which have taken place in the lens; the principal sub-divisions being the *senile*, *soft*, *mixed*, and *traumatic* cataracts. *After cataracts* are also referred to a sub-division, but as we shall subsequently explain, according to the above definition they cannot be strictly considered as cataracts, for they consist principally of inflammatory products, which form a new growth behind the iris.

Causes.—Cataracts are produced in consequence of some faulty condition in the nutrition of the lens, whereby degenerative changes take place in the transparent material which constitutes the lens fibres; for this reason it is most commonly met with in the failing nutrition of advancing years. In other cases, as in persons suffering from diabetes, opacity of the lens seems to depend on alterations in its normal nutrition, consequent on a defective state of the blood. In instances of traumatic cataract, the capsule having been ruptured, not only is the nutrition of the lens interfered with, but the aqueous coming in contact with the lens substance soon causes opacity, which generally quickly extends to the whole lens.

Senile, or Hard Cataract.—There is a gradual increase in the density of the central portion or nucleus of the lens, and consequently of its refractive index, from the period of its full development onwards. This process of consolidation slowly extends from the nucleus to the surrounding lens fibres, and the reflection of light from the surface of such a lens is the cause of the greyish, slightly opaque appearance to be seen behind the pupil of most old people. Nevertheless, such a person may have good sight, at the most being presbyopic, and is not considered to be suffering from cataract. In the early stages of senile cataract, vision is impaired in the affected eye, the nucleus is of a decidedly amber colour, the opacity thinning off gradually towards the periphery of the lens; on dilating the pupil we notice striæ extending from the circumference of the lens towards the opaque nucleus; as the disease advances these striæ become more distinct. It is in consequence of the nucleus of the

lens being principally involved in cases of senile cataract, that most patients, in its early stages see better in a dim light, or when the pupil is slightly dilated, so that rays of light can pass through the margin of the lens to the retina. In some cases, however, in consequence of the dispersion of the light passing through the opaque nucleus, the patient's sight is aided by contraction of the pupil, and in such cases vision may be improved by the use of eserine.

Soft Cataracts are rarely seen unless among children or young people. In these cases the fibres of the lens not only undergo degeneration, but they become disintegrated, so that the contents of the capsule consist to a large extent of an opaque fluid; the capsule bulges forwards, pushing the iris before it, and so lessening the depth of the anterior chamber. If the pupil is dilated the opacity in the lens is seen to be uniform, and to extend up to its margin. Opaque spots may sometimes be observed in the capsule, and also flakes of cholesterine. The fluid contents of the capsule, in some instances of soft cataract are absorbed, and as this process goes on the capsule shrinks, its anterior and posterior layers may ultimately come into contact, and undergo calcareous or chalk-like changes, so that a dense white membrane comes to occupy the place of the lens behind the iris. The remains of a soft cataract of this kind is generally tough and inelastic, so that it is not easy to break it up with a needle; it is better, as a rule, to remove the membrane by opening the anterior chamber, and either cutting through the opaque tissue, or else, having seized it with a pair of forceps, to carefully withdraw the membrane from the eye.

Mixed (or Cortical) Cataracts commence as a series of opaque striæ, extending from the circumference towards the centre of the lens. As the cataract advances the striæ increase in breadth and length, and become more opaque and glistening, having that peculiar mother-of-pearl-like appearance which is so characteristic of this form of cataract. Such a cataract may, however, present a more densely opaque amber-coloured centre, so that light may be reflected from the choroid through the margin of the lens, while its central portion is opaque. It occasionally happens that in cases of this form of cataract, that the patient regains some of the sight which he had lost, in consequence of the partial absorption of the comparatively soft cortical matter surrounding the nucleus of the lens. Changes such as this

may advance so far as to allow the dense nucleus to move within the capsule, and in some few instances to fall to its lower part. In such cases the iris may be tremulous, in consequence of its not being supported by the lens.

Traumatic Cataracts are referred to in a subsequent section of this chapter.

Capsular Cataract.—In cases of purulent conjunctivitis in infants, and in wounds or perforating ulcers of the cornea, the lens may come to rest against the inflamed or injured cornea, and at the point of contact, usually at the anterior pole of the lens, a deposit of inflammatory material adheres to the capsule, and subsequently becomes organized into a patch of opaque cicatricial tissue. As the inflammation or injury to the cornea passes away, the aqueous is retained in the anterior chamber, and the lens being thrust back into its normal position carries with it a small patch of opaque tissue; in this way an *anterior capsular* cataract is formed, most frequently situated in the middle of the pupil, so that it greatly interferes with vision. In the majority of such cases the cataract originates in infantile purulent conjunctivitis, and then, as a rule, in addition to a central opacity of the capsule, there is loss of transparency in the cornea. Opacities of the capsule such as those referred to, especially if they have commenced in ophthalmia neonatorum, are apt to induce further changes in the cells and cortical substances of the lens, immediately beneath the opaque patch of capsule; these structures undergo fatty degeneration, and subsequently calcareous or chalk-like materials are deposited in the affected tissue. In this way a small pyramidal opaque formation occurs, with its base in the anterior capsule, and it is therefore sometimes called a *pyramidal cataract*. Such cataracts usually remain stationary through life, and are best treated by means of an artificial pupil.

There is a more numerous class of cases, in which the posterior capsule of the lens is implicated; these have been described as *zonular*, and *lamellar* cataracts. They are congenital affections, and are generally found to exist in both eyes. Ammon, Hasner, and other surgeons, many years ago described this form of cataract, and expressed the opinion that these opacities were produced from "vestiges of the hyaloid artery." Dr. De Beck, in the *American Ophthalmological monographs* for October, 1890, has given an admirable series of such cases, and describes the developmental

changes which occur in the lens and hyaloid artery, explaining thereby the circumstances of these posterior capsular cataracts. In foetal life branches of the hyaloid artery cover the posterior capsule of the lens, and, passing over its margin, help to form the vascular sheath—the *membrana capsulo-pupillaris*. If from arrest or a fault in development, this vascular layer over the posterior capsule should not disappear before birth, it is apt to degenerate into connective tissue, and so to form an opaque structure covering the posterior capsule to a greater or less extent. In some cases a small patch of opaque tissue only remains on the capsule, indicating the spot at which the hyaloid artery had formerly passed on to the capsule; the rest of the artery dwindles away, or in some cases its remains may be seen extending from the central artery of the retina, to the opaque patch on the capsule. In other cases a central dense opacity is found, with radiating opacities projecting outwards towards the periphery of the lens. The cortical substance of the lens may remain transparent, and if the opaque capsule does not extend to its margin, the patient may have a fair amount of sight, especially when the pupil is widely dilated. Correct vision in all such cases is much interfered with, and although the opacity in the posterior capsule may remain stationary for years, or even for life, nevertheless, its tendency is to interfere with the nutrition of the lens, and so to lead to cortical cataract.

There is another form of cataract closely allied to that above described, being congenital and referable to faulty development; it is known as *posterior polar cataract*. This form of cataract is situated in the lens, in front of the posterior capsule; the opacity is usually stellate, with three pointed or rounded projections from the central part, as Dr. De Beck remarks, forming angles of about 120° with each other, and usually coinciding with the normal sector of the lens. A cataract of this kind may remain stationary, like the anterior capsular cataract, for life, but we have met with instances, in which the cortical substance of the lens ultimately became involved, it may be, independently of the existence of the polar cataract.

Opacity of the posterior layer of the capsule, is without doubt, met with as a secondary affection in some cases of inflammation of the choroid, ciliary body, and vitreous, but, according to our definition of cataract (page 330), these cases

must be set on one side, for the loss of vision from which such patients suffer, is not due simply to an opacity of the lens substance or of its capsule.

Posterior capsular cataracts, although congenital, may be overlooked until the child is about two years old, when he begins to use his eyes on small objects, and then his defective vision is detected. The pupil having been dilated, a whitish-grey opacity is observed in the posterior part of the lens; the opacity is deepest at its centre, and does not extend to the margin of the lens. The substance of the lens may remain perfectly transparent. Cataracts of this description from a clinical point of view may be divided into two classes—the stationary and the progressive. In the former the opacity of the capsule is well defined, and the circumference of the lens transparent. If a capsular cataract presents appearances of this description, we may be almost sure that it will not spread for years, it may be during life. On the other hand, if, in addition to the central opacity, we notice that the circumference of the lens is marked with well defined striæ; the cataract will progress, in the former class of cases an artificial pupil may be sufficient, in the latter the cataract should be removed.

Several rare forms of cataract have been described; among these *black cataract* has held a prominent place; this condition appears to arise from an infiltration of hæmatine into the opaque lens, and rather indicates some deep-seated disease of the eye. Choroido-retinitis has more than once been observed after extracting such a lens. The *calcareous cataract* is another rare form of disease, met with in traumatic cataracts, the lens undergoing degeneration similar to that of the choroid, and other parts of the body.

Extent of the lens involved.—Having formed an opinion as to the nature of the cataract, it is important, with reference to treatment, to determine whether the cataract is ripe; or, in other words, to what extent the substance of the lens has become opaque. If a considerable portion of the lens fibres and its epithelium are transparent, containing a certain amount of living protoplasm, during extraction of the lens, this living matter may become entangled in the iris, and growing there, may become developed into an after-cataract. There can be no question, that in the extraction of immature cataracts, accidents of this kind may occur, but if the operation is performed antiseptically, septic matter

being carefully prevented from gaining access to the anterior chamber, or to the wound in the cornea, the presence of a certain amount of living lens, or epithelial protoplasm in contact with the iris, will do no great harm. In cases of cataract, we may best ascertain how much of the cortex of the lens remains transparent, by means of focal illumination. If we find that the light falling on one side of the cornea, throws a shadow on the opaque lines, or if there appears to be a space between the undilated pupil and the cataract, the anterior part of the lens substance is transparent.

When a cataract has been forming for a long time, and both eyes are involved, but still there is evidently a considerable amount of transparent lens substance, it has been proposed, to accelerate the degeneration of this transparent lens matter by artificial means, before undertaking the operation of extraction.

Some surgeons, in these circumstances, advocate the plan of performing a preliminary iridectomy, and at the time of operation, introducing a tortoiseshell scoop, or some such instrument into the eye, and, with it, making gentle pressure over the capsule of the lens. Pressure exercised in this way, is said to hasten the ripening of the cataract, after which it may be extracted in the usual manner.

Another question likely to arise, regarding the development of a cataract is,—if in one eye the lens is opaque, and in the other, the sight, though impaired is still such as to enable the patient to move about, should we wait until both eyes are equally blind, that is, until the cataracts have fully formed in both eyes, before we operate? The rule commonly followed in a case of this kind is, so long as a patient affected with cataract, can read and move about with comfort with his best eye, not to interfere with the other eye. But if the best eye begins to fail, and the patient's vision becomes so obscure as to prevent his reading and so on, the worst eye should be operated on. Supposing, however, that a cataract is not fully formed in the worst eye, but the patient's sight is much obscured, should we resort to one or other of the methods above referred to, in order to hasten the development of the cataract, and then to extract the lens. We have no hesitation in stating, that in the case of persons advanced in life, or those in feeble health, it would be unwise attempting to produce opacity of transparent lens substance in the manner above indicated. It is much better in almost all cases of

immature cataract, to perform a preliminary iridectomy, and either at the time of this operation to extract the lens, or else to allow an interval of some six weeks to elapse between the iridectomy and the removal of the lens. We have, of late, so frequently operated by extraction (with iridectomy at the time of the operation), for immature cataracts with such marked success, that we cannot hesitate to recommend this proceeding. There is one point which requires care in this operation, and it is, after the lens has presented its margin at the corneal section, to press steadily on the cornea, following up the lens in its exit; in this way the lens draws with it the transparent lens substance, which we are anxious to remove from the eye.

It should be laid down as a rule that when both eyes are affected with cataract, only one eye should be operated on at a time.

Complications.—Before undertaking an operation for the relief of cataract, we should be satisfied that the case is one of uncomplicated opacity of the lens. It is not necessary to recapitulate the symptoms of glaucoma, cyclitis, and such like affections of the eyes which implicate the lens, and may lead to opacity of its substance. When a cataract is fully formed, the patient's vision is reduced to a mere perception of light, but, before operating, it is desirable to determine the amount of vision the patient actually possesses, for it may happen that, in addition to an opaque lens, he has atrophy of the disc, or detachment of the retina—conditions which we could not recognize through a cataract. To determine the amount of vision possessed by a patient suffering from cataract, his pupil should be dilated; and if a patient's pupil does not dilate readily on the application of atropine, it is an unfavourable sign, the choroid or iris being probably compromised. The action of the mydriatic being fully established, the patient is taken into a dark room, and the flame of a lamp held at various distances, and in different positions with respect to his eye; if he sees the light with tolerable distinctness in all directions, particularly above and below the eye, we may be pretty certain that no detachment of the retina exists, and that the optic nerve is healthy (page 11). On the other hand, if the patient cannot follow the direction of the movements of a bright light, or tell if the hand is held between his eyes and the light, the prognosis is uncertain; although in many dense cataracts

there may be little perception of light. In such a case we may, perhaps, derive some information from the condition of the other eye; both eyes are seldom affected to the same extent. In cases of cataract, with a dense lens in one eye, if the pupil has dilated fairly under atropine, although there is little more than perception of light, should the vision in the other eye be fairly good, we may hope after a successful extraction that the patient will obtain useful vision. The tension of the globe of the eye should always be ascertained in cases of cataract before we undertake an operation.

General Health.—We must also take the circumstances of the patient's general health into consideration before operating for cataract; if weak, or otherwise out of sorts, it is well to put off the operation until his health improves. The urine should be examined for albumen and sugar. All that can be said on this subject is, do not operate if the patient is not in his usual state of health, and if he is, the less preparatory treatment he has the better, unless we propose administering anæsthetics during the operation.

PREPARATION OF THE PATIENT.—The preparation of the patient for an extraction operation will depend upon whether we are going to administer ether while operating, in which case it is well to prescribe a mild purgative the day before the operation. Operate, if possible, early the following morning, the patient having taken a light breakfast some hours before ether is administered.

A subcutaneous injection of morphia immediately before administering the ether, will often ward off sickness, especially if used in addition to the preparatory measures above described. If an anæsthetic is administered, the patient should be rendered absolutely and completely insensible; both sensation and reflex action must be totally in abeyance during the time we are operating, otherwise it is far better not to give anæsthetics. In our hospital practice, with good assistance and so on, we have hardly found it necessary to administer an anæsthetic for the operation of extraction half a dozen times within the past four years. A four per cent. solution of cocaine should be dropped into the eye three or four times, at a few minutes' interval immediately before the operation. In private practice, however, as we shall subsequently explain, there is much to be said in favour of performing this operation when the patient is thoroughly

under the influence of an anæsthetic; it is certainly, so far as the surgeon is concerned, a much safer and more simple proceeding than if the patient's eye only has been cocainized.

SELECTION OF AN OPERATION.—We may briefly consider some of the circumstances which would probably lead us to select, either one or other of the operations commonly employed for the removal of a cataract.

The needle operation is a valuable one, but the drawback to it is the length of time it often takes to cure a patient by this means. Needling is applicable to instances of soft cataract occurring in persons under thirty-five years of age, or before the nucleus has fully formed. But this operation has now been almost superseded by that of extraction, unless in such cases as those to which we have referred. The use of the suction instrument is confined to cases of soft cataract, but it affords no advantages over a linear extraction, and is not so safe a proceeding.

Extraction of the Lens, by the aid of antiseptic precautions and the use of cocaine, has become so successful a proceeding, that it is only in exceptional cases any other operation is resorted to for the removal of either a mixed or a senile cataract. There is, however, a difference of opinion among surgeons as to the advisability of performing an iridectomy either before, or at the time of extracting the lens; no inconsiderable number of operators believe that, on the whole, it is best not to excise a portion of the iris, but, as in the old flap proceeding, while removing the cataract, to interfere as little as possible with other structures of the eye, so as to leave a central and movable pupil after the operation. Some authorities hold, that the best possible results are obtainable by removing the lens in its capsule, either with or without an iridectomy. There can however be no doubt, that the most successful results will be obtained by the surgeon, who, at the time of the operation, can best adopt his proceedings to the circumstances of the case before him. The prevailing opinion among ophthalmic surgeons being, that in by far the majority of cases of mixed and of senile cataracts, the opaque lens can be taken away, so as to obtain good vision, by means of Von Graefe's operation. This operation includes an iridectomy, in order to facilitate the passage of the lens from the eye outwards; it enables us to clear out any cortical matter left in the eye after the delivery of the lens, and

subsequently to obviate the danger of prolapse of the iris through the wound. There can be no question as to the value of any proceeding which lessens the chances of injury to the iris during extraction, or of prolapse after the operation. On the other hand, a bruised iris, if protected from the invasion of micro-organisms from without, will very soon recover from the injury; and we have means at our command, in eserine and carefully applied absorbent and antiseptic dressing, which lessen the chances of inflammation and of prolapse of the iris after the operation. The point, therefore, we have to determine, is whether we should strive for perfection in extraction of the lens, or accept the less perfect result for the greater safety of Von Graefe's operation.

Obviously, the first idea that presents itself to our mind in considering the question of iridectomy in extraction of the lens, is the age of the patient. A large majority of the persons we are called on to treat for cataract are far advanced in life; their sight has been failing them for years, and they have abandoned those occupations which necessitate acute vision; in these circumstances common sense impels us to select the safest proceeding, which will give such a person useful vision for the remainder of his life. Beyond this, wounds in old and enfeebled persons take longer to heal than in the young and vigorous; and, therefore, among those who are advanced in years there is a greater chance of prolapse of the iris, or of its satisfactory recovery after being contused in the passage of the lens outward from the eye. On the other hand, among younger persons and vigorous old people, there is no reason, under certain conditions, why we should not remove a cortical or even a senile cataract without an iridectomy, either before or at the time of the extraction of the lens. These conditions appear to us to depend, in the first place, upon the dilatibility of the iris. If the pupil attains its maximal dilatation, in the class of patients we are referring to, under the influence of cocaine or of atropine, we can remove the opaque lens with safety, provided we have made a sufficiently large opening in the corneo-scleral margin to permit of the easy egress of the lens from the eye. On the other hand, if after completing our section we are not satisfied, that it is sufficiently large to allow the cataract to pass through it without a considerable amount of pressure, we should perform an iridectomy before attempting the

removal of the lens. We must, in fact, have a dilated pupil and a sufficiently large opening through which the lens is to pass, if the iris is not to be injured in its passage outwards, or to leave cortical matter behind it, adhering to the iris. Living epithelium and lens fibres if retained in contact with the iris may induce inflammation; to prevent this is one of the most obvious reasons why we perform an iridectomy in extraction. But if the pupil has fully dilated before the operation, and the section has been made sufficiently large, a cataract, as a rule, may be completely removed without an iridectomy, and without leaving either cortical matter or capsular epithelial cells adhering to the iris. Under anti-septic precautions, so far as our experience goes, sloughing of the cornea does not occur in consequence of a large incision being made at its corneo-scleral margin, the wound heals just as well, and as quickly as if a smaller incision had been made. But the large wound entails a greater risk of prolapse of the iris after the operation than a smaller one does.

However much the iris has opened the pupil, the moment the lens has been removed, it contracts to a greater or less extent; and, in order to diminish the risks of prolapse of the iris after extraction, either without an iridectomy, or if a small portion only of the iris has been removed, a solution of eserine should be dropped into the eye immediately after the operation; and dressings applied in the manner described in a subsequent paragraph (page 349). It is essential if we are to prevent prolapse of the iris that the incision we have made should heal thoroughly before the eye is opened. But if our object is to hurry the patient through his after treatment, and we lay stress upon his opening his eye within a few days of the removal of the cataract, it is better to perform an iridectomy. But we are persuaded, that the more careful the after treatment of the patient for the first fortnight, the better will be the ultimate result of the operation.

With reference to extraction of the lens in its capsule without an iridectomy, in the hands of one of the authors of this work, it has proved more successful for the removal of cataracts among the natives of India than any other proceeding. The circumstances of these people, as far as feeding, nursing, and other conditions of life are concerned differ so much from that of Europeans, that it is quite possible a method of operating on Europeans for cataract might not be the best for the natives of India. This idea is

confirmed by the experience of Mr. H. Cayley, formerly Surgeon to the Calcutta Ophthalmic Hospital, who writes :— that in one year (excluding cases of soft cataract) he operated on 135 cases of hard or mixed cataract: of these, 38 cases operated on by Graefe's method, "29 were successful, leaving the hospital with good sight. This gives nearly 77 per cent. of cures." "The cases of Macnamara's operation gave the following results. The total number of cases was 97, of which 84, or nearly 87 per cent. were successful; in 3 cases iritis set in, from which the patients recovered with a fair amount of sight; in 53 of the 97 operations the lens and capsule came out entire, and only one of these went wrong; this patient was suffering from chronic bronchitis, and a violent fit of coughing caused hæmorrhage into the vitreous chamber."* 87 per cent. of successful cases considering the patients, the impossibility of enforcing a reasonable plan of after treatment, and the surroundings of the individual, is a result which could hardly be excelled, if equalled, by any other proceedings.

THE OPERATION OF DISCISSION OR NEEDLING.—The eye to be operated on having been rendered insensible to pain either by the employment of an anæsthetic or by the application of a four per cent. solution of cocaine, and the pupil fully dilated with cocaine or atropine, the patient is laid on his back upon a convenient couch, in front of a good light. The eyelids are then to be separated with a stop-speculum and the eye washed with a solution of boracic acid. The surgeon, standing or sitting behind his patient's head seizes the conjunctiva with fixation forceps held in the left hand, and passes a needle rather obliquely through the cornea at a point just within the position of the fully dilated pupil, puncturing the centre of the capsule and cortical substance of the lens. No pressure should be exercised on the lens, or we may push it back into the vitreous chamber; this may be avoided by using the needle as a drill, rotating its handle gently, so as to bore a hole through the capsule into the lens. As the needle is withdrawn from the lens, the capsule should be opened by a crucial incision to about the extent of the undilated pupil. The size of the opening in the capsule must, however, depend upon the nature of its contents: if fluid we may freely incise the capsule, and

* "Notes on Operation for Cataract," by Surgeon-Major H. Cayley: *Indian Annals*.

allow the soft lenticular matter to escape into the anterior chamber; but, as a general rule it is better to repeat the operation than to do too much at one time.

In the majority of cases, the needle will have to be used as above described several times, at intervals varying from a month to six weeks; but so long as the eye remains irritable after one operation, a second should not be attempted; it is often several months or even a year, before the lens is completely absorbed. At each operation the needle may be more deeply drilled into the lens; but, we should exercise caution in these cases, for a considerable quantity of lens substance is apt to escape through too free an opening in the capsule, and becoming attached to the iris, it may set up inflammation, rendering it necessary for us to remove the remainder of the lens at once under unfavourable conditions.

It is not advisable in such cases to attempt palliative treatment for more than a few days; if our efforts to stop the inflammatory action then fails, we should administer an anæsthetic to the patient, and when fully under its influence proceed to extract the lens. In some cases we may be disposed in place of extracting the remains of the lens and soft matter which has come forward into the anterior chamber, to evacuate the latter through a small opening in the cornea; but it is generally better under antiseptic precautions, and an anæsthetic, to perform a linear extraction. Cases of this description are in truth traumatic cataracts, and must be treated as such.

Provided no complications occur, the after-treatment of an ordinary needle operation is simple enough. The eye must be kept closed for a few days with a pad and bandage, the pupil being fully dilated with atropine. The patient may be allowed to leave his room at the end of three or four days if there is no pain or irritation in the eye. The pupil must be kept dilated, and in a week or ten days the pad and bandage may be removed. As soon as all irritation has passed away we may proceed to needle the lens again, and so on until the cataract has been absorbed.

The Suction Operation.—This proceeding may be employed as an adjunct to the needle operation; the capsule having been freely opened the opaque lens matter may, after a few days, be removed from the anterior chamber by means of a suction instrument. In cases of soft cataract, the pupil having been fully dilated with cocaine, the capsule is to be

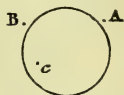freely incised with a broad needle, the point of which should be gently drilled into the opaque substance of the lens, so as to break it up as far as possible, without displacing or injuring the surrounding structures. After some six or seven days a linear incision is to be made in the cornea with a keratome, of sufficient size to admit the nozzle of the suction instrument into the anterior chamber, and so into the soft lenticular matter; the piston is then to be gently raised and the lens substance sucked into the instrument, until the opaque matter which has come forward into the pupil has been entirely removed. Care should be taken to keep the nozzle of the instrument clear of the iris, otherwise it is apt to get drawn into the syringe or otherwise injured. In cases of perfectly fluid cataract there will be no necessity for waiting for a few days after opening the capsule, but the wound in the cornea having been enlarged, the suction instrument is to be introduced, and the opaque lens substance at once removed from the eye.

Cataract Extraction with an Iridectomy:—We have already referred to the preparation of the patient for this operation, and stated our conviction that in hospital practice in exceptional cases only is it necessary to administer an anæsthetic, but that among more highly-strung nervous private patients, it is safer to operate when they are under the influence of an anæsthetic, for cocaine does not destroy the pain caused by removing a portion of the iris, and consequently after making our section, and just as we seize a fold of the iris, the patient may either raise his head or violently strain, and so presses out vitreous from the eye. An accident of this kind is a dangerous matter with the lens still *in situ*, and is of course unlikely to occur if the patient is under the influence of an anæsthetic. The patient, having been cocainised, and laid on the operating table, the stop speculum is to be introduced, and the skin of the eyelids and conjunctival sac should be bathed frequently with a solution of boracic acid, or of corrosive sublimate, one part to six thousand of water. The operator with his left hand, with fixation forceps, then takes a firm hold of a fold of the conjunctiva. The fold of conjunctiva to be thus secured should be in a line with the vertical diameter of the cornea, or immediately opposite the mid-point of the section to be made in the cornea.

The Incision.—The point of a long narrow-bladed knife,

with the cutting edge directed upwards, is entered on the outer side of the corneo-scleral junction, at a point on a level with the semi-dilated pupil. In order to widen the extent of the inner wound, the point of the knife should at first be directed downwards and inwards towards the centre of the pupil, and then, when the blade has advanced about $3\frac{1}{2}$ lines into the anterior chamber, its point is to be directed upwards to the position of the counter puncture; this point must not lie too far back in the sclerotic, but is exactly on a level with the spot at which the knife had entered the eye. Only when the knife has advanced fully $3\frac{1}{2}$ lines within the visible portion of the anterior chamber should the handle be lowered, and the instrument directed to the point of the counter puncture (Fig. 53). As soon as the counter puncture is accomplished, the edge of the knife must be turned forwards, when the incision is to be continued in the apparent sclero-corneal margin: first, by boldly pushing the knife onwards, and then, after its length is exhausted, drawing it backwards. Should this latter movement, though generally sufficient, fail completely to divide the scleral border, the sawing manœuvre must to a less extent be repeated. As soon as the last bridge of the scleral border is cut through, the knife lies freely movable under the uplifted conjunctiva, which, in order to avoid the formation of too long a flap (the proper height is $1\frac{1}{2}''$ — $2''$), must now be divided by a sawing movement horizontally forwards, or even forwards and downwards.

FIG. 53.



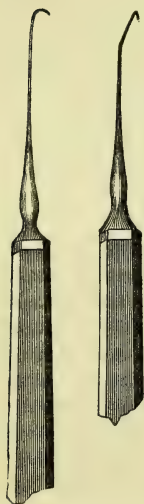
The Iridectomy.—The fixing forceps having been handed to an assistant, with a straight pair of iridectomy forceps, we lift the conjunctival flap off the prolapsed iris, and reflect it down over the cornea, when the prolapsed portion of iris appears perfectly bare. Hereupon the prolapse of the iris is seized with the forceps at its central and most vaulted portion. It is gently pulled upon, so as to make it present a triangular shape, and excised at its base from one corner of the wound to the other, to which end usually two slight strokes of the scissors are required, care being taken that little tags of iris are not left involved in the angles of the wound. After excising the iris, we should direct our attention to the position of the sphincter pupillæ, and if we find that its angles are curled upwards, or involved in the section, we should press them gently back with the curette, so that the

sphincter comes to be in its normal position flat upon the capsule of the lens. If, at this stage of the operation, hæmorrhage takes place into the anterior chamber, the blood may be evacuated by pressing on the cornea with a soft sponge; in some instances it may be necessary to lift up the corneal flap, and squeeze the blood out of the anterior chamber by rubbing the lower lid on the cornea.

Laceration of the Capsule.—The operator having resumed the fixing forceps, now with a cystotome properly bent, and which is armed with a fleam, divides the capsule freely by two or three successive rents, beginning from the lower edge of the pupil, and ascending successively along its nasal and temporal margins near to the upper equator of the lens.

Evacuation of the Lens.—The mode of evacuating the lens varies, but, as a rule, should be effected without the introduction of any instrument, merely by external pressure. In senile cataracts Von Graefe was formerly in the habit of removing the lens by means of a hook or spoon. He directs that the back of a broad and moderately arched spoon should be gently pressed against the sclera, close to the centre of the incision, so that the wound is made to gape. Thus, cortical

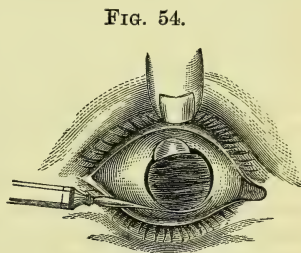
FIG. 53A.



masses are caused to escape, and the vertex of the nucleus presents itself. In order to promote as much as possible the thorough exit of the latter, the back of the spoon is made to glide along the sclera; first, with an equable degree of pressure laterally towards the corners of the wound, and thereupon, withdrawing it from the wound upwards with a continuous increase of pressure. If during these movements the diameter of the nucleus presents itself, the pressure is more and more abated, and the delivery may be completed by applying the end of the spoon to the projecting edge of the nucleus. If there be but a thin stratum of soft cortex, the recommended "slide manœuvre" may likewise be tried, but ought to be abandoned as soon as we observe that during the lateral movements no presentation ensues. In this event, the hook must be resorted to, which in the case of hard cataract is required *ab initio*. The blunt hook which Von Graefe was in the habit of

employing has the form represented in Fig. 53A, and has its stem bent in such a manner as to enable it to be readily pushed under the nucleus. It is first laid flat on the opening made in the capsule: thereupon drawn back over the near edge of the nucleus, when, by a suitable elevation of the handle, it is brought in the direction of the posterior cortex, along which it is then pushed forward on the flat, until it has passed the posterior pole of the nucleus. The instrument is now between the fingers rotated around its axis, so that the plane of the curved extremity of the hook exchanges its horizontal for the vertical position; or should resistance be felt, an oblique one; and the nucleus, or, as the case may be, the whole lens, is by a gentle traction carried towards the incision.

Von Graefe, in his later operations, abandoned the blunt hook, and, like almost all operators at the present time, removed the lens by pressure on the lower portion of the cornea with a vulcanite curette. The eye being fixed by means of a pair of forceps holding a fold of conjunctiva below, and to the inner or outer side of the cornea, the curette is placed along the lower margin of the cornea, and pressure made backwards and upwards; this causes the wound to gape and the upper circumference of the lens to pass through it. The pressure is now increased, the scoop *following up the lens as it is expelled from the eye*. The eye should again be bathed with the antiseptic lotion.



Clearing of the Pupil, and Coaptation of the Wound.—If, as happens in the majority of cases, after extraction of the nucleus, cortical matter remain, it must be evacuated by gentle pressure and friction, exercised with the finger-ends through the medium of the lids, or a small spoon may be introduced for the removal of isolated cortical fragments. Complete removal of the cortex should be insisted on whilst we are engaged in clearing away cortical matter, an antiseptic fluid should be frequently used, otherwise micro-organisms are likely to pass into the eye, and resting in the lacerated tissue set up septic inflammation in the eye.

Extraction of the Lens without an Iridectomy should be conducted upon precisely the same lines as those above described, except, that we do not excise a portion of the iris; and the incision should be made rather more forward so as to be just within the margin of the cornea. There is less chance of prolapse of the iris after such an incision, and in order to gain a free opening through which the lens may pass, the point of the knife should be entered at a line corresponding with centre of the undilated pupil, the counter puncture being opposite and on exactly the same level.

Complications.—Various complications may occur at the time of an operation for extraction either with, or without an iridectomy. If while the section through the cornea is being made the aqueous escapes, the iris will probably protrude before the edge of the knife. Under these circumstances, the surgeon should make gentle pressure over the cornea with the point of his finger, so as to force the iris back behind the blade of the knife; but if this manipulation does not succeed, it is better to cut steadily on, and finish the section, excising a fold of iris at the same time. A portion of the iris being thus shaved off, a bridge of this structure is often left between the hole thus made and the pupil; this strip of iris should be divided before attempting to remove the lens.

If the section in the cornea is too small to allow the easy egress of the lens from the eye, supposing an iridectomy has not been performed, a portion of the iris is to be excised. It is a mistake to attempt to force the lens through the insufficient opening; any such endeavour will lead to trouble, the vitreous rather than the lens being squeezed out of the eye. In these circumstances, the opening in the cornea should be enlarged by means of a pair of blunt-pointed scissors, the incision being carried downwards, so as to leave an ample opening through which the lens may escape. Very gentle pressure should be made with the curette on the globe of the eye, so that in squeezing out the lens we may not press out the vitreous at the same time. If any of the vitreous escapes before the lens, we should at once cease pressure on the globe, and a scoop or a sharp hook passed through the wound, and the lens, if possible, gently withdrawn from the eye.

It sometimes happens that on making pressure upon the eye, the lens does not readily present itself in the pupil, in consequence of our not having sufficiently lacerated the cap-

sule, in which case the cystotome must be re-introduced, and the capsule fully opened. In most of these cases, however, it is an insufficient section in the cornea, and not the capsule of the lens which is at fault. But supposing that at the moment the lens escapes through the opening in the cornea, a gush of vitreous follows, the eyelids must be at once closed, and a compress and bandage applied over both eyes. The loss of a small quantity of vitreous from the eye is a matter of little consequence, and even a fourth of the vitreous may be lost, and yet the patient make a very good recovery; nevertheless, loss of vitreous may be followed by hyalitis, or by detachment of the retina.

After the section has been completed, if, on opening the eyelids we find that a portion of the iris is engaged in, or prolapsing through the wound, we should at once endeavour, by means of a gentle rotatory motion of the point of the finger over the closed eyelid, to return the prolapsed iris into the anterior chamber. If this method does not succeed, a spud may be employed to disengage the iris from the wound and return it into the anterior chamber.

After Treatment of Extraction of the Lens.—The operation having been completed, the stop speculum withdrawn, and the lids closed, before the patient rises from the recumbent position, a few drops of a fresh solution of eserine should be dropped into his eye. An ointment composed of vaseline $\frac{3}{j}$, iodoform gr. ij, should then be smeared over the skin, and along the edges of the eyelids. Several layers of absorbent antiseptic gauze, boracic seems to answer well, but perhaps cyanide of zinc and mercury gauze is still better, should be placed over the lids; outside this gauze, we must apply antiseptic wool, rising as high as the bridge of the nose and eyebrow, over the whole an elastic knitted bandage; our object is not to exert pressure on the eye, but to keep it closed and at rest; any tears or secretion from the eye are absorbed by the dressing. Both eyes should be treated for a week in the same way as regards dressings.

The bandage having been adjusted on the operating-table, the patient should be conveyed to bed, and directed to lie as much as possible on his back for the first few hours after the operation; he may then turn on either side, but not raise his head off the pillow, cough, or use any straining effort, and by no means disturb the bandages. There is no necessity to keep the patient in a dark room. If there is much pain in

the eye towards the evening after the operation, the bandage may be removed but not the dressings, for an hour or so; the surgeon should in these circumstances remain with his patient until the pain has subsided. If the pain continues, remove the dressings and draw down the lower eyelid, and drop a solution of atropine on to the everted conjunctiva, and then reapply the dressings. A subcutaneous injection of morphia also may be given. There will necessarily be some uneasiness in the eye after the operation, generally of a shooting, darting character, but in twelve hours or so this passes away if all is going on well with the eye. Pain in the eye is sometimes caused by the accumulation of tears under the closed eyelids (in spite of the absorbent dressings) and may be removed by gently everting the lower lid, from time to time.

With regard to diet, the patient from the day of the operation may have chicken soup, milk, or other fluids which can be poured into his mouth with a feeding cup; it is of importance not to allow him to rise from his bed, or chew any hard substance during the first twenty-four hours after the operation. Four days having passed, we may allow our patient more liberty; he may then sit up and begin to take solid food; in fact, if all has gone on well, he may now return to his usual diet, and in some cases beer or wine may be taken. Independently of prolapse of the iris, non-union of the corneal wound may result from depression of the patient's nutritive functions. To keep an old and feeble person upon "slops" for several days after extraction, for fear of inflammation, is contrary to common sense and sound surgical practice.

If at the expiration of two or three days, we remove the bandage, and find the eyelids of the eye operated on of a natural colour, not swollen, and free of discharge, the patient being without pain, we may be almost sure that all is going on well, opening the lids in such a case to ascertain the amount of vision the patient possesses is most injudicious.

The dressings must be worn for the first week or ten days after the operation, and then a bandage without a compress may be employed for a week more, and subsequently, if all is well, a shade can be substituted for the bandage. The patient should be kept in his room for some fourteen days, after which he can generally bear the light, and may be allowed to use his eye. A month having expired, we may order our patient suitable convex glasses, but the vision in the eye

operated on, continues in a favourable case to improve for two or three months after the operation.

Supposing the patient, within two days of the operation, suffers from considerable pain in the eye, and on opening the bandage we find the lids puffy and swollen, with a mucopurulent discharge oozing from between them, we know that our operation has not been aseptic, and have to fear purulent inflammation and suppuration of the cornea. If diffuse keratitis has begun, the conjunctiva will be found chemosed, the corneal flap may appear swollen and opaque, the edges of the wound infiltrated with pus, and the cornea hazy, if not opaque; this state of things is utterly hopeless.

It may be, however, that the suppurative action is limited to the part of the cornea included in the flap, in which case we may still hope to save the lower part of the cornea. A solution of corrosive sublimate 1 to 6,000 should be frequently applied to the conjunctiva, and cold compresses kept on the eyelids. Full doses of morphia should be given, so as to relieve the pain and irritation from which the patient suffers, and in fairly robust and healthy patients two leeches should be put on the temple over the affected eye for three consecutive days; we may have to administer port wine and beef-tea; but do what we will, we shall seldom succeed in saving an eye in these circumstances.

Subacute suppurative keratitis may commence in hyperaction in the iris, and may follow a flap extraction; this condition is most commonly met with in feeble patients, but is a complication of rare occurrence since antiseptic principles have been practised by ophthalmic surgeons. Within thirty-six hours of the operation, on opening the bandage, we notice some mucopurulent discharge oozing from between the lids; the patient probably complains of little or no pain in the eye, and the eyelids are not swollen, but on everting them the conjunctiva is found to be œdematous, and the cornea hazy, the pupil filled perhaps with yellowish lymph, and the upper section of the iris presenting spots of a similar kind on its surface; the edges of the wound are gaping open, and not the slightest sign of action or an attempt at reparation is apparent in the parts. Under these circumstances, we must order hot bandages, a firm compress, and above all the frequent application of a solution of corrosive sublimate to the eye. Stimulants and nourishment are often required and must be given freely in these cases.

Another danger which we have to fear after extraction without an iridectomy, is that a prolapse of the iris may occur. This accident may take place at any time within eight days from the operation, as the wound in the cornea will not have thoroughly healed until the first week is over, and till then, the iris may at any moment protrude through the section; a slight straining effort, such as a cough or sneezing, may be sufficient to produce this result. A prolapse having taken place, the patient will experience increased pain in the eye; the lids become slightly swollen, and a muco-purulent discharge is observed on the compress, or at the inner corner of the eye. On opening the lids, the cornea may appear to be clear, but the lips of the wound gape, and a portion of the iris may be seen protruding from between them. Under these circumstances eserine should be dropped into the eye and cocaine applied to the conjunctiva, the prolapse may then be touched with a pencil of mitigated nitrate of silver, and a firm compress and bandage applied over the closed eyelids, and kept there for twelve hours; the bandage may then be removed, and the lids bathed with tepid water; vaseline having been smeared over the eyelids, the compress and bandage should be re-applied. This treatment may be continued for a month or so, unless the prolapse has disappeared in the meantime; the caustic being employed from time to time. If, however, the patient does not object to an anæsthetic, and the prolapse is large, it is better under antiseptic precautions to perform an iridectomy immediately we discover the prolapse.

Iritis may come on within the first six days or more after an extraction; everything may seem to have been going on well until about the fifth day after the operation, when the patient complains of pain in the eye, and over the eyebrow or cheek; and on examining the eye we discover that the symptoms and appearances of parenchymatous iritis exist; cases of this kind must be treated on precisely the same principles, as those already described as appropriate for this form of iritis.

Another complication which may occur after extraction of the lens, is the rupture of some of the bloodvessels of the retina or choroid. The operation has, perhaps, been an easy one, but within a few minutes after the removal of the lens the patient complains of great pain in his eye, and to our dismay, on opening the lids, we find the anterior chamber not only full of blood, but blood oozing out through the

wound in the cornea. A case of this kind is hopeless; we can do no more than apply ice over the eye, so as to check the bleeding, but as an organ of vision the eye is destroyed. This accident may occur some hours after the operation, if the patient having diseased vessels happens to sneeze or coughs violently.

Erythropsia is a peculiar condition usually met with after extraction in which everything appears as if seen through a vivid blood-red glass, all objects are of a deep scarlet colour. It generally comes on some time after the removal of the lens, and is due to subjective colour sensations, in consequence of the dazzling caused by rays of light passing through a large coloboma or iridectomy.

After cataract or false membrane, a patient after the operation of extraction may have made a good recovery, but his sight remains very imperfect, and on dilating the pupil and examining the eye either by focal illumination, or with the ophthalmoscope, we find a film or bands of tissue behind the pupil, which prevent the rays of light reaching the retina. This condition arises from the growth of the epithelial cells of the capsule, and inflammatory products, into connective tissue. At the time of the operation the whole of the capsule not having been removed, the epithelium proliferates, and this together with some slight particle of soft lens matter adhering to it, form into a membrane, or it may be bands of connective tissue, which become more opaque as time advances. As this material becomes organized, it contracts, and often draws the edges of the iris or pupil together, forming the after cataract of extraction, which must be removed before the patient can possibly regain useful vision.

Considerable care is necessary in operating upon after cataracts; all irritation should, as a rule, have subsided in the eye before any attempt is made to break down these bands or membrane, and it is hardly likely, therefore, that we shall be able to operate under a period of two months from the date of the extraction.

The simplest plan of destroying these opaque bands, is to pass a needle through the cornea, the instrument having a cutting edge, so that we may be able to divide the false membrane. The patient having been cocainized, and laid on his back, a stop speculum is to be adjusted, and the eyeball fixed, an assistant seizing a fold of the lower part of

the conjunctiva with a pair of forceps. The surgeon then passes a needle through the cornea, and behind the capsule, so that it may be made to cut an opening through, or break down the opaque membrane; there is no necessity for passing the needle deeply into the vitreous; our object is simply to divide the opaque membrane without dragging on the contiguous parts, either of the capsule, or iris. It often happens, however, that bands, or a membrane of this kind do not yield to the needle, so that we cannot tear or break through it; in these circumstances a second needle is to be introduced through the cornea, at a point nearly opposite the first one; the points of the two needles; being passed through the centre of the membrane, they are widely separated, by crossing the handles of needles in this way a good sized central opening is made in the opaque capsule, without traction on the surrounding tissues. It is often better in these cases to make an opening in the cornea, and introduce the blades of De Wecker's scissors into the eye; one blade of the instrument is passed behind the false membrane, the other in front of the membrane, which is then freely divided; its edges generally retract at once, to such an extent as to leave a good opening for the passage of light into the eye. In some cases the pupil is completely closed by a false membrane. The communication between the anterior and posterior chambers being thus cut off, glaucomatous changes are apt to occur in the eye, indicated by supra-orbital pain and increased tension of the globe. In cases of this kind, if dividing the opaque membrane does not afford relief, we must perform an iridectomy in addition, or remove a further portion of the iris, if that operation had been practised at the time the lens was extracted.

The after-treatment in these cases consists in keeping the pupil dilated, and the eye at rest by means of an absorbent antiseptic pad and bandage.

LIEBREICH'S OPERATION FOR CATARACT.—The following is Mr. Liebreich's description of his operation:—

The incision of the cornea is to be made with the smallest possible Graefe's knife in the following manner.

Puncture and counter-puncture are made in the sclerotic about one millimetre beyond the cornea, the whole remaining incision passing with a very slight curve through the cornea, so that the centre of it is about one millimetre and a half distant from the margin of the cornea. This incision can be

made upwards or downwards, with or without iridectomy, and the lens can be removed through it with or without the capsule.

If, Liebreich observes, "as I now practise, the extraction is made downwards without iridectomy, the whole operation is reduced to the greatest simplicity, and does not require narcosis, assistance, elevator, or fixation; and only two instruments—namely, Graefe's knife, and one cystotome with Daviel's spoon."

LINEAR EXTRACTION.—The operation of linear extraction has undergone various modifications, and is now hardly to be recognized under its old name; it is, in fact, generally described as the Traction operation.

Gibson's Operation.—Linear extraction, as described by Mr. Gibson, is a proceeding which is seldom resorted to at present unless in cases of soft cataract. It consists in dilating the pupil and lacerating the capsule with a needle, as if operating for solution—only the capsule must be more freely incised. The aqueous, in consequence, gains access to the lens, and renders its already degenerated fibres still softer. Some four or five days after the needle operation, an incision is to be made through the cornea, so as to allow of the introduction of a curette into the anterior chamber; the instrument being now turned edgeways, so as to open the wound in the cornea, the soft lenticular matter escapes, together with the aqueous, from the eye.

The Linear or Traction Operation, as described by Messrs. Bowman and Critchett, is performed as follows. The patient having been laid on his back, and the stop speculum introduced, the surgeon fixes the eyeball with one hand by means of a pair of toothed forceps, and taking an iridectomy knife in the other, makes an opening through the corneo-sclerotic junction at its upper part.

The opening must occupy about a fourth of the circumference of the cornea, so as to allow the introduction of the scoop into the eye. In the case of a soft cataract there will be no necessity to make quite so large an opening as this.

The incision having been completed, a fold of iris is to be excised, as in iridectomy. Should there be any bleeding into the anterior chamber, the curette must be introduced between the lips of the incision, and slightly pressed upon the sclerotic edge of the wound. At the same time, the

tendon of the inferior rectus is seized with a pair of forceps, and the eye gently pulled downwards, so as to cause just sufficient pressure to squeeze the blood out of the anterior chamber.

The capsule of the lens is then to be lacerated freely—as possible, as far as the suspensory ligament; but that structure should not be broken through, if it is possible to avoid doing so. If much transparent cortical substance surrounds the opaque part of the lens, Sir W. Bowman inserts the point of the pricker into the lens substance, and then slightly rotates the body of the lens on its antero-posterior axis, so as to loosen it from the capsule. If this is not done, the cataract is very apt to adhere to the capsule.

The lens is then to be removed with a scoop or traction instrument, which is to be introduced through the wound in the cornea, and passed gently onwards between the capsule and the nucleus of the lens. The lens having been secured by the scoop, the instrument is to be withdrawn from the eye, and with it the lens. Any small portions of lenticular matter, which may be left behind in the anterior chamber, are to be carefully removed with the scoop or the suction instrument, and the eye is then to be closed, and a compress and bandage applied.

The Removal of the Lens in its Capsule.—This operation has been practised with varying success since 1773, and strongly advocated by Dr. Pagenstecher and M. Sperino; if it were possible in every case to remove the lens in its capsule, without damaging the other structures of the eye, we should, indeed, have reached perfection in the treatment of cataracts.

Atropine having been applied so as fully to dilate the pupil, the patient is to be laid on his back. The surgeon, standing by the side of his patient, applies the stop speculum; and the eye, being fixed with a pair of forceps, an upward incision is to be made through the *sclerotic*, immediately beyond the margin of the cornea, the same precautions being taken in making the section as we have already described in the case of ordinary flap extraction. A portion of the iris is then to be excised, and gentle pressure exercised with the curette upon the lower part of the sclerotic, and at the same time counter-pressure is to be made with the point of the fingers upon the upper part of the eyeball. In this way

the lens in its capsule may be gently forced out of the eye. If the lens is not readily displaced upon slight pressure being made on the globe of the eye, a shallow round curette may be inserted behind the lens, and a gentle traction exerted on the lens, so as to start it from its position.

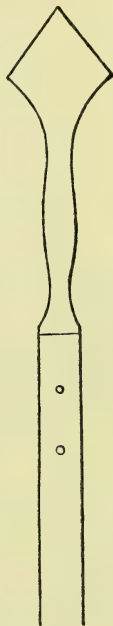In making the flap, we must keep slightly external to the margin of the cornea, so as to leave as large an opening as possible, through which the lens may escape, its bulk, when contained within the capsule, being considerable. Supposing there is a difficulty in extracting the lens in its capsule, the latter may be opened, and the operation completed as in ordinary flap extraction.

The operation to which we have referred, page 344, under the head of modified linear extraction, consists in making an opening in, and slightly behind the sclero-corneal margin at the outside of the eye. Through this opening the lens can be removed from the eye by means of a scoop, without rupturing the capsule and without an iridectomy.

The pupil having been fully dilated with atropine for two or three days before the operation, the patient is laid on his back, and placed completely under the influence of an anæsthetic. The operator adjusts a stop speculum, and carefully washes the surface of the eye with a solution of corrosive sublimate.

Supposing the right eye is to be operated upon, the surgeon standing behind his patient with a pair of fixing forceps, seizes a fold of the conjunctiva together with the tendon of the internal rectus, so as to have a steady, firm hold of the eyeball, and in the other hand takes a short and broad-bladed triangular knife (Fig. 55), and thrusts its point through the line of junction of the cornea and sclerotic, the blade of the knife is to be passed steadily onwards nearly up to its heel (Fig. 55), so that the incision made through the sclero-corneal junction is at least half an inch long. It is evident as the blade of the instrument is thrust into the anterior chamber, parallel to and in front of the iris, that

FIG. 55.



the extremities of the incision will extend further into the sclero-corneal junction, than the plane of its point of puncture (Fig. 56). The speculum and hold of the

FIG. 56.

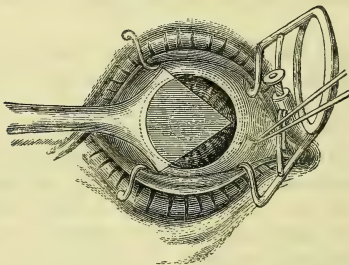


FIG. 57A.



FIG. 57.

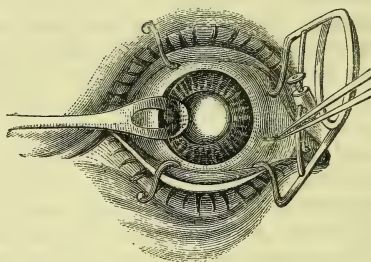
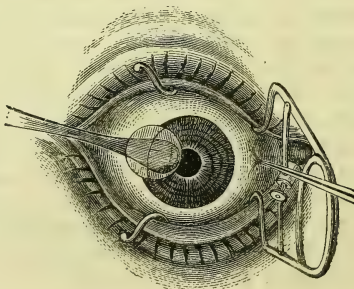


FIG. 58.



internal rectus being retained, the scoop (Fig. 57A) is to be inserted so far into the anterior chamber as to enable us to reach the margin of the pupil; the handle of the instrument being raised, and its rounded extremity depressed, the latter evidently rests on the capsule of the lens, immediately within the margin of the pupil. The scoop is now to be slightly withdrawn, still keeping its extremity on the lens, so as to open the pupil sufficiently to enable us to exercise gentle pressure upon the circumference of the lens with the extremity of the scoop; it frequently happens, when this is done, that the lens turns on its axis, and comes to rest in the concavity of the scoop, and may then be withdrawn from the eye. In other cases, if the lens does not readily shift its position and fall into the hollow of the scoop, the instrument may be inserted behind the lens (Fig. 52), until its bent and toothed extremity embraces the inner margin of the cataract; in this way the lens comes to lie in the scoop, and may be removed from the eye (Figs. 57 and 58), without rupturing the capsule. Should the capsule be ruptured, during the above-described manipulation, the lens substance may be withdrawn from the eye by means of the scoop.

Traumatic Cataract results as a rule from a wound of the capsule, but may occur from laceration of this delicate membrane in consequence of a blow on the eyeball. The capsule of the lens having been ruptured, its nutrition is interfered with and the entire substance of the lens may become opaque. It frequently happens that the cornea or sclerotic are cut through at the time the lens is injured, and in these circumstances micro-organisms are apt to find their way into the damaged structures, and set up active and probably purulent inflammation in the part. In the same way pieces of metal or other foreign bodies entering the eye, and lodging in the lens are likely to convey septic matter into this part, and cause violent inflammation in the surrounding tissues.

If only a small opening is made in the capsule with a clean instrument, a portion of the cortical substance of the lens may pass through it into the aqueous humour, and become absorbed; the wound in the capsule heals and a small cicatrix alone remains to mark the site of the original injury. If the opening in the capsule is more extensive but free of bacteria, it is still possible a partial cataract may form round the seat of injury, the rest of the lens remaining transparent.

But cases of this description are exceptional, for, in by far the majority of instances, if the capsule of the lens has been opened to however small an extent, the nutrition of the lens is interfered with, and it becomes opaque. During this process the cortical substance of the lens becomes swollen, some of it passes into the anterior chamber and may excite a considerable amount of irritation in the iris, and it may be acute inflammation; from septic infection the ciliary body and choroid are apt to become speedily implicated, to the great risk of the eye. Nor does the injury stop here, for the septic matter in such a case may pass along the lymphatic channels of the injured eye and affect the sound one. (See page 205.)

The only difficulty in diagnosing a traumatic cataract, is in obtaining a clear view of the parts after they have been injured. The patient having had previously good sight, receives a severe blow on his eye, it may be with some sharp-edged instrument, there is immediately intense pain in the eye, and so much surrounding swelling and ecchymosis, that it is difficult to obtain a clear view of the cornea. In these circumstances it is advisable to exercise patience, any force used to separate the swollen eyelids can only do harm. It is possible that the application of cold compresses to the injured eye, and syringing between the eyelids a four per cent. solution of cocaine and boracic acid, will reduce the irritation, and enable us in a day or two to examine the cornea and the parts behind it. If the lens has been injured, it will already have become more or less opaque, and may generally be recognized unless obscured by blood in the anterior chamber.

Treatment.—The treatment of a case of traumatic cataract will depend much on the condition of the lens and iris. Supposing only a small opening has been made in the capsule and that there are no symptoms of severe iritis, it is to this latter condition our attention should be principally directed, for we cannot determine the extent to which the capsule has been opened; moreover, it is to the iritis and its consequences, that the chief importance will be attached when considering the line of treatment to follow in a case of this kind. If then, although we find the lens has been injured, we can secure complete dilatation of the pupil, we may hope that the injured lens will heal, or if not, that it will gradually become absorbed. If the injury has been more severe, and

on opening the eye we find a wound of the cornea and prolapse of the iris, with an opaque lens occupying the pupil, it will still be advisable to order cold compresses and antiseptic lotions with cocaine, and to watch the progress of the case for a week or two, especially if the pain in the eye subsides, and the general condition of the parts improve; on the other hand should the pain in the eye be great, and if pus forms in the iris, it is inadvisable to continue palliative treatment; we have two courses open to us; either to remove the injured eyeball, or if there is a hope of saving the eye to administer an anæsthetic and perform an iridectomy, at the same time extracting the opaque lens matter. The result obtained after an operation of this kind, however, is generally at the best unsatisfactory, and if the sight of the injured eye has been completely destroyed, it is much safer to excise the globe before the other eye has become involved.

DISLOCATION OF THE LENS.—Dislocation of the lens may be either complete or partial; in the former, the lens is forced out of the eye through a wound in the sclerotic or cornea, but in partial dislocation the lens remains attached by some portion of the suspensory ligament; it may fall forwards, backwards, or to either side of its normal position in the eye.

1. *Complete Dislocation of the Lens* is most commonly caused by a blow, such for instance as that of a racquet-ball, or some such small and hard body by which the sclerotic is ruptured, usually at its inner and upper part, immediately beyond the margin of the cornea, and the lens escapes through the rent, and may lodge beneath the conjunctiva. An injury causing such a serious lesion of the eye as this is always complicated with more or less damage to the iris, which is usually torn from its attachment to a greater or less extent. Immediately after the accident the anterior chamber becomes filled with blood. On examining the eye, an opening through the sclerotic will be visible, and the lens may generally be recognized by its form and size beneath the conjunctiva. It soon loses its transparency, and then appears as an opaque body in the situation above indicated. In other cases, the lens is compressed in its passage through the rent in the sclerotic, and until it becomes opaque we may be unable to recognize it under the conjunctiva, or the lens may be driven completely through the sclerotic and conjunc-

tiva, and fall on to the patient's cheek. In India we frequently meet with cases of dislocated lenses, the work of native practitioners who perform the operation of "depression" for the cure of cataract. In too many cases the instrument employed is dirty, and purulent inflammation with an abscess of the eyeball follows the operation.

Treatment.—If the dislocated lens is still to be seen beneath the conjunctiva, it should be removed and the rent in the sclerotic closed, its edges being brought together with one or more fine silk sutures; the eyelids should then be effectually closed with antiseptic pads, and kept at rest until the irritation excited by the accident has entirely subsided. If then the patient's sight is found to have been completely destroyed the damaged eyeball should be removed.

2. *Partial Dislocation of the Lens.*—This accident usually occurs from a blow on the eye or forehead, the lens being partially torn from the suspensory ligament and displaced either upwards, downwards, or to either side; in some cases it is thrown forwards and rests partially or completely in the anterior chamber. Under these various circumstances, the patient's sight is more or less impaired, for the dislocated lens not only becomes somewhat hazy, but by bobbing about behind the pupil interferes considerably with the perfection of vision.

It does not always happen that the displacement of the lens immediately follows the receipt of an injury; several days may have elapsed since the accident, when from an effort of coughing or sneezing, the already damaged suspensory ligament is ruptured and the lens dislocated.

On examining the eye, supposing the dislocated lens is still held by a portion of the suspensory ligament, the pupil having been dilated with atropine, we shall observe the lens swinging about with every movement of the eye, its structure being slightly opaque, and the black chasm of the vitreous appearing behind that part of the lens which has been detached from the suspensory ligament. The iris, from the loss of support afforded it by the lens, is tremulous.

If the lens has been dislocated forwards into the anterior chamber, it may occupy the entire pupil, and remaining almost transparent there may be some little difficulty at first in detecting the nature of the injury. The light, however, being reflected by the circumference of the lens, presents a dark rim behind the cornea, the iris is pressed

back, rendering the anterior chamber larger than natural, and the pupil is dilated and motionless.

In cases of partial dislocation, if the lens is causing irritation, it is advisable to perform an iridectomy, and then to extract the dislocated lens by means of a scoop. We must be careful in operating, otherwise the lens will slip from the scoop, and fall back into the vitreous chamber.

CHAPTER XV.

DISEASES OF THE ORBIT.

Injuries of the Orbit—Diseases of the Bones—Inflammation of the Cellular Tissue—Orbital Growths and Tumours—Dislocation of the Globe of the Eye—Extirpation of the Eyeball.

INJURIES OF THE ORBIT.

CONTUSIONS AND FRACTURES.—A blow or fall upon the outer ridge of the orbit is usually followed by no other consequences than a “black eye,” but it sometimes happens that an injury of this kind causes a fracture of the orbital plate of the frontal bone. In cases of this description there is frequently considerable ecchymosis, which first appears beneath the conjunctiva of the globe of the eye; then beneath the palpebral conjunctiva, and subsequently in the integument of the eyelids.

PENETRATING WOUNDS OF THE ORBIT.—The first point to be ascertained in the case of a punctured or gunshot wound of the orbit, is as to the presence of a foreign body in the wound: our finger or probe will be the best guide in arriving at a conclusion on this point, and should we discover a foreign body lodged in the orbit, we must, if necessary, enlarge the external opening to such an extent as to enable us to remove it. Instances are recorded in which a bullet has remained embedded in the orbit for years, apparently without producing any ill effects; but in ninety-nine cases out of a hundred, unless the foreign body be removed, inflammation, and suppuration of the tissues of the orbit will ensue, and very possibly irreparable damage be done to the eye.

The second point to be noticed is the direction which the instrument has taken; if this be towards the brain, the case may be a most serious one, and our prognosis must be correspondingly guarded. The extent of the external injury cannot be relied on as an indication of the severity of the wound; in fact, on a casual examination no contusion may be detected in the skin, the eyelids having been open when the instrument inflicting the wound passed through the orbit and entered the brain. This point is forcibly illustrated by the following case, related by Mr. Guthrie. A boy was struck while at play with an iron wire in the right eye; there was no external wound to be seen, but there was considerable chemosis of the conjunctiva of the upper and inner part of the eyeball. Four days after the accident the patient complained of sickness and pain in the head; this was followed by restless delirium and coma, and on the sixth day after the accident the patient died. On examination, it was found that a piece of the iron wire had passed under the upper lid, and through the posterior part of the orbital plate of the frontal bone into the anterior lobe of the brain, which was softened and bedewed with matter. This case shows the extreme caution necessary in forming a prognosis under such circumstances.

If for twelve or fourteen days after the accident has occurred, no head symptoms have supervened, we may be hopeful as to the result, but the patient is not safe from ulterior bad consequences for some time afterwards.

GUNSHOT WOUNDS OF THE ORBIT, from a practical point of view, differ in no respect from punctured wounds, always taking into consideration the occasional unaccountable wanderings which a ball pursues in this, as in other parts of the body. As already directed in the case of other foreign bodies, the presence or not of the bullet in the orbit must first be determined, and then the direction it has taken ascertained; lastly, it is as necessary to remove a ball from this situation as any other substance. We occasionally meet with instances in which a number of small shot have penetrated the conjunctiva, and perhaps, glancing off from the sclerotic, have become imbedded in the cellular tissue of the orbit. In a case of this kind, all the shot that can be extracted without making a deep incision into the cellular tissue, should be removed; the remainder will become encysted, or in time make their way to the surface, and may then be extracted;

it is not advisable to search for them in the deeper structures contained within the orbit.

DISEASE OF THE BONES.

INFLAMMATION OF THE PERIOSTEUM of the bones of the orbit may be either acute or chronic and the symptoms to which it gives rise will accordingly vary in their intensity, and in the rate at which they advance. Periostitis in this situation most commonly arises from syphilis, either acquired or hereditary; it may result from an injury, or from exposure to cold. The periosteum of the external margin of the orbit is most frequently affected, a swollen, and on pressure, painful spot will be detected; but if the membrane towards the back of the orbital fossa is involved, it is more difficult to ascertain the nature of the disease. The patient usually complains of deep-seated pain in the orbit, which increases towards bedtime; the globe of the eye protrudes more or less from its socket; as the disease advances, the inflammatory action is likely to extend to the cellular tissue of the orbit, terminating in suppuration. In the earlier stages of periostitis so situated, if pressure be made with the point of the finger deeply into the orbit, we may probably detect a particularly painful spot corresponding to the diseased periosteum, and if nocturnal exacerbations of pain are well marked the patient having had syphilis, the diagnosis is in favour of a periosteal gumma.

It is sometimes difficult to form a diagnosis between acute periostitis of the deeper parts of the orbit and inflammation of its cellular tissue. In cases of periostitis, as above remarked, by pressure against the walls of the orbit we may reach one particular spot that is exquisitely painful; or by forcing the eyeball back into the socket, this tender spot may be indicated. Moreover, as the swelling of the periosteum and cellular tissue around it will at first be limited, the eyeball will be protruded in the opposite direction to that in which the inflammation is situated; for instance, if the periosteum in the upper part of the orbit is inflamed, the globe of the eye will be thrust downwards, as it also would be in the case of a tumour. In diffuse inflammation of the cellular tissue of the orbit, no one spot will be specially painful, and the protrusion of the eyeball will be more uniform; the skin

of the lids becomes involved, and the course of the disease is usually more rapid than in periostitis: nevertheless the diagnosis is often perplexing, but is simplified if the patient has a history of syphilis, when a course of mercury and full doses of iodide of potassium will in all probability relieve the symptoms.

Treatment.—If, from the intensity of the symptoms, we have reason to suppose that suppuration beneath the periosteum has taken place, we are justified in exploring the part with a grooved needle; and should we discover the presence of pus, we must at once cut down along the needle upon the collection of matter, and allow it free exit. If this is not done, destruction of the bone will surely occur, or, it may be, the inflammatory action will extend to the lining membrane of the skull. We need hardly remark that great caution should be exercised in making an incision into the orbit, on account of the complicated anatomy of the parts, but we are bound, nevertheless, to operate without hesitation. We have, in several cases of the kind, after exploring the part with a grooved needle, run a director along the groove of the instrument, and so torn open the cellular tissue, simply incising the skin to give exit to the pus.

In cases of periostitis connected with syphilis, full doses of iodide of potassium will control, if not cure the disease.

NECROSIS.—Necrosis of one or more of the bones of the orbit, as has just been remarked, may follow periostitis, or it may take place in consequence of direct violence, or from inflammation of the cellular tissue of the orbit, as in the following instance:—A man, of the name of Tait, was exposed to severe cold; the following day inflammation of the cellular tissue of the right orbit set in, and at the end of fourteen days a considerable quantity of pus escaped through an opening at the inner part of the upper eyelid. Ultimately a fistula formed in this situation, and small portions of necrosed bone constantly came away. When first seen, dead bone was felt in the roof of the orbit, the patient was blind with the right eye, and on making an ophthalmoscopic examination, the optic disc was found to be atrophied. The inflammatory action had attacked the cellular tissue of the orbit, and extending to the optic nerve, had caused atrophy of the papilla.

Treatment.—In instances of necrosis, unless exfoliation has taken place, it is better to wait until the dead bone has

separated, when it may be cut down upon and removed. The structures contained in the orbit are closely packed and of an important character; except, therefore, in instances unequivocally demanding the use of the knife, it is advisable to be as sparing as possible of its employment.

CARIES OF THE BONES OF THE ORBIT.—The following case affords an instance of the terrible mischief which sometimes results from this disease, especially under injudicious treatment:—

G. C. S., aged eighteen, admitted under my care into hospital on August 20. Up to within the last twelve months he had enjoyed good health, and been employed as a compositor; there was no history of either hereditary or acquired syphilis. A year ago he began to suffer from pain in the head, and shortly afterwards from a discharge of blood and matter from his nose; for this he was salivated, the ptyalism lasting two months; he also had leeches applied to his temples. Some time afterwards, on rising one morning, he discovered that he could no longer see with the left eye, and within a short time the sight of his right eye was destroyed. His digestive system and his mental faculties were perfect; he had lost the sense of smell. The right eyeball protruded considerably, and the cornea was hazy. There was a fistulous opening at the inner part of the left upper eyelid, and through this a probe could be passed far back into the orbit; no dead bone was felt. The left eye was less prominent than the right one, and the dioptric media were transparent; the margin of the optic disc was ill-defined, and, like the retina, looked cloudy; the retinal vessels of normal size. The patient gradually became weaker, he was troubled with severe pain in the head, and often had attacks of obstinate vomiting, but his speech and mental faculties remained perfect. Soon after his admission both eyeballs were observed to throb or pulsate in a most remarkable manner after the slightest exertion, for instance, on rising in bed; the pulsations being synchronous with those of the heart.

The boy died on the 18th of February; the whole of the orbital plate of the frontal bone, and the greater part of the body of the sphenoid had been destroyed by caries, so that nothing but the thickened dura mater intervened between the brain and the tissues contained in the orbital fossa; the pulsation of the globes was thus easily accounted for.

FISTULÆ.—Caries of the walls of the orbit is, fortunately,

by no means always so destructive as in the case of this lad; the disease is often confined to a small portion of the bones, and a fistulous opening forms between this spot and the skin, through which a thin watery fluid constantly oozes away, and the soft disintegrated bone may be felt with a probe.

The fistulæ thus formed in cases of necrosis and caries are frequently more troublesome to cure than the disease itself; the external opening is maintained by adhesions to the periosteum, and thus a puckered cicatrix forms, which often leads to eversion of the eyelid.

Openings of this kind are best treated by slitting up the fistula, and effectually scooping away the diseased bone and soft structures lining the sinus.

INFLAMMATION OF THE ORBITAL TISSUES.

INFLAMMATION OF THE CELLULAR TISSUE.—The cellular tissue contained within the orbit is occasionally the seat of acute inflammation and suppuration, but except as a complication of traumatic cases or periostitis this affection is rare; those instances that do occur usually arise from the spread of erysipelas to the part. Under these circumstances the eyeball itself generally escapes, but, unfortunately, the patient's sight is too often much impaired, if not destroyed, from the extension of the inflammatory action to the optic nerve, or from effusion into the retina and its detachment from the choroid. Occasionally the matter burrows into the sheath of the muscles, deranging their action and giving rise to diplopia. A much more serious complication is apt to occur in the course of this disease, in the form of septopyæmia and thrombosis of the cavernous sinus. This accident or complication is obviously more likely to occur, if the cellular tissue of both orbits are affected by erysipelato-inflammation.

The Symptoms of inflammation of the cellular tissue of the orbit are as follows:—The patient complains of a throbbing pain in the part extending to the temple, side of the head, and frequently to the muscles of the back of the neck; the pain is sometimes excruciating, and the patient is feverish and restless. The eyelids are swollen and of a dusky red colour, the conjunctiva becomes uniformly con-

gested and chemosed, and the eyeball is rapidly protruded to an uncertain extent, in consequence of the effusion that takes place into the cellular tissues of the orbit. The globe is usually thrust directly forwards, and not, as in periostitis and in the case of various tumours, with a certain deviation from the axial line, according to the direction of the compressing force. The cornea may remain bright and clear, or it may be that from exposure to the atmosphere, the secretions on its surface, and that of the conjunctiva, form hard dark crusts; the cornea becoming cloudy from desiccation of its epithelium, necrosis follows, and the eye is destroyed.

In the course of ten or twelve days from the commencement of the attack, we generally detect one or more points at which fluctuation can be felt, usually at the upper and inner part of the orbit. As soon as the pus has been evacuated, the pain and swelling diminish, the eyeball sinks into its socket, and the parts regain their normal position. But although the eyeball may not be directly destroyed by the inflammatory process, yet, as we have before remarked, in very many of these cases the optic nerve is more or less involved, and is subsequently apt to become atrophied; or necrosis of the bones of the orbit, or the formation of extensive cicatrices, may ultimately lead to atrophy of the globe.

In CHRONIC INFLAMMATION of the cellular tissue of the orbit the symptoms are less severe than those above described. The patients are generally the offspring of syphilitic parents.

The inflammatory process usually begins as a gumma in the periosteum, the patient complaining of pain in the part, increasing towards evening, and probably extending over the forehead. As the inflammation advances, the cellular tissue of the orbit becomes involved, the conjunctiva and lids are red and swollen, and the eyeball is thrust forward to a greater or less extent; the pain, however, is far less severe than in acute inflammation of the cellular tissue, on account of the gradually increasing pressure to which the parts are exposed. The protrusion of the eyeball in these cases is often considerable, and as their progress is slow, it is only by a careful study of the collateral symptoms that we shall avoid an error in our diagnosis. In cases in which a morbid growth causes the eyeball to protrude, its axis usually deviates from its natural position, according to the direction of the pressure occasioned by the tumour (*see* Figs. 48 and 59);

whereas in inflammation of the cellular tissue this is not the case. In doubtful instances we may further satisfy ourselves, as to the presence or not of pus in the orbit by the aid of a grooved needle.

The Treatment of inflammation in the cellular tissue of the orbit, differs in no respect from that of similar affections in other parts of the body. In the early stages of the more sthenic forms of inflammation in this situation, we may endeavour, by leeches and cold compresses constantly applied, to allay the action going on in the part, and to prevent suppuration; but if this does not succeed we must then employ poultices and hot fomentations. As soon as matter has formed, the abscess should be incised, the pus evacuated, and a drainage tube introduced, antiseptic dressing being subsequently employed.

If the case is complicated with erysipelas, antiphlogistics are not to be thought of; on the contrary, the patient's strength must be supported, the pulse, and the temperature of the body being our safest guides as to the amount of nourishment and stimulants required. Opium, or chloral hydrate, will be required to enable the patient to sleep; indeed, in the early stages of this form of the disease, there is no better practice than to give the system rest, and at the same time support the patient's strength with soup and stimulants, administering also the tinct. ferri sesquichlor.; we may thus hope to ward off the suppurative stage of the affection, or at any rate promote its speedy termination.

INFLAMMATION OF THE CAPSULE OF TENON occasionally occurs in rheumatic subjects; in other cases it is said to arise from injuries to the part, or it may be from extension of erysipelas from neighbouring structures.

Symptoms.—The subconjunctival tissue is deeply injected, but the iris is healthy, nor can we easily account for the persistent chemosis and injection of the vessels in question. The patient complains of slight pain in the eye, particularly when he turns the eyeball from side to side, but there is no impairment of vision; slight protrusion of the eye may occur, and the mobility of the globe be impaired, so that diplopia may exist. The symptoms usually disappear under treatment.

Hot compresses generally give the patient much relief, combined with the administration of iodide of potassium in large and repeated doses.

ORBITAL GROWTHS AND TUMOURS.

EXOPHTHALMOS, or protrusion of the eyeball, may be conveniently considered under two heads:—

1st. Protrusion of the eyeball arising from an increase in the contents of the orbit—as, for instance, from a tumour.

2nd. From diminution of the cavity of the orbit, by the encroachment of its walls upon the eyeball—as, for example, in cases of bony tumours springing from the walls of the orbit, or from an abscess of the antrum forcing the inferior wall upwards.

EXOPHTHALMIC GOITRE.—Among the most remarkable affections of the orbit included under the first heading, is exophthalmic goitre, described by Dr. Graves, and more fully elucidated by his friend, the late Professor Trousseau, in his admirable clinical lectures. He considers that exophthalmic goitre arises from a neurosis of the sympathetic, resulting in local congestions, the proximate cause of which is an alteration produced in the vaso-motor apparatus. “It is a morbid entity, because it presents special phenomena; palpitation, and congestion of the thyroid gland and of the eyeballs. It is a pathological variety of the great class of neuroses, with a paroxysmal course, and should be regarded as entirely distinct from ophthalmos due to organic diseases of the heart, while it cannot be confounded with goitre proper.”

Dr. T. Laycock states that exophthalmic goitre occurs under a variety of morbid conditions of the nervous system. When the exophthalmos is symmetrical, it is spinal, the cervical and dorsal regions of the spinal cord being the seat of the disease, together with the corresponding cervical and dorsal divisions of the sympathetic; but when unsymmetrical it is due to disease of the trigeminal ganglion, and branches of the fifth pair. In either case, it seems probable that from irritation of the sympathetic, hypertrophy of the adipose tissue, and dilatation of the veins of the orbit occur. Sattler on the other hand believes, and we agree with him, that this affection is due to a lesion of the vaso-motor centre, or in some portion of the brain which directly governs the vessels both of the thyroid and orbital contents.

Exophthalmic goitre is almost confined to the female sex. Out of fifty cases referred to by Withusen, only eight

occurred in men. It may be induced by moral causes, or by privations which have produced excessive anæmia.

Symptoms.—The symptoms of this disease are, in the first instance, nervous irritability, a sensation of fulness in the head and face, violent palpitation, usually coming on in paroxysms. In the case of female patients, menstruation generally becomes disordered. Some enlargement of the thyroid gland generally occurs, and protrusion of the eyeballs, alike on both sides, commences. This may be very gradual in its progress, and is preceded by obvious changes in the integrity of the muscular apparatus of the eyes, their axes being inverted; the eyes have also a staring expression due to retraction of the upper eyelid; the lid fails also to follow the movements of the globe of the eye as the plane of vision rises and falls—it remains too much elevated, so that when the eyeball is directed downwards more or less of the sclerotic is exposed. The eyeballs continue mobile, but may in time become so far protruded as to prevent the patient from closing the eyelids over them. In other instances, the eyeballs are only slightly protruded; but their lustrous appearance, the enlargement of the thyroid gland, together with palpitation and other nervous symptoms, are pathognomonic of the malady.

The affection does not depend upon disease of the heart, although palpitation exists, and frequently a systolic (anæmic) murmur at the base, but no structural changes, as a general rule, can be detected in this organ. The patient complains of shortness of sight, and difficulty in keeping her eye fixed on any one object, but beyond this there is seldom any impairment of vision. The ophthalmoscopic appearances of an eye affected in this way indicate congestion of the retina and choroid; but the dioptric media may remain transparent.

Prognosis.—In some cases, after a very considerable interval, exophthalmic goitre gradually disappears of itself, the patient's general health improves, the palpitations and other nervous symptoms from which he suffered abate, and the enlargement of the thyroid gland, and protrusion of the eyeballs, subside. Suppuration of the cornea and destruction of the eye may, however occur from the exposure of the uncovered cornea to the air, or it may be due to paralysis of the trophic fibres of the fifth nerve. On the other hand, if the anæmia increases the disease becomes a most formidable

one, requiring the greatest care with regard to diet, and, above all, freedom from mental anxiety and worry.

Treatment.—From the foregoing history of this malady, we learn that it is no mere local affection, and the remedial measures we adopt must therefore be mainly directed to restore the general health and secure rest of mind. As the large majority of cases occur in women, and are attended with catamenial derangement from their commencement, and often with anæmia, our treatment should be further directed by attention to these special features.

Trousseau recommends a judicious use of hydropathy, among other measures, as likely to improve the patient's general health; and he regards this as being the best and only rational plan of treatment in such cases. Galvanization of the cervical sympathetic with a weak ascending current, not only lessens the size of the thyroid gland, but seems to exercise a favourable influence on the course of the disease. A firm compress and bandage may be employed with advantage over the closed eyelids, especially if the cornea becomes at all hazy. Should the retraction of the upper lid be very marked, the following operation has been proposed. The horn spatula having been introduced beneath the lid to be operated on, a horizontal incision is to be made through the skin of the lid above, and parallel to the upper border of the tarsal cartilage. A portion of the fibres of the orbicularis muscle, and subjacent fascia, is to be divided so as to expose the levator palpebræ; and those fibres of this muscle which pass over and into the tarsal cartilage are to be very carefully cut through. An incomplete ptosis results, but this gradually diminishes, and neutralizes the retraction of the lid, if the operation is successful.

CYSTIC TUMOURS growing within the orbit are another cause of exophthalmos. In this situation, such tumours are usually attached to some portion of its bony wall. It is almost impossible, before operating, to ascertain the exact connections or depth to which these cysts extend within the orbit; they may possibly extend backwards through the optic foramen.

Symptoms.—Cystic tumours in this situation usually increase in size very slowly, and without causing the patient pain or much inconvenience, until they attain a considerable bulk and begin to displace the eyeball, forcing it forwards in the opposite direction from that in which they grow. When they have reached this size, on everting the lids, the cyst may

generally be seen projecting from between some part of the orbital walls and the eyeball; follicular cysts enclose sebaceous-like matter, when no fluctuation can be detected; in doubtful cases, we should do well to use the aspirator or grooved needle before deciding as to the nature of the disease.

The Treatment to be pursued in instances of this kind is by no means so simple as might at first sight appear. It may be well to draw off the contents of the cyst, if fluid, by means of the aspirator, but it will refill; and if the cyst is a large one, hæmorrhage may take place into it, and suppuration ensue. As a rule the better course is to remove the cyst, as far as practicable. Should it extend so deeply into the orbit as to prevent our taking it away entire, we must content ourselves with removing as large a portion of it as possible. To do this, a sufficiently large incision must be made through the lid to expose the tumour fully, and allow the cyst to be dissected away from its attachments. Or, if it should seem more desirable, the outer canthus may be slit up and the lid everted with the same intention.

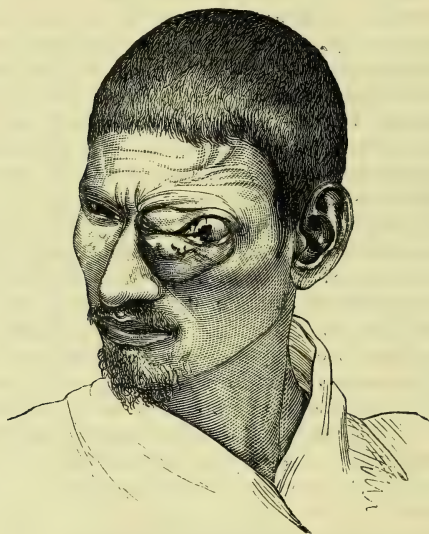HYDATID CYSTS of the orbit are occasionally met with, and these, as they increase in size, must necessarily displace the globe of the eye. If the tumour projects between the orbital walls and the globe of the eye, it may be felt as a firm, elastic swelling; and as it generally yields an obscure sense of fluctuation, the case may closely simulate one of chronic abscess. The aspirator will settle the point; a colourless limpid fluid, containing echinococci, being drawn off by the instrument. In these cases the cyst must be opened, and the included bag should, if possible, be removed; this done, the cavity in which it has grown will probably close up and cicatrize.

SANGUINEOUS CYSTS (Lymph-adenomata) are occasionally met with in the orbit, either of spontaneous origin, or as the result of an injury. It is almost impossible to discriminate between a tumour of this description and an ordinary cyst, unless by means of the exploring needle or the aspirator. The symptoms and progress of these tumours differ in no respect from those of other cystic growths. The whole of the cyst should, if practicable, be removed.

SARCOMAS are not of unfrequent occurrence in the orbit, and they usually grow from the periosteum. A sarcoma may take

a long time to grow, and in the first instance be mistaken for a node; but the absence of a syphilitic history would lead us to dismiss the idea of periostitis, while the smooth and softer surface of the growth precludes the supposition of an exostosis. As the morbid growth increases in size, exophthalmos, or displacement of the eyeball occurs, and gives rise to diplopia. (Fig. 55.) These tumours have often extensive attachments to the walls of the orbit, although they may only appear as a small, hard, and nodulated mass upon an external examination. If allowed to remain undisturbed they continue steadily

FIG. 59.



(From a photograph.)

growing, the skin covering them in course of time ulcerates, an open sore is established, and the patient's health gradually fails. The following case illustrates the history of a case of this kind:—

S. D., aged thirty-two, states that he had a small tumour removed from near the inner angle of the left eye, about four years ago. We could obtain no clue to the nature of this morbid growth. A year after the operation a tumour again

commenced growing in the same situation; it caused him no pain.

“At present a morbid growth is seen situated towards the inner part of the orbit (Fig. 59). It has evidently deep-seated attachments, and feels hard to the touch; the skin is not involved. The left eyeball is displaced by the tumour an inch outwards, and fully one inch forwards, from its normal position; nevertheless, the eye moves in unison with the other one, and its sight, for both near and distant objects, is perfect. The patient's general health is good, and no enlargement of the glands of the neck exists.

“After making the necessary incisions through the skin, and exposing the tumour, we found that it was attached to the lower and also to the inner walls of the orbit; it was consequently removed, together with a considerable part of the bones with which it had been united. Lastly, the wound was filled with lint soaked in the chloride of zinc paste. The cornea became hazy immediately after the application of the paste, and subsequently sloughed, the eyeball collapsing; but, excepting this loss of the eye, the case progressed favourably, and the wound healed and cicatrized. Four years subsequently this patient returned to the hospital; a small bleeding fungoid mass was growing from the site of the original tumour, the glands of his neck were enlarged.”

In undertaking an operation for the removal of a tumour of this description, we must be guided by the history of the case, should the morbid growth have increased rapidly, Dr. C. S. Bull, of New York, remarks, if the “bones of the orbit are involved, operative interference should not be attempted—the small amount of good attained by an operation is but temporary, and is far outweighed by the dangers of the operation, the severity of reaction, and the rapid recurrence of the growth.” On the other hand, if the tumour has increased in size very gradually, taking perhaps years to grow, we are justified in removing it, and destroying the surface of bone from which it originated, by means of the chloride of zinc paste.

OSTEOMA, OR EXOSTOSES OF THE ORBIT, may grow from any part of the walls of the orbit; they most frequently present a nodular form, and are of an ivory-like texture. Sir James Paget is of opinion that they usually originate in the diploë or neighbouring sinuses, as isolated or narrowly at-

tached masses ; their tendency being to extend in all directions.

— *The Symptoms* to which an exostosis in the orbit gives rise, will vary somewhat with its position, and the rate at which it grows. The globe of the eye is pushed forwards before the morbid mass, and protrudes to a greater or less extent from its socket. Pain is by no means a prominent symptom in these cases, and frequently we hear no complaints of it from the patient. As soon as the tumour attains a considerable size, it may be felt as a hard, rounded, or spiculated mass attached to the bone, sometimes by a broad base, at other times pedunculated.

Treatment.—It is seldom possible to remove these bony tumours of the orbit, in consequence of their tendency to penetrate into the skull. Nevertheless, instances have been recorded in which tumours of the kind have been cured by Nature, the ivory-like mass sloughing away ; and it may be well, as Sir James Paget remarks, to expose tumours of this description, by making incisions through the soft parts covering them, and applying, if need be, escharotics to the surface of the bone.

ANEURISM OF THE OPHTHALMIC ARTERY is said to have been met with occasionally. The quick development of such a tumour, causing the eyeball to be considerably protruded, its pulsating character, accompanied by an aneurismal bruit distinctly audible on placing the stethoscope above the supra-orbital ridge, together with the absence of symptoms indicating any other form of disease—these features would appear to be sufficient for the purposes of diagnosis ; but we shall see hereafter that in cases of this kind, we can never speak very confidently as to the exact seat of the lesion. The only treatment we can adopt, with any hope of success, for the cure of an aneurism so situated, is to apply a ligature round the corresponding common carotid artery. We should hesitate, however, to have recourse to so serious an operation, unless pressure made upon the artery either stops, or at any rate lessens, the pulsation of the globe.

A DIFFUSED ANEURISM has been known to form in the cellular tissue of the orbit, as in other parts of the body, in consequence of an injury, or spontaneously from disease and rupture of a vessel and effusion of blood into the cellular tissue of the part, producing some slight exophthalmos. As

the protrusion of the globe increases, the vessels of the conjunctiva become congested and swollen, and the movements of the eyeball are impaired. The eyeball pulsates, and the arterial souffle may be heard in its neighbourhood; this may be stopped if the eyeball be gently pressed back into its socket, and the pulsation of the globe ceases at the same time, to be renewed the moment the compressing force is removed. If the pressure is discontinued, the eyeball slowly protrudes to the same extent as before the compression was made.

Should the symptoms make their appearance after an injury to the part, we should be led to suppose that an effusion of blood has taken place in the loose cellular tissue of the orbit, and that the clot, having been partly absorbed, has left an aneurism communicating with the injured vessel. In other instances similar changes are said to have occurred after a severe strain, probably not noticed by the patient at the time, but which has caused the rupture of an artery already in a diseased condition, and thus given rise to an aneurism. On the other hand, we must remember that pulsating tumours of the orbit may occur in consequence of a fracture of the base of the skull, involving the internal carotid artery in the cavernous sinus, and giving rise to symptoms such as those we have above referred to; in fact, increased pulsation of the ophthalmic artery or its branches, as well as obstructions in the ophthalmic vein or cavernous sinus, will produce pulsation of the eyeball, as will a rapidly growing sarcoma.

The Treatment of false aneurism in this situation will be the same as that of true aneurism, and consists in tying the corresponding common carotid artery. Digital compression of the carotid has proved successful in a few cases; in one recorded instance it was continued for fifty-six hours without avail. It is advisable when practicable under these circumstances, to raise the carotid and compress it between the fingers, rather than attempt to fix it against the spine. But little dependence can be placed on other remedial measures, yet a remarkable case of aneurism successfully treated by the administration of ergot and veratrium, is reported in the *Ophthalmic Review*, vol. i., p. 288.

ERECTILE TUMOURS may form in the cellular tissue of the orbit; they are painless growths, and usually increase slowly, the patient's health remaining unimpaired. As the vascular tumour augments in volume, it causes more or less exophthalmos, and the prominent eyeball has a pulsating movement

imparted to it; on gentle backward pressure being exercised on the globe of the eye, the eyeball may be made to recede into its normal position. The size of the tumour increases if the patient makes a straining effort, as in crying. If the erectile mass projects forward beneath the conjunctiva, the colour and general characters of the morbid growth will be more apparent, and render the diagnosis comparatively easy.

Treatment.—A case of this kind is probably best treated by ligature of the carotid, unless the erectile tumour is of small size; we may then be justified in attempting to obliterate the vessels, by means of injections of perchloride of iron, or tannic acid, into the morbid growth; but great care is necessary in a proceeding of this kind, for it is hardly possible to limit the extent or direction in which the injected fluid will run, or to prevent it entering some of the larger vessels; the galvanic cautery would seem to be well adapted for the treatment of erectile tumours in the orbit, a small portion of the growth being dealt with from time to time.

To the foregoing account of vascular tumours in the orbit, it should be added, that they are very rarely met with, and their diagnosis is at all times difficult and uncertain. Cases of pulsating, vascular protrusion of the eyeball, exhibiting most of the features above described, as characteristic of those affections, sometimes present themselves; but in most of them it is doubtful whether the disease is really within the orbit. Several cases of supposed orbital aneurism have proved to be of a different nature, when the opportunity has been afforded of correcting the diagnosis by a *post-mortem* examination, and hence the unavoidable inference that others may have had no better claim to be so regarded. Mr. Nunneley, who has had an unusually large experience in such cases, believes that aneurism within the orbit, whether true or diffuse, is almost unknown. He remarks, that in a large majority of instances of "vascular protrusion of the eyeball, there is no disease whatever in the orbit; the seat of it is mostly intra-cranial. The protrusion of the eyeball is passive, and the other distressing symptoms are secondary, depending on obstruction to the return of the blood through the ophthalmic vein." Cases are recorded in which all the symptoms of orbital aneurism have arisen from compression of the ophthalmic vein, preventing the passage of blood from the orbit, as for instance, an aneurism of the ophthalmic artery near its origin. It is satisfactory, however, to know that, whether the seat of

the tumour be within the orbit or not, the treatment will be the same, and that ligature of the carotid has been successfully practised under these circumstances.

A case, which forcibly illustrates Mr. Nunneley's observations, has been recorded by Mr. Hulke. The patient, five months after receiving a blow on the left side of the head, presented all the capital signs of an orbital aneurism—fulness of the left orbital region—protrusion and pulsation of the eyeball—a distinct sibilant bruit heard extensively in the neighbourhood. The common carotid artery was tied, but the patient subsequently died, and on making a *post-mortem* examination, phlebitis of the cavernous, transverse, circular, and petrosal sinuses was discovered.

EXOPHTHALMOS FROM COMPRESSION OF THE ORBIT.—The cavity of the orbit may, as we have before remarked, be encroached upon by pressure from without as well as by growths from within. In some remarkable cases of chronic hydrocephalus, the accumulation of fluid within the cranium has been known to force the orbital plate of the frontal bones downwards and forwards, causing the eyeballs to protrude so far from their sockets as to prevent the lids from closing over them. It would be useless to dwell longer on the description of such cases as these, as their nature must be at once apparent.

Abscess of the Frontal Sinuses.—Distension of the frontal sinus is generally caused by a blow on the face which has fractured some of the anterior ethmoidal or frontal cells, and so induced a closure of the infundibulum, preventing the escape of mucus from the sinus into the nares. The secretion of the frontal sinus being in this way retained, gradually accumulates and expands the sinus, often to a very considerable extent. If the malady cannot be traced to an accident, we may assume that closure of the infundibulum has taken place as a result of disease. The symptoms may be either those of active inflammation, or of a chronic character: in the former case the patient complains of great pain over the brow and root of the nose, the frontal sinus becomes rapidly distended with pus and may burst, the pus finding an exit into the nose or upper part of the orbit. When the latter accident occurs, the abscess protrudes from the inner and upper part of the orbit, pushing the eye in the opposite direction. The upper lid is much inflamed, and the pro-

trusion is very tender; fluctuation may ultimately be felt in it.

In chronic cases of this disease there may be little or no pain, or other symptoms of inflammation; but the gradual formation of a tumour, at the upper and inner part of the orbit, protruding the eyeball downwards, outwards, and forwards. The disease is usually confined to one sinus, but may attack both.

If, from the bulging condition of the frontal bone and pain in the part, we are led to believe that the sinus is so distended with fluid, it will be advisable to cut through its bony walls and allow the pent-up matter to escape.

In a case recently we followed out with complete success the plan of treatment recommended by Mr. G. Lawson. He says:—A single curved incision parallel with the fold above the lid is to be made over the most prominent part of the tumour, and having by a little dissection exposed its surface the scalpel should be plunged into it, and an opening made to the extent of the incision. The index finger of the right hand is now to be pushed into the sinus through the wound, to ascertain the size of the cavity and if there is any necrosed or carious bone. Whilst thus exploring the sinus, the little finger of the left hand should be passed up the corresponding nostril, and an endeavour made to find out the spot at which the tip of the finger in the sinus will approximate most closely the end of the one in the nose. After a little search it will be found that at one part the fingers will almost meet, there being only a thin plate of bone between them. Having gained this information, the finger in the frontal sinus is to be withdrawn, but that in the nostril is to be retained *in situ* to act as a guide to the gouge or elevator, which is to be passed into the sinus and made to force a passage into the nose through the lamina of bone on which the tip of the little finger is resting.

A communication between the frontal sinus and the nose having been thus established, a drainage tube is to be introduced, one extremity of which is to be afterwards fastened on the forehead, whilst the other end protrudes slightly from the nostril. The easiest way of introducing the drainage tube is to pass a probe with an eye up the nostril and out of the wound, and having fastened the tube to it by means of a piece of string, to draw it back again through the nose. The object of the drainage tube is to keep the channel

between the two cavities from closing, and to enable the attendant to wash out the frontal sinus at least twice a day with some astringent and disinfectant solution. For the latter purpose the *lotio alum. cum zinc. sulph.*, or the *lotio acid. carbol.* may be injected with a glass syringe through one of the openings at the upper extremity of the tube. The drainage tube should be worn for five or six months, or until all discharge from the nose had ceased. The results of these cases when thus treated are usually most satisfactory.

Hydatid cysts and polypi have occasionally been met with distending the frontal sinus.

From Diseases of the Antrum.—The orbital fossa, however, is more frequently encroached upon from below than from any other direction, in consequence of malignant growths, or the accumulation of fluid within the antrum, forcing the orbital plate of the maxillary bone upwards. Abscess of the antrum or an accumulation of its natural secretion from closure of the passage leading into the nose, may distend the walls of this cavity to such an extent, that the hard palate, cheek, and orbital plate of the bone are thrust outwards; and in this way the orbital fossa may be so far encroached upon, as to occasion some protrusion of the eyeball.

A polypus growing from the walls of the antrum, or from the nostril, may, by its gradually increasing size, so far displace either the inner or inferior wall of the orbit, as to lessen the dimensions of the orbital fossa. In these cases the distortion of the face will render the diagnosis comparatively easy; mistakes however do occur: Mr. Poland relates an instance in point; he says, "Only a short time back there was a case where excision of the eyeball was actually proposed for this affection, when it was discovered that the protrusion was due to an abscess in the antrum, which was opened, and the eye saved and resumed its natural place." Such a history as this shows a want of forethought and consideration against which it is impossible to arm individuals, however profuse or practical our rules may be.

The following table drawn up by Mr. Poland exhibits the causes of protrusion of the eyeball:—

Causes of Protrusion of the Eyeball—

- | | | |
|----------------------|-----|---|
| 1. Congenital | ... | { 1. <i>Real</i> protrusion. |
| | | { 2. <i>Apparent</i> —from shortening of levator palpebræ and lids. |
| 2. In the eye itself | ... | { 1. Inflammation of globe, ophthalmitis. |
| | | { 2. Phlebitic ophthalmitis. |
| | | { 3. Hydrophthalmos. |

Causes of Protrusion of the Eyeball—*continued.*

- | | | | | |
|--|-----|--|-----|--|
| 2. In the eye itself—
<i>continued.</i> | } | 4. Tumours in eye | { | 1. Sarcomas.
2. Carcinomas.
3. Hydatid. |
| 3. Within orbit | ... | 6. Tumours | ... | { |
| | | | | 1. Encysted.
2. Hydatid.
3. Sarcomas.
4. Osseous. |
| 4. External to orbit | } | 1. Inflammation of cellular tissue—idiopathic and traumatic.
2. Suppuration and abscess.
3. Erysipelatous and phlegmonous inflammation.
4. Foreign bodies.
5. Excess of development of fat.
7. Aneurism and effusions of blood.
8. Venous congestion; exophthalmic goitre.
9. Paralysis of muscles of eyeball—ophthalmoplegia.
10. Spasm of muscles of eyeball, as in tetanus.
1. Above—Nodes, hydrocephalus, fungus of dura mater, polypi in frontal cells and diseases thereof, tumours of brain, inflammation and diseases of lachrymal gland.
2. Below—Diseases of the antrum.
3. Internal—Nasal polypi and tumours.
4. External—Exostosis.
5. In front—Contraction of lids, and eyes slipping through, hernia oculi. | | |

DISLOCATION OF THE EYEBALL.

Dislocation of the eyeball exists when the eye has been forced out of the orbit, as for instance, by a foreign body being thrust between it and the orbital walls. We saw an instance of this kind not long since. The patient was a sailor, and in a quarrel with a comrade had had his left eye gouged out. The eyeball was hanging down on the poor fellow's cheek, and as the whole of the tissues at the posterior part of the eyeball had been torn from their attachments, and with them apparently the optic nerve, it was useless attempting to save the eye.

Cases are on record, however, where an eye has been dislocated, the patient, for the time being, having entirely lost his sight, but on the eye being replaced in its socket vision has been restored. Except therefore in cases where we have evidence that the optic nerve has been divided, it will be well to separate the eyelids and restore the dislocated eye to its socket. A firm compress and bandage should subsequently be applied over the closed eyelids, so as to keep the eyeball in its place. If at the end of four or five days the patient has no perception of light, it will be advisable, if practicable, to examine the eye with the ophthalmoscope, and should the retina be detached from the choroid, or the optic disc atrophied, it would be useless attempting to save the eye, and better to extirpate it at once, substituting an artificial eye.

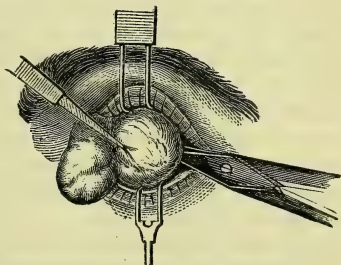
If, on the other hand, the patient has the least perception of light, four or five days after the accident in the injured eye, we must retain it in its place by a pad and bandage for three weeks or so. The firmer the compress can be worn the better, the eyeball being forced back into the orbit by this means, and giving the divided muscles the best opportunity of forming adhesions near the anterior part of the eyeball, so as to reduce, as far as possible, the amount of exophthalmos and diplopia which must result from an accident of this kind.

EXTIRPATION OF THE EYEBALL.

Extirpation of the eyeball may be rendered necessary by the presence of foreign bodies in the eye, or other injuries; by staphyloma, sympathetic irritation, and other diseases. The operation is performed as follows:—

The patient having been laid on the operating table and an anæsthetic administered, a stop speculum or retractors are introduced, so as to keep the eyelids well apart. A fold of conjunctiva having been laid hold of with a pair of forceps, the mucous membrane, sub-conjunctival tissue, and capsule of Tenon are to be cut through all round the cornea, with a pair of slightly curved scissors, so as freely to expose the sclerotic; the straight and oblique muscles are then to be divided close to their insertion into the sclerotic, with a few strokes of the scissors; this manœuvre is facilitated by dragging the eyeball in the opposite direction to that of the muscle whose tendon we are about to divide; or we may take up each of the recti muscles on a strabismus hook, and divide them one by one. The eyeball being thus separated from its muscular attachments, is to be seized and drawn well forward; the curved scissors may then be passed behind it (Fig. 60), and the optic nerve divided close to the sclerotic, together with any other structures which prevent our entirely removing the eyeball.

FIG. 60.



As a rule the bleeding after this operation may be arrested, by means of pressure kept up for a few minutes by an assistant, with a sponge thrust into the cavity from which the eyeball has been removed, and no arteries will have to be tied; but it is well to have ice at hand in case of hæmorrhage. The stop speculum having been removed, a sponge or pad of wet lint is to be applied over the closed eyelids, and retained there with a light bandage round the head. The use of sutures to bring the edges of the conjunctival wound together are unnecessary, and likely to set up irritation; compresses of lint or a sponge inserted within the orbit, except for a few minutes as above directed, after the removal of the globe, are not called for to restrain hæmorrhage, and are consequently only to be employed in exceptional cases to stop excessive bleeding.

The subsequent treatment of these cases consists in keeping the parts clean, and to do this properly it will be necessary to open the eyelids from time to time, and syringe out the wound with a weak solution of carbolic acid; or a solution of corrosive sublimate.

It will be noticed that in this operation the globe of the eye is removed from within the capsule of Tenon, without wounding the cellular tissue of the orbit; the muscles, nerve, and, in fact, the attachments of the eyeball being divided close to the sclerotic.

ARTIFICIAL EYES.—An artificial eye is made of a hollow hemisphere of enamel, coloured so as to resemble the front of the other eye.

It was formerly the practice in removing the globe of the eye to cut wide of the sclerotic, and in fact to take away the greater part of the contents of the orbit. One of the advantages of the operation of excision, as now performed, is, that the capsule of Tenon, with the attachments of the muscles, is left in the orbit, and forms a movable stump upon which an artificial eye may rest, and thus move in harmony with the sound one. A still better support is afforded by the operation of abscission, previously described. (Page 145.)

In some cases, after the eye has been destroyed by purulent conjunctivitis or other causes, we may with advantage fit an artificial eye over the atrophied eyeball. Care is necessary in adapting the artificial eye to the requirements of individual

cases, and this can best be done by the manufacturer; or a cast of the outer part of the orbit may be made and forwarded for his guidance. Under any circumstances, the false eye should not be worn until all inflammation and irritation have disappeared. In introducing it, the upper eyelid must be raised, and while the patient looks downwards, the upper border of the artificial eye should be pushed beneath the lid, which is then allowed to fall: and the lower one being in turn depressed, a little manipulation is sufficient to make the remaining portion of the eye slip into the lower palpebral sinus.

In removing the artificial eye, the lower lid must be everted, and the thumb-nail, or the point of some instrument, may be introduced under the lower edge of the eye; it is thus lifted away from the remains of the globe, and falls down into the open hand, or upon a soft cushion ready to receive it. After being withdrawn, the artificial eye should be dipped in water and cleansed. Under any circumstances it is liable to get corroded and rough in course of time, and then sets up much conjunctival irritation. Whenever this is the case, or if, independently of changes in the surface of the glass, it causes the patient any inconvenience, it should not be worn; otherwise it may excite dangerous sympathetic irritation in the other eye. The artificial eye should always be removed at night, and only worn at first for a few hours during the day.

Mr. W. H. Mules in the Transactions of the Ophthalmological Society for 1885, describes his operation for evisceration of the globe with artificial vitreous as an alternative to enucleation. This operation consists in emptying the contents of the globe under aseptic conditions, and introducing into the cavity of the denuded sclerotic, a light hollow glass sphere, which, while preserving the shape of the globe and causing no irritation, would perfect the stump for the adaptation of an artificial eye. The patient to be operated on having been anæsthetised, the parts are to be thoroughly disinfected. The front of the eye is to be transfixed and removed at the corneal-scleral junction. The contents of the globe are then to be completely removed, together with the ciliary body and choroid, leaving only a clean white sclerotic, which is to be thoroughly disinfected. One of Mr. Mules' glass spheres is then to be introduced into the sclerotic, and the cut edges of the sclera are to be brought into accurate apposition by means of cat-

gut sutures. The wound is to be dressed on Listerian principles, and the patient should be kept in bed for a few days. It is most important to keep the wound perfectly aseptic, otherwise the operation cannot be expected to succeed.

CHAPTER XVI.

Innervation and Action of Muscles of the Eye—Diplopia—Paralysis of Orbital Muscles—Causes—Treatment—Strabismus—Convergent—Divergent—Treatment—Nystagmus.

INNERVATION AND ACTION OF THE MUSCLES.—The third pair of nerves divides into two branches in the orbit, the upper one supplies the levator palpebræ and superior rectus, and the lower branch sends nerves to the internal rectus, inferior rectus, inferior oblique, the sphincter pupillæ, and ciliary muscle.

The fourth nerve supplies the superior oblique.

The sixth nerve the external rectus.

The eyeball moves round a fixed point called the centre of rotation, which is situated 13 mm. behind the cornea in the emmetropic eye, and therefore does not exactly coincide with the actual centre, but lies a little behind it; the six orbital muscles are arranged in three antagonistic pairs, and produce two kinds of movement; first, moving the cornea upwards, downwards, inwards, or outwards; and secondly rotating the eyeball round its antero-posterior axis. The starting point of the eyeball from which all action of the muscles must be considered, is that in which the eye is directed straight forwards; this is termed the *primary position* of the eyeball, and is that in which there is the least innervation of the muscles.

The external rectus acting alone rotates the eye on its vertical axis and turns the cornea directly outwards.

The internal rectus rotates the eye on its vertical axis and turns the cornea directly inwards.

The superior and inferior recti rotate the eye on an axis which is not quite horizontal, but takes a direction from

before, backwards and outwards, forming with the antero-posterior axis of the eyeball an angle of 70° , the superior rectus turns the cornea upwards and slightly inwards, producing also some rotation of the globe inwards, *i.e.*, the upper part of the vertical meridian is turned inwards.

The inferior rectus directs the cornea downwards and inwards, and also produces rotation of the globe outwards.

The effects of these muscles will vary in different positions of the eye, thus when the eye is turned outwards, the

FIG. 61.

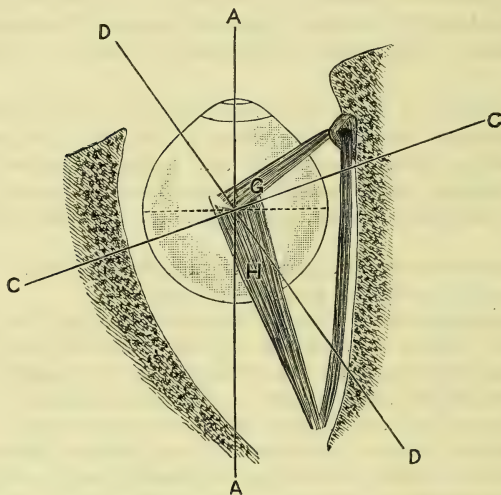


Fig. 61 shews the axis of rotation (C) of the superior rectus (H) which forms with the antero-posterior axis (A) an angle of 70° .

(D) is the axis of rotation of the superior oblique; this forms with the antero-posterior axis (A), an angle of 35° .

upward and downward movements are greatest, because the antero-posterior axis of the eyeball then more closely corresponds with the axis of the muscles, when turned inwards, the influence of the muscles to rotate the cornea is greatest.

The superior and inferior oblique rotate the globe on an axis which lies in the horizontal plane passing from within

and behind, forwards and outwards forming with the antero-posterior axis of the globe an angle of 35° .

The superior oblique turns the cornea downwards and a little outwards, and rotates the upper part of the cornea inwards.

The inferior oblique turns the cornea upwards, and a little outwards, and produces rotation of the upper part of the cornea outwards.

The power of the obliques in producing upward and downward movements, are greatest when the eye is turned in, while their rotating power is greatest when the eye is turned out.

The cornea is turned inwards by the internal rectus, outwards by the external rectus, upwards by the combined action of the superior rectus and inferior oblique, downwards by the combined action of the inferior rectus and superior oblique.

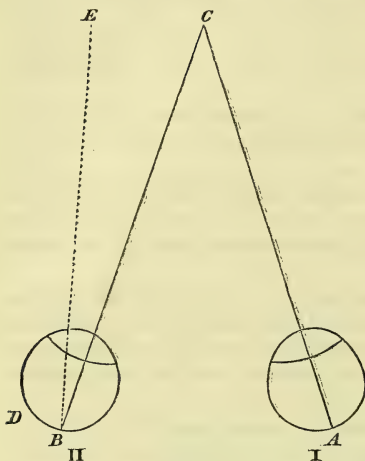
The purely vertical and lateral movements bring the eye into what are called PRIMARY POSITIONS, and are unaccompanied with rotation of the globe on its antero-posterior axis, movements into the intermediate positions are called SECONDARY and are combined with rotation or as it is sometimes called torsion.

So far we have considered the movements of each eye separately; more frequently we have to consider them together; these associated movements may be of two kinds: (1) Movements of convergence; (2) Movements in the same direction; thus, if an object be looked at on one side the internal rectus of one eye is associated with the external rectus of the other; we may also have a combination of these two kinds of movement.

These associated movements are governed by definite centres in the brain, and are regulated by the desire for binocular vision. When, from deviation of either eye, the image of an object falls on parts of the retina of the two eyes which do not correspond, diplopia or double vision is produced.

DIPLOPIA.—In order to ensure correct vision the eyes must work in unison; or, in other words, there must be perfect association in the movements of both so that the two retinal images may be fused into one. If in any position of fixation the two visual axes do not cross on the object, double vision or *diplopia* is the result; provided there existed previously

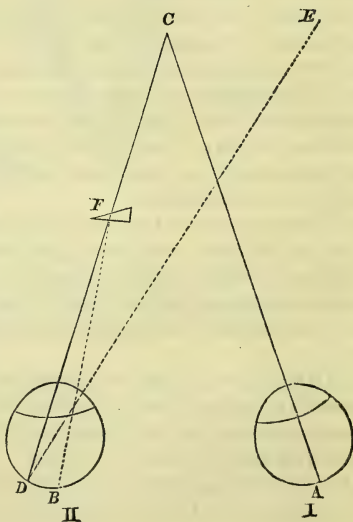
FIG. 62.



true binocular vision. There are two forms of diplopia, *homonymous* and *crossed*; the former may be understood by referring to Fig. 62. The left eye, B, in this case is adducted, the right eye, A, is normal, and fixed on a distant object c, the rays from which fall on the macula at A; but, in consequence of the left eye being adducted, the rays from c fall on the point B, internal to the macula, and the image formed will be mentally projected in the direction of E; and thus two images of the figure c will be

visible, one in its real position and the other peripheral, to the left of c at E. The reverse of this would hold good, if the right eye were adducted; the peripheral image would then be to the right instead of to the left of c. In the second form of diplopia, as its name implies, the images cross one another, as shown in Fig. 63. The left eye, B, is supposed to have abnormal divergence, and in the right eye, A, which is normal and fixed, so that the rays of light from the point c fall upon its macula at A; but as B is abducted, the rays from c do not impinge upon its macula at B, but on a point external to it at D, and are projected in

FIG. 63.



a line perpendicular to this point in the direction of E, so that they cross those proceeding from C to A, and hence the crossed diplopia.

Besides the lateral displacement, diplopia may occur in the vertical direction, or from weakness in the muscles concerned in the rotation or torsional movement of the eyeball. The course of the rays C, D, may be changed by means of a prism, as at F, by which they are bent towards the base of the prism, and so fall on the macula at E; in this way the diplopia may be corrected; for although the eye B is abducted, the rays from C are directed upon its macula by means of the prism F, and binocular vision restored.

PARALYSIS OF THE ORBITAL MUSCLES.—In addition to diplopia, which has just been referred to and which is indicative of strabismus, other symptoms exist in complete or partial paresis of any of the ocular muscles; in some positions the diplopia may not be complete, the two images simply overlapping and so producing indistinct vision; giddiness may be complained of, due no doubt to faulty projection; there may be a tendency to close the affected eye so as to obtain single vision, or by turning the head to the side of the paralysed muscle diminish or suppress the diplopia, frequently some deviation of the affected eye may be noticed. The diplopia always increases towards the paralysed side, and is usually most troublesome when the two images are close together; when they are widely separated the false image falls on a peripheral part of the retina and so produces a feeble image which can easily be disregarded. When the sound eye is made to fix an object the affected eye may deviate; this movement of the eye is called the primary deviation; if now the sound eye be covered and the affected eye made to fix the object, the sound eye will make a corresponding movement; this movement is termed the secondary deviation. In paralytic squint it must be remembered that the secondary deviation is greater than the primary, whereas in concomitant squint the primary and secondary deviations are equal. For instance, suppose the external rectus of the left eye is paralysed, the patient is therefore unable to abduct this eye; but if a candle be held in front of him, with the right eye closed, on moving the candle to the left of the patient the left eye makes an effort to follow it, and may be moved perhaps one line outwards; the right eye we shall

find has made an associated movement inward of two lines. In this case, therefore, the secondary deviation is evidently greater than the primary. The power of the left external rectus being defective, it requires an increased nerve stimulus to abduct the left eye; but this increased stimulus cannot be confined to one eye, but is equally propagated to the sound one; and, as the healthy muscle responds normally to the increased nerve force, the right eye is adducted considerably more than the left one is abducted. As a consequence of the want of action in the external rectus, after a time, secondary changes occur in the antagonistic muscle, leading to alterations in its contractile power. To detect the affected muscle, we direct the patient to look at some convenient object held about one metre off, and then alternately cover each eye with a card, noticing if any movement takes place on uncovering either eye; should there be any deviation of either eye, then a correcting movement would be necessary to enable it to fix the object on uncovering, but to actually judge of the amount of deviation, it is necessary to measure the angle with the perimeter, as described hereafter. We should also carefully map out the diplopia in the different parts of the field of vision; to enable us to discriminate easily between the two images, a red glass should be placed before the fixing eye in a spectacle frame; this, of course, will render the image of this eye coloured; we place the glass before the fixing eye so as to render the diplopia more apparent; if it were placed before the affected eye and the false image happened to be a long way from the true one, by placing the glass before that eye we should render the image still more indistinct, and so it might easily be overlooked. A candle is a convenient test object and should be held about two metres from the patient, first, straight in front, then above and below, then to each side, and the position of the images duly recorded in each position.

Paralysis of all the external ocular muscles (ophthalmoplegia externa) occurs sometimes in coarse brain disease, and indicates that the mischief involves the centres of the 3rd, 4th, and 6th nerves; such cases are usually syphilitic in character. The nerves which are most liable to paralysis are the 3rd and the 6th; while of affections of single muscles the external rectus stands first in frequency, then the superior oblique; paralysis of the superior, internal, or inferior rectus singly, is rarely met with, while paralysis of

the inferior oblique is an ophthalmological curiosity, only a very few cases having been recorded.

Besides these, many cases will be of a mixed character, two or more muscles being affected in varying degree. We may also have paralysis of associated movements, as in the case of conjugate deviation to one side.

PARALYSIS OF THE EXTERNAL RECTUS (6th nerve) is usually easily detected; there is an internal strabismus with loss of power outwards towards the paralysed side; diplopia and giddiness are complained of, and the head is turned towards the affected side in order to diminish the effect of the paresis. If the patient try to strike an object, especially if the sound eye be closed and the blow be made quickly, he will probably strike to the side of the affected muscle.

Supposing the external rectus of the right eye be affected, if a lighted candle be looked at with a coloured glass before the good eye, in front and on a level with the eyes, the images of the candle will be close together with the red image to the left, *i.e.*, homonymous diplopia; on moving the candle to the left, the head of the patient remaining fixed, the images will come closer together until they overlap; on carrying the candle over to the patient's right, that is in the direction of the paralysed muscle, the images will be further apart but will remain upright. On moving the candle above and to the right the images will be still widely apart, but the false image will also lean away from the other. Below and to the right the same takes place, except that the false image will incline to the other. Normally, in looking upwards and to one side, the vertical meridian of the cornea slants upwards and to that side, but in the case of paralysis of one external rectus the movements outwards and upwards are curtailed so that rotation will also be less, and therefore the projected image will not be erect.

The position of the diplopia in the different parts of the field can be seen at a glance if a diagram be made with the images of the candle marked as they appear to the patient in different positions.

PARALYSIS OF THE THIRD NERVE may be complete or partial; in the former case all the muscles supplied by this nerve are paralysed, and in the latter one or more only may be affected. Supposing complete paralysis of the third nerve of the left

eye exists, the first symptom we shall notice will be loss of power of the levator palpebræ, the patient being unable to raise his upper eyelid. On opening the lids the pupil will be seen to be partially dilated, and the ciliary muscle will be found to be paralysed, so that all accommodation is lost. We shall also find that our patient can only direct the eye outwards; in other directions it is unable to follow an object placed before it, so that if the latter be held above, below, or to the right of the affected eye, diplopia is produced. In consequence of the illusion thus created in the mind, when the patient attempts to walk across a room to reach an object in front of him he is apt to stagger much as a drunken man would do. In some cases exophthalmos results from the loss of power in the recti muscles, and their inability to resist the natural tendency of the elastic contents of the orbit to thrust the eye forwards. The pupil acts very slowly under the stimulus of light, and is more or less dilated. In instances of complete paralysis of the muscles supplied by the third pair, we have only to bear in mind their combined action, in order that we may understand the nature of the diplopia that must occur. (Page 396.)

PARALYSIS OF THE SUPERIOR RECTUS.—This muscle is not often paralysed alone, when it does happen, it is due to an affection of that branch of the third nerve which supplies the superior rectus muscle. The movements of the eye upwards are more or less curtailed, and when attempted, frequently leads to retraction of the upper lid, the cornea will be directed forwards and slightly outwards, because the action of the inferior oblique is unopposed. When the good eye is covered, and an object is held above the patient's eye, the affected eye turns upwards as far as it is able to, the cornea of the sound eye will be found to have turned upwards and outwards to a greater extent. If the patient strikes quickly at an object, the chances are, that he will hit too high. When the object is held above the horizontal meridian of the eyes, diplopia will be present, crossed in character, with the false image appearing above the other and sloping somewhat away from it.

Dr. D. Webster, of New York, has published an interesting case of paralysis of the superior rectus, which he cured by tenotomy, he writes as follows:—

William C. McK——, aged thirty-three, bachelor, clerk, was intro-

duced to me by my friend Dr. George C. Jeffery, on January 1st, 1889. He said his eyes began to give out while working by gaslight in the latter part of 1887. In January, 1888, he selected glasses for himself [$+ \frac{1}{60}$] at an optician's and they gave him some help. In November, 1888, he consulted Dr. Jeffery, who advised him to lay aside his glasses, and he, after that, got along quite as well without them. He complains that his eyes seem to be "out of gear." He frequently becomes nervous and excited, and then his eyes are worse. He holds his head tilted to the left in order to avoid diplopia. In 1877, he had a chancre which was followed by various secondary symptoms: R.V. = $\frac{20}{20}$; Hm. O. 25 D. L.V. = $\frac{20}{20}$; $\frac{2}{15}$ with + O. 75 D.

Ophthalmoscope shows no lesion; physiological excavation of both optic discs, with pulsation of the retinal veins. On looking directly at a candle flame twenty feet distant the patient saw double images. These images were fused by prism 5° base down and 8° base out over the left eye. The images become farther apart as the patient looks down. The patient was seen again on January 4th, and the following glasses were ordered for constant use: Rt. + O. 25 D. S. Lft. + O. 50 D. S. prism 3° base down. He was also put upon iodide of potassium in increasing doses.

January 14th.—The patient says the glasses rest his eyes and prevent "that tired feeling," but in order to see a thing distinctly with them he has to look straight at it. Advised to continue the glasses and the iodide.

February 1st.—Is taking 100 minims of the saturated solution of iodide of potassium three times a day. Gets along well with his glasses and is gaining flesh.

February 16th.—Is getting along about the same. To lessen the dose of iodide potas. by 5 minims every third day.

May 16th.—Stopped the iodide the latter part of April and has taken no medicine since. The paralysis of the left superior oblique remains unchanged, but he gets along very comfortably with his glasses.

October 3rd.—The patient says that he has been having "the blues" without any sufficient cause. Latterly his head hasn't felt good, but he has not had what you would call a real headache. His eyes are not as strong as they were, and he often fails to see things correctly at first glance. He complains that he is getting more and more nervous and weak, and is entirely unfitted for business. A prism of 8° base down over left eye is now required to level up the double images. A tenotomy of the left superior rectus was advised.

November 1st.—The patient came to have the tenotomy performed. Immediately before the operation the double images were united by a prism of 9° base down, over the left eye. Immediately after the tenotomy of the left superior rectus, which was done under cocaine, the images were blended by a prism of 1° base down over the left eye. Five minutes later he was tested again, and it was found that a prism of 1° base up over the left eye was necessary to correct the diplopia.

November 2nd.—The patient is troubled with diplopia which he fails to correct by tilting his head. A prism of 2° base up over the left eye is now required to cause the images to blend.

November 4th.—The patient complains that "everything is all astir

and double." In the street a horse and wagon are double, and the upper one seems as though it were going up a hill. A prism of 6° base up over left eye fuses the images. It was now evident that the over-effect of the tenotomy was increasing, and without further surgical interference, would be permanent, so that "the last state of the patient would be worse than the first." We therefore again cocainized the eye, opened the wound, caught up the free end of the tendon which had retracted too far, and stitched it to the episcleral tissues on the corneal side of its former insertion. This stitch was drawn gradually tighter until the double images on the vertical plane were fused, and until the double images, produced by prisms placed horizontally before either or both eyes, were in a horizontal plane.

November 5th.—Patient has been comfortable since the readjustment of the muscle. No hyperphoria of either eye.

November 8th.—The patient has single binocular vision which is kept up with a red glass over either eye. Removed the stitch.

November 12th.—The patient complains that for the last few days he has had an uncomfortable feeling in his left eye, as though an eyelash were inverted. Inspection shows a slight abrasion of the corneal epithelium.

Orthophoria; sursumduction R. 2° ; L. 2° ; abduction 4° ; adduction 4° .

Homatropine solution was dropped into the eye and a bandage applied.

November 13th.—Abrasion healed. Orthophoria, abduction 8° , adduction 9° .

January 1st, 1890.—The patient comes to my office to report himself "as well as he ever was in his life." He needs no glasses, carries his head erect, has no confusion of vision, and has no more of that tired feeling. The prism tests show no insufficiency of his ocular muscles (orthophoria).

There are some interesting points in this case. In the first place, as the paralysis was due to syphilis, we expected to give relief by a thorough course of iodide of potassium. But although doses of nearly three hundred grains a day were taken daily for several weeks, and large doses for several months, no result was obtained so far as his eyes were concerned. In the second place, we may say that the completeness of the relief following the operations upon the superior rectus was very remarkable. There remained no diplopia in any part of the field, and the nervous symptoms, which had almost entirely incapacitated the patient for work, disappeared simultaneously.

Some time in 1888, Dr. H. Knapp reported a case to the Ophthalmic Section of the New York Academy of Medicine similar, in many respects, to that reported above. So far as I know, Dr. Knapp's case which is not yet in print, is the only case besides my own treated in this way.

In Vol. IV. of the *Archives of Ophthalmology*, the same author publishes three cases in which he performed tenotomy of the superior or inferior recti for paralytic squint, but these were all complicated cases, other muscles being involved. They were:—

"1. Tenotomy of the upper and lower recti of the same eye for paresis of the upper rectus.

"2. Tenotomy of the external rectus of both eyes, and the inferior rectus of the left eye, for strabismus and diplopia.

"3. Strabismus, sursumvergens, improved by tenotomy of the superior rectus, with a suture, increasing the effect, through the lower lid; secured advancement of the inferior rectus."*

PARALYSIS OF THE INTERNAL RECTUS may be due to paralysis of that branch of the third nerve which supplies the internal rectus muscle. Divergent strabismus is present with more or less loss of power to move the eye inwards. The diplopia is of course crossed, and the double images separate as the test object is carried to the side of the affected muscle. Paralysis of this muscle by itself is exceedingly rare, though in cases of paralysis of the whole third nerve it may be the muscle which suffers most.

PARALYSIS OF THE INFERIOR RECTUS.—In paralysis of this kind the movements of the eye downwards are restricted, especially when the globe is turned outwards. Crossed diplopia is present in the lower part of the field, the false image being below and slanting towards the true one.

PARALYSIS OF THE INFERIOR OBLIQUE.—Paralysis of this muscle very rarely occurs without some of the other muscles of the eye being involved; should it be met with the movements of the eye upwards would be found curtailed; this will be especially marked when the eye is turned inwards. The diplopia will be homonymous and will be present only for the upper portion of the field.

PARALYSIS OF THE SUPERIOR OBLIQUE.—Paralysis of the superior oblique is due to a lesion of the 4th nerve, which may be either peripheral or central; the action of this muscle is to turn the cornea downwards and slightly outwards, and at the same time to rotate the upper part of the cornea inwards, therefore paralysis of this muscle will be most apparent when the eyeball is turned downwards and inwards, as all movements in this direction are restricted. This defective motion may be exceedingly difficult to detect, and it is only by carefully mapping out the field of the diplopia that we shall arrive at an accurate diagnosis. The diplopia is homonymous in character, and is confined to the lower half of the field of vision. In the middle line below, the false image will appear lower than the true one, because the eye on the

* Read before the Ophthalmic Section of the New York Academy of Medicine, May 21st, 1890. —*Medical Record*, 7th June, 1880.

paralysed side is higher than on the other, therefore the image will be formed above the macula and so be projected downwards, the position downwards and outwards is that in which the greatest rotation of the cornea takes place, therefore, when the candle is held in this position the false image slopes towards the true one; downwards and inwards is the position in which the greatest vertical displacement takes place. Although the diplopia is usually homonymous, cases do occur of paralysis of this muscle in which the diplopia is crossed in some positions; this is due to excessive contraction of the inferior oblique. Great disturbance of vision is caused by paresis of this muscle, which in some cases renders it difficult for the patient to move about, frequently he holds his head downwards and towards the sound side. It is a remarkable fact that in this form of paralysis the false image appears to be nearer than it really is.

Causes of Paralysis or of Paresis of the Muscles of the Eye.—Pathological changes at the base of the brain, or in the region of the nuclei of the third, fourth and sixth nerves situated at the base of the fourth ventricle, and aqueduct of Sylvius, may be the cause of paralysis, or of paresis of the ocular muscles. But peripheral lesions of one or more of these nerves, the result of rheumatism, or of syphilis, is a more frequent cause of paralytic affections of the ocular muscles. Malaria has a similar influence; hemicrania depending on this cause, being occasionally followed by paralysis or paresis of the nerves supplying the muscles of the eye-ball; in the tropics and other malarious countries, cases of this kind are by no means rare. It is, however, often difficult to determine the site of the lesion in these paralytic cases. In the first place the history of the case is all important; and secondly the extent of the affection, that is the area of the muscles involved. For instance, if a patient is free of syphilis, and is suddenly seized with diplopia from weakness of one of his external recti, we may fairly diagnose the case to be one of rheumatic paresis of the corresponding sixth nerve; provided there is not total paralysis of the muscle. The same remark applies to the superior oblique.

If the patient had suffered from long standing syphilis, and if one of the external recti or the superior oblique muscle had lost its power to contract, we should expect that a gumma had grown in the course of the fourth or sixth nerve, either in the orbit, or within the cranium, and by pressure interfered

with the functions of the nerve. And so with paresis and even paralysis of the third nerve; if this nerve alone is implicated, the fourth and sixth nerves continuing healthy, we may as a rule conclude that the lesion is peripheral, and produced either by rheumatic, syphilitic or malarial neuritis; for considering the close proximity of the nuclei of the third, fourth and sixth nerves, any central changes would in all probability involve not only the third but also the fourth and sixth nerves. If, however, in recent paralytic affections of the third nerve, the diplopia cannot be overcome by prisms, or that slight alterations in the strength of the prism or in the position of the object under observation reproduces the diplopia, we must incline rather to suspect a central lesion.

If we find that the muscles supplied by different nerves are paralysed to a greater or less extent we should certainly suspect some cerebral trouble. This idea is confirmed if the muscles of both eyes are involved, especially if the paralysis affects the fourth nerve on one side and the sixth on the other. We cannot overlook the fact that in the majority of cases of intra-cranial disease, paralysis of the ocular muscles is accompanied by other symptoms pointing to the nature of the lesion; and in all such cases important information is to be gained by ascertaining the condition of functional activity of the facial, sympathetic, and the fifth nerve.

The Prognosis in cases of paralytic affections of the ocular muscles will, in the first place, depend largely upon the cause of the affection, central lesions being less hopeful than those depending on peripheral changes in the nerve or nerves; and secondly upon the length of time which has elapsed since the diplopia or other symptoms first occurred; lastly we must take into consideration the nature of the cause giving rise to the symptoms. As a general rule the longer the time which has elapsed since the commencement of the affection of the muscles, the less hope is there of recovery; complete fatty changes, or sclerosis of the nerve following any prolonged morbid action in its substance, whether these be of syphilitic origin or from any other cause. Central lesions are obviously less hopeful than peripheral; of the latter the rheumatic are the most common. In a considerable number of cases of sudden paresis of the sixth nerve on one side, commencing after exposure to cold to the affected side, if properly treated in its early stages, the muscle completely regains its functions, although this is a work of time; two or three months would hardly be too short a period

to allow for the recovery of the weakened muscle. And the same remark applies to syphilitic and malarial affection of the nerves; we have seen a considerable number of such cases treated in their early stages recover completely or to a great extent. On the other hand in an unhealthy individual, worn out by age or disease, especially if the paresis has been in existence for some months, the prognosis is unfavourable; in those conditions patients with a syphilitic history are most likely to improve under treatment.

We occasionally meet with paralytic affections of the ocular muscles following an erysipelatous attack of the contents of the orbit, in such cases the muscles seldom if ever regain their functions. But in instances of weakness of the muscles arising from the pressure of an abscess in the orbit, or from a tumour, if the cause of the muscular incapacity can be removed its functions may be restored. Diphtheritic and other poisons which produce acute fevers by their action on the nerve centres, occasionally cause paresis of the ocular muscles; in these cases the prognosis is not unfavourable, although the recovery of the weakened muscle is always a work of time, and must largely depend upon the severity of the attack and the recuperative powers of the patient.

The Treatment of paralytic affections of the ocular muscles will depend in the first instance upon the cause which has produced the muscular weakness. In rheumatic affections of the nerves full doses of salicine or salicylate of soda are not unfrequently of marked benefit, if administered in the early stages of the loss of power in the muscle. Quinine is also of service in such cases, and is clearly indicated together with a change of the locality in which the patient resides in instances of malarial affections of the nerves. In syphilis, mercury is our sheet anchor in combination with iodide of potassium. But beyond the constitutional treatment, which must vary with the health and condition of the patient, we may do much in the way of local treatment in paralytic affections of the ocular muscles. The longer a muscle remains at rest the greater the degenerative changes in its structure, especially when its nerve supply is compromised, consequently the weakened muscle must be exercised; this may be done by ordering the patient for ten or fifteen minutes twice a day to move his eye in the direction of the weakened muscle. The muscle may also be exercised by an effort on the part of the patient to overcome the diplopia and maintain binocular

vision. To accomplish this the patient should fix his eyes on some small object, and then move the object gradually further in the direction of the area of double vision, whilst he does his best to fuse the images which tend more and more to separate. In cases of this kind, when at work with both eyes, the strain to fuse the images may often be relieved by the use of prisms placed before both eyes with their base directed inwards. Electrical stimulation is no doubt useful in many cases. Faradization being employed with a weak current for about five minutes twice a day, one pole is to be applied over the closed eyelid and the other behind the corresponding ear on the affected side.

All other means having failed if the diplopia continue to trouble the patient, the weakened muscle may be shortened, and in such cases it may also be necessary to weaken the opposing muscle by tenotomy; the operative proceedings called for in such cases is referred to under the observation on the operations for strabismus. We have already referred to a case of Dr. Webster's in which he operated for paresis of the fourth nerve; proceedings of this description are more frequently called for in paresis of the external rectus, and if the loss of power in the affected muscle is not very considerable, benefit often attends these operations. Our object is to correct the degree of excessive convergence which exists in fixing an object in the middle line so as to overcome the diplopia; division of the internal rectus is seldom sufficient in cases of this kind, it is almost always advisable at the same time to advance the weak external muscle. As we before remarked, however, paralytic affections of the ocular muscles take, as a rule, a long time to recover, a year or eighteen months is not too long in which to expect improvement, and then it is only if the diplopia is very annoying, and cannot be corrected by prisms that we should recommend an operation for its relief; when, as in Dr. Webster's case, and in that which follows, simple tenotomy should be first tried, although as we have remarked it seldom affords a permanently satisfactory result in this class of cases.

Captain E., aged 45, came under the care of Surgeon-Major Partridge, of Bombay, in September, 1869, complaining of defective vision and strabismus. Dr. Partridge writes: on examination, I found that he only, as a rule, used the right eye, and had acquired a habit of half-closing the lids of the left eye, to avoid confusion of images. If the right eye was covered he could see, though not clearly, with the left. When

directed to look at an object distant about 12 inches, with both eyes open, the left eye turned directly downwards, or downwards and very slightly inwards. The right eye being covered, the left immediately came into position, showing a primary deviation of about 2 lines. Both eyes being uncovered, and he being told to look with the left eye only, the right eye was turned somewhat upwards. On testing his vision, I found that with the right eye he had simple astigmatism, in the left eye he had mixed astigmatism.

Taking into consideration that diplopia could be produced by a prism, that vision could be corrected by suitable glasses, I saw no reason why an operation for the cure of the strabismus should not succeed, although it had existed for forty-five years! Accordingly, I placed him under chloroform, and divided the inferior rectus by the sub-conjunctival operation. There were no lateral expansions of the muscle, and the eye immediately righted itself, turning at first a little outwards; this, however, corrected itself after the first day. The eye is now quite straight, and all deformity is removed.*

STRABISMUS.

The term strabismus is applied to cases in which a disturbance exists in the relative movements of the eyes, without there necessarily being any actual loss of power in the muscles. Cases of strabismus may be divided into two classes: in the first (strabismus concomitans) the patient never directs the visual axes of both eyes to the same point, they always cross in front or beyond the object, whichever eye is fixed on it. In this case the field of excursion of each eye is not diminished, but only displaced a certain number of degrees inwards or outwards.

In the second class of cases of strabismus (apparent strabismus), the corneal axes may converge or diverge, while the visual lines cross at the point of fixation. Even in the normal eye the visual lines do not, as a general rule, coincide with the axes of the cornea, but form with them an angle. This angle may be larger or smaller in different individuals, and in consequence the eyes appear to diverge or converge, notwithstanding the perfectly correct action of the visual axes.

Concomitant Strabismus.—Strabismus exists when there is a deviation in the direction of the eyes, so that the visual axes are not directed to the same object. Simple inspection does not always enable us to say definitely that squint is present, for there may be a deviation so slight that it cannot

* *Medical Times and Gazette*, Vol. I., 1871, p. 243.

be detected, while, on the other hand, there may appear to be a deviation which does not really exist; this is sometimes called apparent strabismus, and is due to the angle α , which is the angle formed between the visual and optic axes being greater or less than normal; in emmetropia the angle α is usually about 5° .

In hypermetropia (Fig. 65), the angle α increases with the degree of hypermetropia, and if it be high it may attain

FIG. 64.




FIG. 65.




FIG. 66.



M . The macula. N . The nodal point. B , Optic nerve. v . The object. VM . The visual axis. ON . The optic axis. α . The angle alpha formed between the visual and optic axes. c . The centre of rotation of the eyeball situated on the optic axis. γ . The angle gamma (Fig. 64) formed at the centre of rotation of the eyeball, by the optic axis and a line drawn from the centre to the object looked at.

7°, 8°, or even more; this large angle gives to the eyes an appearance of divergence.

In myopia (Fig. 66), the angle α decreases, and in high myopia the visual axis may approach the optic axis, so that the angle α is very small, or it may coincide with it, when no angle is formed, when the angle is said to be *negative*. This small angle α gives to the eyes an appearance of convergence.*

In order to find out the variety to which our case of strabismus belongs, as well as to decide which is the deviating eye, we direct the patient to look at an object held about a metre in front of him, then gradually bring this object nearer to him, so as to call into action the accommodation; if both visual axes continue to be directed steadily towards the object as it is made to approach the eyes, the case is one of *apparent* strabismus; but, if one eye fixes it, while the other, after following it up to a certain distance, suddenly deviates inwards or outwards, the condition is spoken of as *concomitant* (convergent or divergent) strabismus; or both eyes may follow the object up to a certain point, when one stops, after perhaps making a few jerking oscillating movements; it then belongs to the *paralytic* variety of strabismus. Again, having covered one eye with a card, or, what is better, with an opaque glass disc, which, while preventing the patient seeing with that eye, yet allows us to see the movements that take place behind it, we direct him to fix with the other eye some object, such as a pencil held about half a metre in front of him. If the covered eye make a movement inwards, the squint is real, and this movement is called the *primary deviation*. If now the fixing eye be covered, the squinting one uncovered and made to fix the object, the first eye, which is now excluded from vision, may make a movement inwards; this movement of the sound eye is called the *secondary deviation*.

When the primary and secondary deviations are equal, the squint is said to be *concomitant*.

The range of movement in concomitant squint is as great as in cases where no squint exists, it is simply displaced; in the paralytic form, the movements of the squinting eye are usually much curtailed; this we easily detect by holding up

* Another angle sometimes mentioned is the angle γ , which is the angle formed at the centre of rotation of the eye by the optic axis, and a line drawn from this centre to the object looked at. Shown in Fig. 64.

the finger about 50 cm. in front of the patient, and directing him, while keeping the head still, to follow the movements of the finger, which is moved to either side, then up and down. In the concomitant form, the squinting eye will almost exactly accompany the other, the visual lines being at the same angle, except, perhaps, in the extreme periphery, whereas, in the paralytic form, the movement in one eye will stop at a certain point, while the other eye continues to follow the finger.

When either eye fixes indifferently, the vision being equally good in both, it is called *alternating strabismus*. *Monolateral* or *constant* when the same eye always squints; the vision in the squinting eye is usually below that in the fixing one.

Periodic when it only comes on occasionally, as after looking some time at near objects. If judiciously treated, this variety can be cured without operation; if neglected, it generally passes on into one of the constant forms.

In concomitant strabismus the primary and secondary deviations are equal. In the paralytic form the secondary deviation usually exceeds the primary.

The amount of deviation may be estimated in several ways as described on page 408.

Concomitant strabismus is intimately connected with hypermetropia and myopia, it may be—

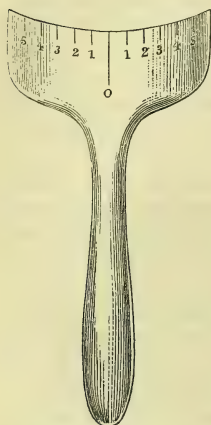
Convergent.

Divergent.

There are several ways by which we may estimate the amount of the deviation. We may indicate it in the form of a diagram; the position of the pupil to the internal canthus when looking as far as possible to one side, which will show the extreme range of the eye inwards; then direct the patient to look in the opposite direction, so that we may find the extreme range outwards; this we indicate by the position of the outer edge of the cornea, with the external canthus; our diagram must of course include both eyes, so that we may judge of their relative range of movement.

The strabismometer (Fig. 67) consists of a handle, supporting a small ivory plate, shaped to the lower lid, and having on it a scale by which we measure the amount of deviation of the centre of the pupil. This is an easy method of measuring the strabismus, but is not to be depended upon.

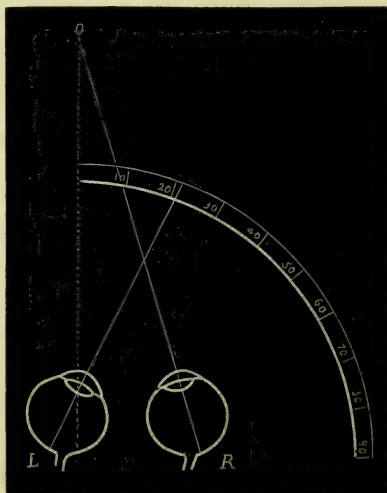
The measurement of the *angle of the strabismus* is the only reliable and exact method of recording the amount of squint, and is the method therefore recommended. Landolt defines the angle of the strabismus, as that angle which the visual axis makes, with the direction it should have, in a normal state.



Strabismometer.

For this measurement we require a perimeter, in front of which we seat the patient, with the quadrant placed according to the kind of squint we are about to measure; if it be a convergent or divergent one, then the quadrant is placed horizontally. The patient being seated so that his deviating eye is in the centre of the instrument; we direct him to fix with both eyes some distant object (o, Fig. 68), placed in a line with the centre of the perimeter; a lighted candle is moved gradually along the inside of the quadrant from the centre of the instrument outwards; the observer, following the movement of the candle with his head, stops as soon as the reflection of the candle on the cornea of the squinting eye occupies the centre of its pupil, this gives the direction of the optic axis; what we really wanted was the direction of the visual axis, but for all practical purposes the former is sufficient. The degree is read off the quadrant at

FIG. 68.*

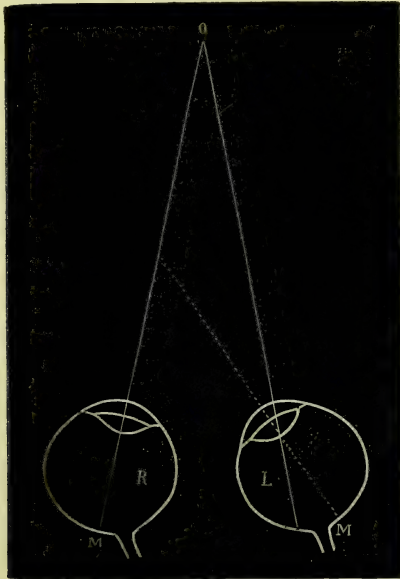


* In the above diagram o is intended to represent a distant object; it is placed near the perimeter in order to take up less room.

the point where the candle was stopped and this result recorded. We must next measure the angle of deviation for near vision, by requesting the patient to look at the centre of the perimeter, proceeding with the candle as before, and recording the result.

CONVERGENT STRABISMUS (Fig. 69).—On looking at any object one eye may be directed to it, while the other turns

FIG. 69.



R. Right eye directed to object O. L. Left eye deviating inwards. M. Macula.

inwards, so that the metrical angle is much greater in the deviating eye, than in the fixing one. It is almost always due to hypermetropia, probably at least 80 per cent. of the whole being due to this cause; its method of production depends upon the intimate connection that exists between accommodation and convergence.

The convergence is most marked when looking at near objects; sometimes there may be no squint when distant objects are viewed.

A person who is hypermetropic requires to use some of his accommodation for distant objects; for near objects he must, of course, use still more, since, for every increase in the accommodation, there is a desire for a certain increasing degree of convergence. Thus, an emmetropic individual, accommodating for an object 30 cm. off, would at the same time converge for that particular point. If the individual were hypermetropic to the extent of 4 D., possessing, as he does, the same amplitude of accommodation as the emmetrope, we will suppose 8 D.; of this one half, 4 D., would be required to enable him to bring parallel rays to a focus on the retina; and he would have the tendency at the same time to use 4 metre angles of convergence. Thus, for distant objects he would have an inclination to converge, his internal recti acting, and it is only by the increased tension of the external recti, called into action by the desire which all eyes possess for singleness of vision, that convergence is prevented. The more we converge the more can we accommodate; so that on looking at near objects—which means an increase of the accommodation—an increased tendency to convergence is produced.

Now, if the hypermetropia be of such a degree that, for any given point of convergence, it exceeds the positive part of the relative accommodation, one of two things must occur; either the patient must see indistinctly by not accommodating sufficiently, or one eye must be allowed to converge. Some patients will prefer binocular indistinct vision, others, single clear vision with squint. One occasionally finds an individual who can thus choose which he will do; we are trying his acuteness of vision at the distant type perhaps, he stops at some place, we will suppose, $\frac{6}{12}$ and says that he is unable to read the next two lines unless he squint. The accommodation necessary to read $\frac{6}{6}$, makes a heavier call on the convergence than can be borne; such a case forms a good illustration of the manner in which convergent strabismus is produced in a hypermetrope. Hence, if the impulse to see distinctly is greater than the desire to retain binocular vision, one eye yields, and squint occurs; at first, diplopia follows the convergence, and is always in the opposite direction to the deviation. Possibly the convergence of the deviating eye is increased by the desire that the weaker

image may be made still weaker by falling on a more peripheral part of the retina. At first the diplopia may be very annoying, but by degrees the sensorium learns to suppress the image of the weaker eye, which after a time becomes amblyopic. The earlier the age at which the squint appears, the sooner does the sight in the deviating eye thus deteriorate.

Some observers deny that amblyopia is ever developed as a result of squint, but consider the amblyopia so frequently met with, as congenital, and therefore one of the combining causes of the strabismus; at present there is but little evidence in support of either theory.

In high degrees of hypermetropia, when no amount of accommodation can make vision distinct, squint is less likely to occur. It is usually, therefore, in cases of from 2 to 4 D. that convergent strabismus is most frequently met with, and it generally makes its appearance about the fourth or fifth year, so soon in fact, as the child begins to use its accommodation much for near objects. Anxious parents frequently have all sorts of excellent reasons to which they attribute the defect; they say that the child has been imitating its playmate, or that the nurse did something which caused it to squint, perhaps by making the child look too much, or too constantly in one direction. Any cause which, by rendering the image in one eye less distinct than that in the other, as *nebulæ*, ulcers of the cornea, a difference in the refraction of the two eyes, or even wearing a shade for a few days for some trivial complaint, may, where hypermetropia is present, combine to produce strabismus; the impulse of binocular vision is lessened, and the eye in which the fainter image is formed, converges.

It is thus seen that convergent strabismus gradually destroys binocular vision. In cases of hypermetropia, where binocular vision does not exist owing to great difference in the refraction of the two eyes, divergent strabismus may occur. This intimate connection between accommodation and convergence, together with the method of the production of strabismus, will be more easily understood by carrying out some such simple experiments as the following. We will assume the observer to be emmetropic; the strongest concave glass with which he, having binocular vision and being at a distance of six metres, can still read $\frac{6}{6}$, is the measure of

the *relative* accommodation. The *absolute accommodation* is measured by the strongest concave glass, with which each eye separately can read $\frac{6}{6}$. In my own case, with -4 D.

before each eye, $\frac{6}{6}$ can be seen singly and distinctly, -4.5 D.

renders it indistinct, and each increase in the glass increases the indistinctness, but produces no diplopia. Separately each eye can overcome -7 D. Armed with -4 D. before

each eye, I am able to see $\frac{6}{6}$ distinctly, using of course 4 D

of my accommodation; if a coloured glass be placed before one eye, homonymous diplopia at once appears, proving that one eye has deviated inwards; with -3 D. and the coloured glass, squint was produced, but with no weaker concave glass.

On repeating the experiment in an individual with $.5$ D. of myopic astigmatism in one eye, and emmetropia in the other, -2 D. before each eye was the strongest glass with

which $\frac{6}{6}$ could be seen clearly and singly, -2.5 D. did not

render it indistinct, but produced diplopia. The absolute accommodation for each eye amounted to 6 D. With -2 D. before each eye, the coloured glass was placed before the astigmatic one, and diplopia was produced. With -1 D. and the coloured glass the result was the same, except that the two images were nearer together. With $-.5$ D. actual diplopia was not produced. These experiments require but little explanation. In my own case, when using 4 D. of

accommodation, I have the tendency also to use a corresponding amount of convergence; I am conscious of this muscular disturbance by the effort I make and by a feeling amounting almost to giddiness, produced when first looking through the -4 D. The instinctive desire to see clearly and singly is so great, that the external recti contract, thereby balancing the increased contraction of the internal recti. Any increase of

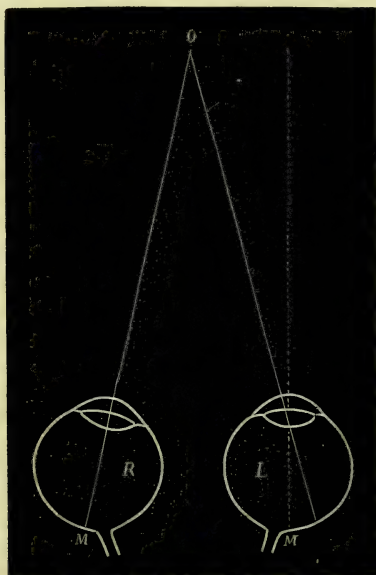
my accommodation above 4 D. when looking at $\frac{6}{6}$ causes the

letters to become indistinct, the desire to maintain binocular vision being greater than that for clear images. On placing the coloured glass before one eye we diminish the retinal impression in that eye; the demand for binocular vision is

lessened, the external recti ceases to act, and as a result of the increased action of the internal recti, squint occurs. In the second experiment the retinal impression in one eye, even with so slight an amount of astigmatism, is reduced, so that with 2 D. of accommodation without convergence, the desire for clear images is greater than that for binocular vision, and diplopia, the symptom of squint, results.

A certain number of cases of convergent strabismus get

FIG. 70.



well with advancing age; a possible explanation of this is that, as the accommodation diminishes, the time at length arrives when the amount of accommodation at the patient's disposal is not sufficient to produce clear images; he therefore relaxes his accommodation, and with it, extreme convergence. This spontaneous cure is most likely to take place when the sight in both eyes is good.

DIVERGENT STRABISMUS exists when one eye only fixes the object looked at, the other deviating outwards (Fig. 70). It

is usually dependent on myopia, but it may occur in any eyes in which binocular vision does not exist, as in some cases of high hypermetropia or astigmatism, or it may result from a too free division of the internal rectus muscle, in attempting to cure a case of convergent strabismus. I have seen one case in a young person with hypermetropia 1 D., whose visual acuteness was $\frac{6}{6}$ for each eye; the cause of the divergence here was no doubt a congenital insufficiency of the internal recti.

The divergent is much less common than the convergent variety of strabismus.

In myopia the antero-posterior diameter of the eyeball is elongated, the range of movement is diminished, and the extreme convergence which is necessary to enable the patient to see objects within his far point, tires out the internal recti muscles, giving rise to muscular asthenopia, to relieve this one of the internal recti gives way, and the eye deviates outwards. Sometimes the deviation only takes place after the patient has been working some time and the eyes feel fatigued; in others it is only noticed when looking at objects beyond their far point. Soon, however, the squint becomes constant, and a divergent strabismus once established usually increases.

Treatment of squint consists in prescribing proper glasses, with or without a course of mydriatics, supplemented in some cases by tenotomy.

In concomitant convergent strabismus, when the squint has just commenced, and arises only under the influence of excessive accommodation necessary to enable the child to see near objects (periodic squint), then resting the eyes by allowing no near work to be done, may suffice to remove the deviation and so preserve binocular vision. It is obvious that such treatment cannot be indefinitely carried out, and therefore we endeavour to relieve excessive accommodation by means of convex glasses; the child is placed under atropine, and the amount of hypermetropia found out by retinoscopy, or some other method, and such glasses ordered that will correct the total error within 1 D. or so (the nearer the full correction the better). These glasses must be worn constantly. If any astigmatism is present this should be corrected at the same time, so as to relieve the ciliary muscle

as much as possible, and bring up the visual acuteness of the patient to its highest standard.

When the convergent strabismus has already become permanent, we must keep the patient under atropine for a week or two, correcting his hypermetropia with glasses at the same time, while he must be cautioned to abstain as much as possible from looking at near objects, the mere impulse of convergence being sufficient to produce the squint. In some cases this treatment will be sufficient to cure the strabismus; and if at the end of a year or so no recurrence of the squint has taken place, an attempt may be made to leave off the spectacles when out of doors, using them only for near work.

If the case be one of the less common forms of squint, divergent with myopia, we endeavour to give the patient as near as possible his full correction. When the vision in the two eyes is different, that in the squinting one being more or less amblyopic, it is of service sometimes to exercise each eye separately for a certain fixed time daily.

It will be seen that after the use of atropine the squint may be diminished, or, in slight cases, have disappeared; this is, of course, due to accommodation being rendered impossible. Eserine has also been used with the same object.

Should the child be too young for spectacles (under three years), we must endeavour to prevent the increase of the squint and also prevent the deviating eye from becoming amblyopic; this can best be done by keeping the child atropized for a few weeks at a time and occasionally tying up the eye which does not squint, and so compelling the deviating eye to be used, thus preserving its visual acuteness; it has, of course, no effect on the deviation, the covered eye converging under the bandage. After the age of three, spectacles may be prescribed.

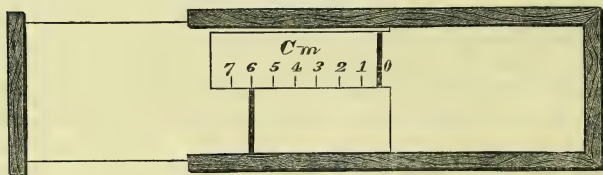
In many cases, after the spectacles have been worn for some months, it will be found that the strabismus still exists, and it will then be necessary to supplement the treatment by tenotomy. A free division of one muscle may cure a deviation of 15° ; when a greater effect is required both internal recti may be divided, or the tenotomy may be combined with advancement of its antagonist.

In some cases after operation it will be found that binocular vision is not obtained, the image in the squinting eye being disregarded or projected in a wrong direction, producing

diplopia, here good may be done by *Orthoptic Exercises*; these exercises may be carried out with a stereoscope.

Box stereoscopes are now made without prisms and fitted with a clip at each sight hole capable of taking the lenses of the ordinary trial box (Fig. 71). The patient being emmetropic will require in the clip a convex glass, whose focal length corresponds with the length of the stereoscope, thus if it be 16 cm. long, he will require + 6 D.; had the patient been hypermetropic 3 D., then he will require + 9 D.; if myopic 3 D., then + 3 D. would be the glass required, the object is to enable him to see the slide at the end of the stereoscope without accommodating. A convenient slide may be made, composed of two vertical lines, one above and the other below the same horizontal line, so arranged that the two lines can be made to recede or approach each other; this test object is placed in the box instead of the ordinary

FIG. 71 (Landolt).



views. The two lines being now separated to a distance equal to that between the two eyes, and the clips containing the necessary convex glasses, the patient will see the lines without accommodation or convergence, and should succeed in fusing the two lines into one; when this is done binocular vision is obtained with parallelism of the lines of fixation, we endeavour at future trials to obtain fusion with an equal amount of convergence and accommodation, this is done by sliding the two lines towards each other about 1 cm, this will call into play something like 1 m. a. of convergence, we then diminish the convex glass 1 D. so that the amount of accommodation provoked (1 D.) may correspond to the amount of convergence. In this way we slide the lines nearer and nearer together, diminishing the + glasses at the same time, until the two form one vertical line, then binocular vision is obtained with 6 m. a. of convergence and with 6 D.

of accommodation; when this point has been reached, stereoscopic pictures may be used as slides.

The operations for Strabismus, as we have already remarked, divide themselves into those for division (tenotomy) of one or other of the ocular muscles; or we may have to shorten one of the muscles. As a rule it is advisable before operating to administer chloroform, for among young persons and children it is hardly to be expected that they will have sufficient self-control to enable us properly to carry out a tenotomy or a more complicated operation to their greatest advantage. Among adults, if they prefer it, we may drop a 20 per cent. solution of cocaine upon the conjunctiva, and then with a sub-cutaneous syringe inject a few drops of a 10 per cent. solution beneath the conjunctiva, over the spot at which we propose dividing the tendon. The surgeon when operating stands either behind the patient's head or in any position most convenient to himself. The eyelids should be separated with a stop speculum. Supposing one of the internal recti is to be divided, an assistant may with advantage abduct the eye by seizing a fold of the conjunctiva with the fixing forceps. The surgeon then nips up a fold of the conjunctiva with a pair of forceps, in a line with the lower border of the cornea and over the insertion of the tendon to be divided, that is from a quarter of an inch to half an inch from the cornea. The conjunctiva is divided with a pair of scissors, and through this opening the blades of the scissors are introduced, and the sub-conjunctival tissues are thoroughly incised until the points of the scissors can be freely moved over the sclerotic. The strabismus hook is then inserted through the wound, its point being directed backwards along the lower border of the muscle; it is then turned upwards between the muscle and the eyeball, the muscle thus comes to lie in the hook of the instrument. The hook is now drawn forwards until it is stopped by the attachment of the tendon. The tendon is to be divided between its insertion and the hook, the lower blade of the scissors being passed between the tendon and the sclerotic, and the upper blade between the tendon and the conjunctiva. The attachment of the rectus is thus cut through sub-conjunctivally. The strabismus hook is again inserted and passed upwards and downwards so as to determine if any portion of the tendon has escaped division, if so, this portion must also be divided. The eye should subsequently be bathed with a solution of corrosive sublimate

and a pad and bandage applied for twenty-four hours, after which no bandage will be required.

If the operation has been successfully performed the patient will, after recovering from the effect of the anæsthetic, have some power of adducting the eye operated on in an effort of convergence; but not such as to allow of his converging and fixing the eye upon an object held close to his nose. In the course of four or five days the divided end of the muscle unites with the sclerotic at a point slightly behind its original insertion, so that the patient has never complete power of convergence with the eye operated on. When a greater deviation than 15° exists, it is, as a rule, necessary to divide the tendons of both internal recti in cases of convergent strabismus. This proceeding is to be preferred for obvious reasons to that of advancing the attachment of the external rectus, an operation seldom required unless there be decided weakness of this muscle. It is better when we propose a double tenotomy to divide one muscle and allow it time to reunite with the sclerotic, that is, to postpone the second operation to about a fortnight after the first; the result will be better than if we divide both internal recti at one time. If, however, the patient or his friends demur to a second operation, we may divide both muscles at one time.

After tenotomy for strabismus, true binocular vision is seldom procured; but in many cases the eyes work together, preventing a recurrence of the squint, and so improving a person's appearance. On the other hand, especially in adults, one meets with cases in which, after tenotomy, distressing diplopia manifests itself and continues in spite of prisms or any other aid, such as weakening the opposing muscle, which the surgeon can devise. It is seldom advisable to perform tenotomy for strabismus before a child has come to such an age as to be able to wear spectacles, that is from three to five years of age; but so soon as the patient begins to read it is well not to delay the operation; in cases where the angle of the strabismus exceeds 15° , the sight of the squinting eye soon begins to deteriorate and the external rectus to fail in power.

Operation for Advancement of a Rectus Muscle.—Various operations have been advocated for effecting this purpose. The patient having been placed under the effects of an anæsthetic, and the stop speculum applied, the eye is to be

thoroughly bathed with a solution of boracic acid. A vertical incision is then to be made through the conjunctiva over the muscle to be advanced; the incision should be of such an extent, as to enable us fully to expose the rectus. A strabismus hook is passed under the muscle, so as freely to separate it from the globe of the eye, and two fine silk threads are then passed through the insertion of the tendon of the muscle, one from above, downwards, and the other from before, backwards. In like manner two sutures are passed through the muscle some little distance behind the hook, according to the amount of advancement required, the muscle is then divided between the sutures, passed through the tendon and the muscle, which are tied together securely by means of the sutures, so as to bring the end of the muscle and tendon into close apposition. The sutures are then cut off close to the muscle and the wound having been washed with a solution of boracic acid, its edges are to be brought together by means of catgut sutures. In several cases, we have, after bringing the ends of the divided muscle together, passed two fine catgut stitches through the tendon and muscle at the line of division, our object being to give additional security and perfect apposition between these structures until union had taken place. Before the eye is closed it should be again washed, and subsequently a pad of absorbent antiseptic gauze applied over it. The dressing may be changed every twenty-four hours, but it is necessary to keep the eye closed for a week or ten days, otherwise the sutures are apt to cut their way through the muscle, its divided end does not then unite with the tendon and the last condition of the patient is made worse than the first by our operation.

NYSTAGMUS consists in a peculiar oscillation of the eyeballs; this oscillation is almost always in the horizontal direction. During the period of irregular movements of the eyes the patient complains of diplopia and an utter inability to pursue his ordinary avocation. Nystagmus generally firsts manifests itself in infancy, but it may be caused in after-life in certain circumstances. For instance, men employed in working in our coal mines have to carry on their avocation for hours together leaning on one side, with their gaze fixed above the horizontal line. Occupation of this kind not unfrequently leads to what is known as *miners' nystagmus*. In cases of this kind no lesion of the optic nerve can be recognized, but the

oscillating movements of the eyes prevent the patient from continuing his work.

The treatment of instances of miners' nystagmus consists in resting the eyes ; after a complete cessation from work the muscles regain their functions, and the oscillations of the eyeballs cease. The relief is, however, usually temporary, the irregular movements of the eyes too often returning when the miner resumes his occupation. Rest is the only means which affords any relief in these cases. Among infants the nystagmus is generally associated with anomalies of refraction, together with opacities of the cornea or lens, and in many cases with irreparable lesions of the optic nerve or retina.

SECTION II.

ERRORS OF REFRACTION AND ACCOMMODATION.

THE REFRACTION OF THE EYE.

CHAPTER XVII.

OPTICS.

LIGHT is propagated from a luminous point in every plane and in every direction in straight lines ; these lines of direction are called *rays*. Rays travel with the same rapidity so long as they remain in the same medium.

The denser the medium the less rapidly does the ray of light pass through it.

Rays of light diverge, and the amount of divergence is proportionate to the distance of the point from which they come ; the nearer the source of the rays the more they diverge.

When rays proceed from a distant point such as the sun, it is impossible to show that they are not parallel, and in dealing with rays which enter the eye, it will be sufficiently accurate to assume them to be parallel when they proceed from a point at a greater distance than 6 mètres.

A ray of light meeting with a body, may be *absorbed*, *reflected*, or if it is able to pass through this body, it may be *refracted*.

Reflection.

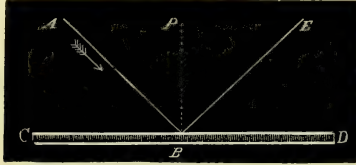
Reflection by a Plane Surface.

Reflection takes place from any polished surface and according to two laws.

1st.—The angle of reflection is equal to the angle of incidence.

2nd.—The reflected and incident rays are both in the same plane, which is perpendicular to the reflecting surface.

FIG. 72.

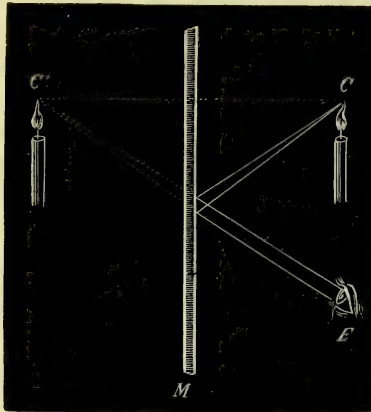


Thus, if AB be the ray incident at B , on the mirror CD , and BE the ray reflected, the perpendicular PB , will divide the angle ABE into two equal parts, the angle ABP is equal to the angle PBE ; and AB , PB and EB lie in the same plane.

When reflection takes place from a plane surface, the image is projected backwards to a distance behind the mirror, equal to the distance of the object in front of it, the image being of the same size as the object.

Thus in Fig. 73 the image of the candle c , is formed behind

FIG. 73.



M . The mirror. c . The candle. c' . The virtual image of the candle.
 E . The eye of the observer receiving rays from mirror.

the mirror M , at c' , a distance behind the mirror, equal to the distance of the candle in front of it, and an observer's eye placed at E , would receive the rays from c as if they came from c' .

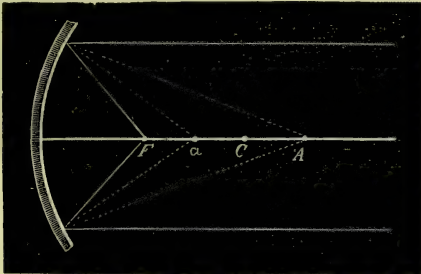
The image of the candle so formed by a plane mirror is called a *virtual image*.

Reflection by a Concave Surface.

A concave surface may be looked upon as made up of a number of planes inclined to each other.

Parallel rays falling on a concave mirror are reflected as convergent rays, which meet on the axis at a point (F , Fig. 74) called the *principal focus*, about equally distant from the

FIG. 74.



mirror and its centre c . The distance of the principal focus from the mirror is called the focal length of the mirror.

If the luminous point be situated at F , then the diverging rays would be reflected as parallel to each other and to the axis.

If the point is at the centre of the concavity of the mirror (c), the rays return along the same lines, so that the point is its own image.

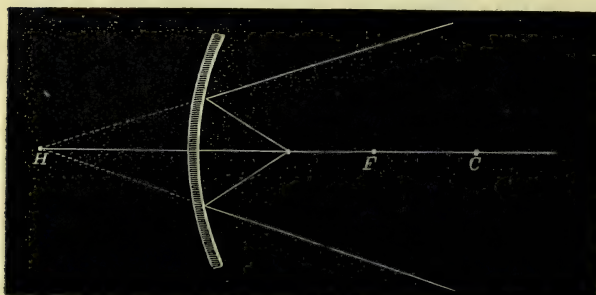
If the point be at A , the focus will be at a , and it will be obvious that if the point be moved to a , its focus will be at A ; these two points therefore, A and a , bear a reciprocal relation to each other and are called *conjugate foci*.

If the luminous point is beyond the centre, its conjugate focus is between the principal focus and the centre.

If the luminous point is between the principal focus and the centre, then its conjugate is beyond the centre; so that the nearer the luminous point approaches the principal focus, the greater is the distance at which the reflected rays meet.

If the point be nearer the mirror than F the principal focus, the rays will be reflected as divergent and will therefore never meet; if, however, we continue these diverging rays backwards, they will unite at a point (H)

FIG. 75.



behind the mirror; this point is called the *virtual focus*, and an observer situated in the path of reflected rays will receive them as if they came from this point.

Thus it follows that—


Concave mirrors produce two kinds of images or none at all, according to the distance of the object, as may be seen by looking at oneself in a concave mirror; at a certain distance one sees a small and inverted image, at a less distance the image is confused and disappears when at the focus; still nearer, the image is erect and larger, being then a virtual image.

Reflection by a Convex Surface.

Parallel rays falling on such a surface become divergent, hence never meet, but if the diverging rays thus formed are carried backwards by lines, then an imaginary image is formed which is called *negative*, and at a point called the *principal focus* (F).

Foci of convex mirrors are virtual; and the image, whatever the position of the object, is always virtual, erect, and smaller than the object.

FIG. 76.



The radius of the mirror is double the principal focus.

Refraction.

Refraction by a Plane Surface.

A ray of light passing through a transparent medium into another of a different density is refracted, unless the ray fall perpendicular to the surface separating the two media, when it continues its course without undergoing any refraction (Fig 77, H K).

A ray is called *incident* before passing into the second medium, *emergent* after it has penetrated it.

A ray passing from a rarer to a denser medium is refracted towards the perpendicular; as shown in Fig. 77, the ray A B is refracted at B, towards the perpendicular P P.

In passing from the denser to the rarer medium the ray is refracted from the perpendicular, B D is refracted at C from P P (Fig. 77).

Reflection accompanies refraction, the ray dividing itself at the point of incidence into a refracted portion B C and a reflected portion B E.

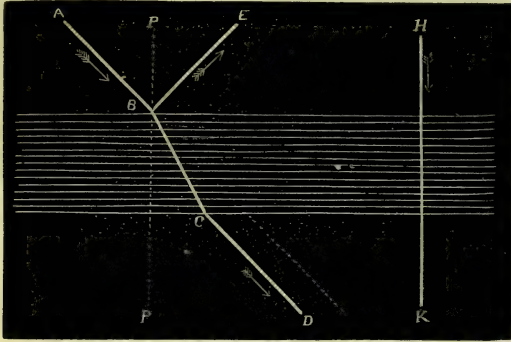
The amount of refraction is the same for any medium at the same obliquity and is called the index of refraction; air is taken as the standard and is called 1; the index of refrac-

tion of water is 1.3, that of glass 1.5. The diamond has almost the highest refractive power of any transparent substance and has an index of refraction of 2.4. The cornea has an index of refraction of 1.3 and the lens 1.4.

The refractive power of a transparent substance is not always in proportion to its density.

If the sides of the medium are parallel, then all rays, except those perpendicular to the surface which pass through

FIG. 77.



without altering their course, are refracted twice, as at B and C (Fig. 77), and continue in the same direction after passing through the medium, as they had before entering it.

If the two sides of the refracting medium are not parallel, as in a prism, the rays cannot be perpendicular to more than one surface at a time.

Therefore every ray falling on a prism must undergo refraction, and the deviation is always towards the base of the prism.

FIG. 78.

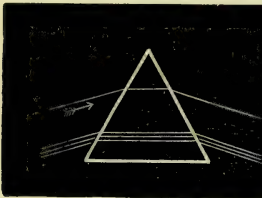
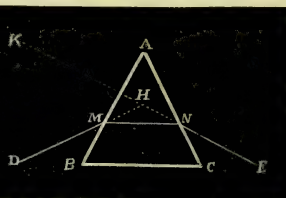


FIG. 79.



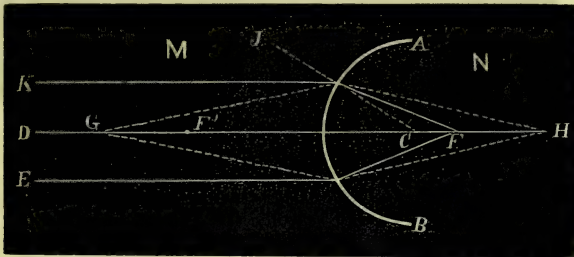
The relative direction of the rays is unaltered (Fig. 78).

If DM (Fig. 79) be a ray falling on a prism (ABC) at M , it is bent towards the base of the prism, assuming the direction MN ; on emergence it is again bent at N , an observer placed E would receive the ray as if it came from K ; the angle KHD formed by the two lines at H is called the *angle of deviation*, and is about half the size of the *principal angle* formed at A by the two sides of the prism.

Refraction by a Spherical Surface.

Parallel rays passing through such a surface separating media of different density, do not continue parallel, but are refracted, so that they meet at a point called the *principal focus*.

FIG. 80.



If parallel rays K, D, E , fall on AB , a spherical surface separating the media M and N of which N is the denser, ray D , which strikes the surface of AB at right angles, passes through without refraction and is called the *principal axis*; ray K will strike the surface at an angle and will therefore be refracted towards the perpendicular CJ , meeting the ray D at F ; so also with ray E , and all rays parallel in medium M . The point F , where these rays meet, is the *principal focus*, and the distance between the principal focus and the curved surface is spoken of as the *principal focal distance*.

Rays proceeding from F will be parallel in M after passing through the refracting surface. Rays parallel in medium N will focus at F' , which is called the *anterior focus*.

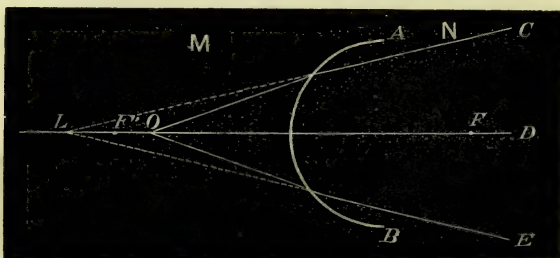
Had the rays in medium M been more or less divergent, they would focus on the principal axis at a greater distance

than the principal focus say at H , and conversely rays coming from H would focus at G , these two points are then *conjugate foci*.

When the divergent rays focus at a point on the axis twice the distance of the principal focus, then its conjugate will be at an equal distance on the other side of the curved surface.

If rays proceed from a point O , nearer the surface than its principal focus, they will still be divergent after passing through $A B$ and will therefore never meet; by continuing

FIG. 81.




these rays backwards they will meet at L , so that the conjugate focus of O will be at L , on the same side as the focus; and the conjugate focus will, in this case, be spoken of as *negative*.

Refraction by Lenses.

Refraction by lenses is somewhat more complicated.

A lens is an optical contrivance usually made of glass, and

FIG. 82.



consists of a refracting medium with two opposite surfaces,

one or both of which may be segments of a sphere, they are then called spherical lenses, of which there are six varieties.

1. Plano-convex, the segment of one sphere (Fig. 82, B).
2. Biconvex, segments of two spheres (Fig. 82, A).
3. Converging concavo-convex, also called a converging meniscus.
4. Plano-concave.
5. Biconcave.
6. Diverging concavo-convex, called also a diverging meniscus.

Lenses may be looked upon as made up of a number of prisms with different refracting angles—convex lenses, of prisms placed with their bases together; concave lenses, of prisms with their edges together.

A ray passing from a less refracting medium (as air)

FIG. 83.



through a lens, is deviated towards the thickest part, therefore, the three first lenses, which are thickest at the centre, are called *converging*; and the others, which are thickest at the borders, *diverging*.

A line passing through the centre of the lens (called the *optical centre*) at right angles to the surfaces of the lens, is termed the *principal axis*, and any ray passing through that axis is not refracted.


All other rays undergo more or less refraction.

Rays passing through the optical centre of a lens, but not through the principal axis, suffer slight deviation, but emerge in the same direction as they entered; the deviation in thin lenses is so slight that they are usually assumed to pass through in a straight line; these are called *secondary axes* (Fig. 84).

Parallel rays falling on a biconvex lens are rendered

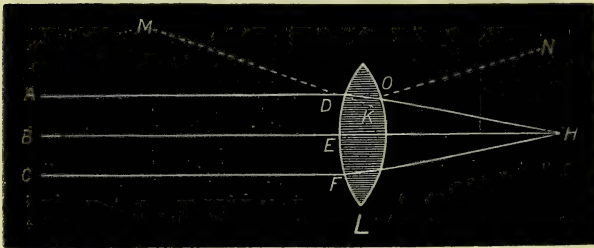
convergent; thus in Fig. 85 the rays A, B, C, strike the surface of the lens (L) at the points D, E, F; the centre ray (B) falls on the lens at E perpendicular to its surface, and therefore passes through in a straight line; it also emerges from the lens at right angles to its opposite surface, and so continues its course without deviation; but the ray (A) strikes the surface of the lens obliquely at D, and as the ray is passing from one medium (air) to another (glass) which

FIG. 84.



Lens with secondary axes undergoing slight deviation.

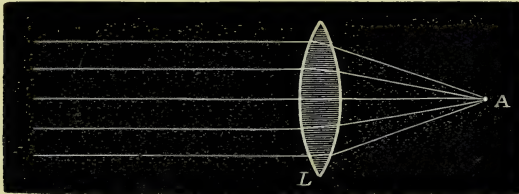
FIG. 85.



is of greater density, it is bent towards the perpendicular of the surface of the lens, shown by the dotted line MK ; the ray after deviation, passes through the lens, striking its opposite surface obliquely at O , and as it leaves the lens, enters the rarer medium (air), being deflected from the perpendicular NO ; it is now directed to H , where it meets the central ray BH ; ray C , after undergoing similar refractions meets the other rays at H , and so also all parallel rays falling on the biconvex lens (L).

Parallel rays, therefore, passing through a convex lens (L), are brought to a focus at a certain fixed point (A) beyond the

FIG. 86.

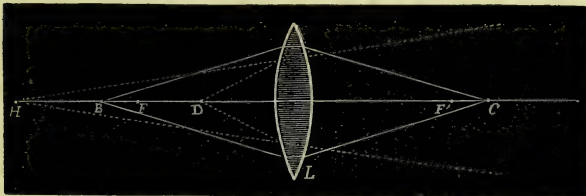


lens; this point is called the *principal focus*, and the distance of this focus from the lens is called the focal length of the lens.

Rays from a luminous point placed at the principal focus (A) emerge as parallel after passing through the lens.

Divergent rays from a point (B) outside the principal focus (F, Fig. 87) meet at a distance beyond (F') the principal focus on the other side of the lens (L), and if the distance of the luminous point (B) is equal to twice the focal length

FIG. 87.



of the lens, the rays will focus at a point (C) the same distance on the opposite side of the lens, rays coming from C would also focus at B, they are therefore called conjugate foci, for we can indifferently replace the image (C) by the object (B) and the object (B) by the image (C).

If the luminous point (D) be between the lens and the principal focus (F), then the rays will issue from the lens divergent, though less so than before entering; and if we prolong them backwards they will meet at a point (H) further from the lens than the point D; H will therefore be

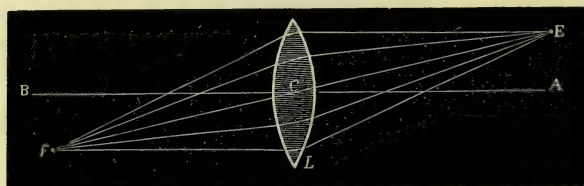
the virtual focus of D , and the conjugate focus of D may be spoken of as *negative*.

Biconvex lenses have therefore two principal foci, F and F' , one on either side, at an equal distance from the centre.

In ordinary lenses, and those in which the radii of the two surfaces are nearly equal, the principal focus closely coincides with the centre of curvature.

We have assumed the luminous point to be situated on the principal axis; supposing, however, it be to one side of it at E (Fig. 88), then the line ($E F$) passing through the optical

FIG. 88.

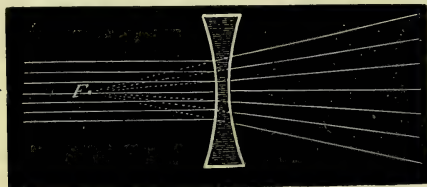


centre (C) of the lens (L) is a secondary axis, and the focus of the point E will be found somewhere on this line, say at F , so that what has been said respecting the focus of a luminous point on the principal axis ($A B$), is equally true for points on a secondary axis, provided always that the inclination of this secondary axis is not too great, when the focus would become imperfect from much spherical aberration.

In biconcave lenses the foci are always virtual whatever the distance of the object.

Rays of light parallel to the axis diverge after refraction,

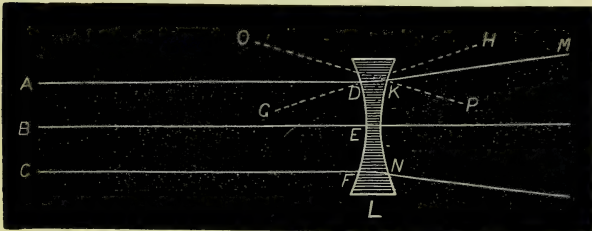
FIG. 89.



and if their direction be continued backward, they will meet at a point termed the principal focus (Fig. 89, F).

Fig. 90 shows the refraction of parallel rays by a biconcave lens (L); the centre ray B, strikes the lens at E perpendicular to its surface, passing through without refraction, and as it emerges from the opposite side of the lens perpendicular to its surface, it continues in a straight line; the ray A, strikes the lens obliquely at D and is refracted towards the

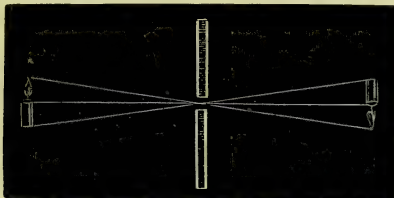
FIG. 90.



perpendicular, shown by the dotted line G H; the ray, after deviation, passes through the lens to K, where, on entering the medium of less density obliquely, it is refracted from the perpendicular O P, in the direction K M; the same takes place with ray C, at F and N, so also with all intermediate parallel rays.

Formation of images.—To illustrate the formation of images the following simple experiment may be carried out:—Place on one side of a screen having a small perforation, a candle, and on the other side a sheet of white cardboard at some distance from the object, to receive the image formed; rays diverge from the candle in all directions, most of those falling on the screen are intercepted by it, but some few rays pass through the perforation and form an image of

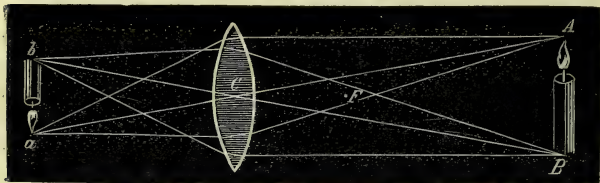
FIG. 91.



the candle on the cardboard, the image being inverted, because the rays cross each other at the orifice; it can further be shown that when the candle and cardboard are equally distant from the perforated screen, the candle flame and its image will be of the same size. If the cardboard be moved further from the perforation the image is enlarged, if it be moved nearer it is diminished; if we make a dozen more perforations in the screen, a dozen more images will be formed on the cardboard, if a hundred, then a hundred, but if the apertures come so close together that the images overlap, then instead of so many distinct images, we get a general illumination of the cardboard.

The image of an object is the collection of the foci of its several points; the images formed by lenses are, as in the case of the foci, real or virtual. Images formed, therefore, by convex lenses may be real or virtual.

FIG. 92.



Real inverted image formed by convex lens.

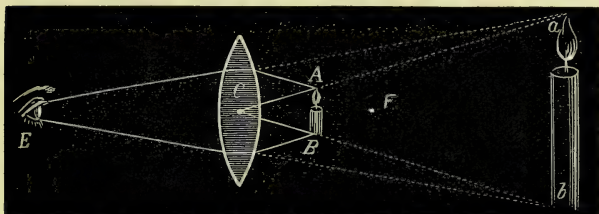
In Fig. 92, let $A B$ be a candle situated at an infinite distance, from the extremities of $A B$, draw two lines passing through the optical centre (c) of a biconvex lens, the image of A will be formed somewhere on this line (termed a secondary axis), say at a , rays from B at b , so $b a$ is a small inverted image of the candle $A B$, formed at the principal focus of the convex lens. Had the candle been placed at twice the focal distance of the lens, then its image would be formed at the same point on the opposite side of the lens, of the same size as the object, and inverted.

If the candle be at the principal focus (F) then the image is at an infinite distance, the rays after refraction being parallel.

If, however, the candle ($A B$) be nearer the lens than the focus, then the rays which diverge from the candle will,

after passing through the convex lens, be still divergent, so that no image is formed; an eye placed at *E* would receive the rays from *A B* as if they came from *a b*; *a b* is therefore

FIG. 93.

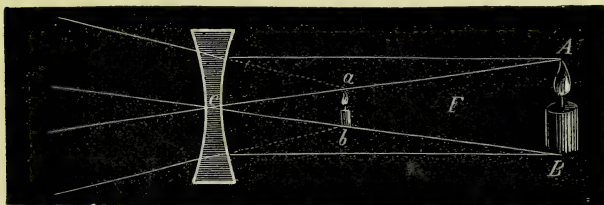


Virtual image formed by convex lens.

a virtual image of *A B*, erect and larger than the object, and formed on the same side of the lens as the object.

Images formed by biconcave lenses are always virtual, erect, and smaller than the object; let *A B* be a candle, and *F* the principal focus of a biconcave lens, draw from *A B* two lines through *c*, the optical centre of the lens, and lines also from *A* and *B* parallel to the axis, after passing through the lens they diverge and have the appearance of coming from *a b*, which is therefore the virtual image of *A B*.

FIG. 94.





Virtual image formed by concave lens.

A real image can be projected on to a screen, but a virtual one can only be seen by looking through the lens.

The *cylindrical lens* still remains to be mentioned; it consists of a lens, one surface of which is usually plane, while the other is the segment of the cylinder, and may be either con-

vex or concave; if a convex cylinder be held vertically, the vertical meridian will be plane, exercising no influence on rays passing through it in that meridian, while the horizontal meridian will be convex, and will act as such on rays passing through it. The axis of the cylinder is usually indicated by a portion of the lens on each side being ground, parallel to this axis.



CHAPTER XVIII.

REFRACTION. ACCOMMODATION. CONVERGENCE.

THE eye may be looked upon as an optical instrument, a sort of photographic camera, designed to produce by means of its refracting system a small and inverted picture of surrounding objects upon the retina; the stimulation produced by this picture is conducted by the optic nerve to the brain, which must be able to interpret correctly the impressions thus transmitted to it. Immediately behind the transparent retina is a layer of pigment, which absorbs the rays of light as soon as the image is formed; were this not so the rays would be reflected to other parts of the retina, and cause much dazzling, considerably interfering with vision, as in the case of albinos.

The refracting system of the eye is so arranged that but little, if any, spherical or chromatic aberration takes place, as is the case with ordinary optical instruments.

For distinct and accurate vision the following conditions are necessary:—

1. That a well-defined inverted image be formed on the layer of rods and cones at the yellow spot.

2. That the impression there received be conveyed to the brain.

In a work of this character the first of these conditions alone concerns us, and for the carrying out of this—the media being transparent—three important factors call for a separate description, viz.:—

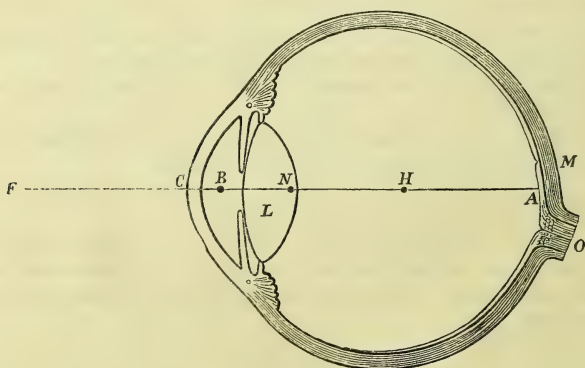
Refraction.
Accommodation.
Convergence.

Refraction.—This term is used to express the optical condition of the eye in a state of rest. There are three refracting surfaces in the eye—the anterior surface of the cornea, the anterior surface of the lens, and the anterior surface of the vitreous; and three refracting media, the aqueous, the lens, and the vitreous. These together make up the dioptric system, and may for the sake of simplicity be looked upon as equal to a convex lens of about 23 mm. focus. What was said about convex lenses applies equally to the eye as an optical instrument.

A ray of light falling on the cornea does not, however, follow the simple direction we might imagine when considering the eye merely as a lens of 23 mm. focus, but it must be looked upon as a compound system, composed of a spherical surface and a biconvex lens. To enable us to understand the course of a ray through the eye, it is necessary to be acquainted with the cardinal points of this compound system; too much space would be occupied to explain how the position of these points is arrived at, but it suffices to say, that having first found the cardinal points of the cornea and then those of the lens, the cardinal points of the eye will be the result of these two systems together.

The cardinal points of the eye are six in number, *two principal points, two nodal points and two principal foci*. In

FIG. 95.



the above diagram of the emmetropic eye the cardinal points of this compound system are shown, all situated on the optic

axis (F A); at B are two principal points, situated so closely together in the anterior chamber, that they may conveniently be looked upon as one point; at N are two nodal points, also close together, for simplicity we shall consider them as one point; at F is the first principal focus; at A the second principal focus. We then have the following: C, the cornea; L, the lens; M, the macula; O, the optic nerve; F A, the optic axis; B, the principal point; N, the nodal point; H, the centre of rotation of the eye, 9.2 mm. in front of the retina; A, the second principal focus; and F the first principal focus.

The *nodal points* correspond nearly to the optical centre, the axis ray passing through these points is not refracted; every ray directed to the first nodal point, appears after refraction to come from the second point, and continues in the same direction to that which it first had: the nodal points in the eye are situated about 7 mm. behind the cornea.


The *principal points*. When an incident ray passes through the first principal point, the corresponding emergent ray passes through the second principal point, but the incident and emergent ray are not parallel: the principal points are situated about 2 mm. behind the cornea.

The *first principal focus* is that point on the axis where rays parallel in the vitreous meet, this point is about 13.7 mm. in front of the cornea.

The *second principal focus* is that point on the axis where parallel rays meet after passing through the eye, 22.8 mm. behind the cornea.

A luminous point placed above the principal axis forms its image on the retina below this axis, and inversely, the image of a point below the principal axis will be formed above it. If we replace these two points by an object the

FIG. 96



same thing occurs, and we get an *inverted* image (Fig. 96);

it is essential that the method of formation of these inverted images be thoroughly understood.

From every point of an object $A B C$, proceed divergent rays. Some of those coming from A pass through the pupil, and being refracted by the dioptric system, come to a focus on the retina at a : some coming from B focus at b , and some from C at c . In the same way rays come from every point of the object as divergent rays, and are brought to a focus on the retina; so that the retina being exactly at the focal distance of the refracting system, receives a well-defined inverted image.

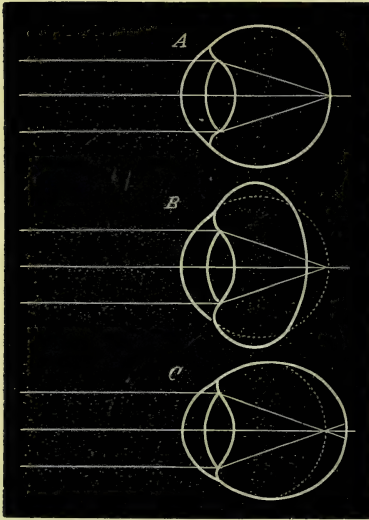
Much has been said and written as to why images which are formed in an inverted position on the retina should be seen upright, and all sorts of ingenious explanations have from time to time been given. The whole thing is entirely a matter of education and experience, which is supplemented and corroborated by the sense of touch. We have no direct cognisance of the image on the retina, nor of the position of its different parts, but only of the stimulation of the retina produced by the image; this stimulation is conducted by the optic nerve to the brain, producing there certain molecular changes. We do not actually see the retinal image, but the object from which the rays emanate, and we refer the sensation in their direction; thus, if an image is formed on the upper part of our retina, we refer the sensation downwards from which the rays must have come.

The great advantage of inverted images is that for a given sized pupil a much larger retinal picture can be formed, than would be the case if no inversion took place; for in the latter case all images must necessarily occupy a smaller space on the retina than the size of the pupil.

The refraction of the eye is said to be normal, when parallel rays are united exactly on the layer of rods and cones of the retina; in other words, when the retina is situated exactly at the principal focal distance of the refracting system of the eye. This condition is called *emmetropia* ($E\mu$, within, $\mu\acute{\epsilon}\tau\rho\nu$, measure, $\acute{\omega}\psi$, the eye) (Fig. 97, A). If parallel rays are focussed behind, or in front of the retina, then the term *ametropia* (a , priv., $\mu\acute{\epsilon}\tau\rho\nu$, measure, $\acute{\omega}\psi$, the eye) is used, and of this there are two opposite varieties:—

Hypermetropia, when the eyeball is so short, that parallel rays are brought to a focus behind the retina (Fig. 97, B).

FIG. 97.



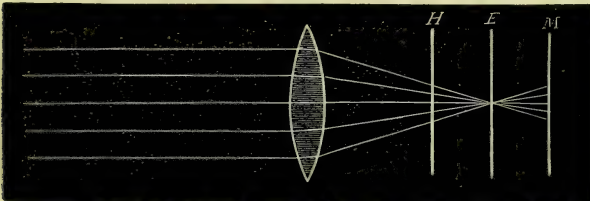
A. Emmetropic eye. B. Hypermetropic eye. C. Myopic eye.

Myopia, when the eyeball is too long, so that parallel rays focus in front of the retina (Fig. 97, c).

Emmetropia in a strict mathematical sense is very rare.

If we represent the eye by a biconvex lens and the retina by a screen, emmetropic when situated at the principal focus of the lens as E Fig. 98, we make it hypermetropic (H) by

FIG. 98.



Convex lens of 23 mm. focus. Parallel rays focus at E (emmetropia) on the screen, forming a well-defined image of object from which rays come; at H (hypermetropia) they form a diffusion patch instead of an image. M (myopia), also a diffusion patch, the rays having crossed and become divergent.

bringing forward the screen, and myopic (M) by moving it further away from the lens.

In all eyes, vision ranges from the far point or punctum remotum (which in the emmetropic eye is at infinity), to the near point or punctum proximum.

The near point varies in the normal eye, according to the amount of the accommodation; receding gradually as age advances; when it has receded beyond 22 cm. (which usually occurs in the emmetropic eye about the age of forty-five), the condition is spoken of as *presbyopia*.

Infinity is any distance beyond 6 metres, the rays coming from a point at or beyond that distance being parallel, or almost so.

The emmetropic eye therefore, has its far point, or punctum remotum, situated at infinity: the hypermetropic eye has its punctum remotum beyond infinity, and the myopic eye its punctum remotum at a finite distance.

Generally the two eyes are similar in their refraction, though sometimes there is a very great difference. One may be hypermetropic, the other myopic; or one emmetropic the other ametropic. *Anisometropia* is the term used when the two eyes thus vary in their refraction.

There may be differences also between the refraction in the different meridians of the same eye—*astigmatism*.

In all forms of ametropia the acuteness of vision is liable to be diminished. The visual acuteness usually decreases slightly as age advances, without any disease.

The acuteness refers always to central vision. The yellow spot is the most sensitive part of the retina, and the sensibility diminishes rapidly towards the periphery. The acuteness is measured by the size of the visual angle, that is, the angle formed at the posterior nodal point, which point closely coincides with the posterior surface of the lens, and is about 15 mm. in front of the yellow spot.

In Fig. 99, let CD be an object for which the eye is accommodated. The lines Cc , Dd , drawn from the extremities of the object, cross at the nodal point N . The angle CND , will be the visual angle under which the object CD is seen. The size of the angle depends upon the distance of the object as well as upon its magnitude, and the size of the image thus formed on the retina will also depend upon the antero-posterior length of the eyeball.

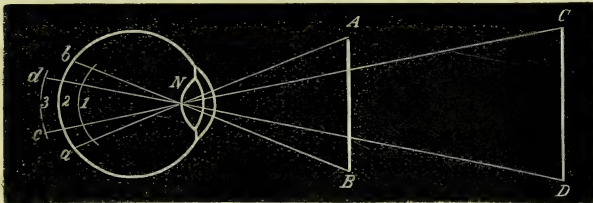
Thus an object AB , which is as large as CD , but nearer to

the eye, will be seen under a larger angle, the angle, $A N B$ being greater than $C N D$. It is also clear that the image formed on the retina will be smaller at 1, when the antero-posterior diameter of the eye is less, as in hypermetropia, than it is at 2 in emmetropia, and that it will be larger in myopia, as at 3, where the eyeball is elongated. It is, therefore, easy to understand that a patient may be able to read the smallest type and still have some defect of refraction, unless the type be read at its proper distance (see Fig. 106).

It is by the unconscious comparison of things of known size, and the amount of accommodation brought into play, that we are able to estimate the distance of objects, and not by the visual angle alone.

Objects must therefore be of a certain size, and it has been proved, that to enable us to see a complex figure like a letter distinctly, each part of the figure must be separated from

FIG. 99.



the other parts, by an interval, equal to not less than the arc subtending an angle of $1'$ at the nodal point.

It has been shown (Fig. 97, B), that in the hypermetropic eye, when in a state of rest, parallel rays are brought to a focus behind the retina, so that instead of a clear, well-defined image, we get a circle of diffusion. Convex glasses render parallel rays passing through them convergent, so that by placing a lens of the right strength in front of the hypermetropic eye, we bring forward its focus on to the retina.

In myopia (Fig. 97, c), where the focus is in front of the retina, we succeed by concave glasses in carrying back the focus.

Lenses.—These lenses are spherical, and were until recently numbered according to their radii of curvature,

which was considered as equal to their focal length in inches, a glass of 1 inch focus being taken as a standard. To this plan there were several objections. The standard glass being a strong one, weaker glasses had to be expressed in fractions. Thus a glass of 4 inch focus was one-fourth the strength of the standard 1 inch, and was expressed as $\frac{1}{4}$. In addition to the trouble and inconvenience of working with fractions, the intervals between the lenses were most irregular, and, moreover, the inches of different countries vary. At the Ophthalmological Congress in 1872, it was decided to adopt a metrical scale of measurement. A lens of 1 metre focus was taken as the unit, and was called a dioptré; a weak instead of a strong glass therefore becoming the unit, a lens of two dioptrés is twice the strength of the former, and has a focal length of half a metre. Thus each lens is numbered according to its refracting power, and not, as in the old system, according to its focal length; so that we have a series composed of equidistant terms. The numbers 1 to 20 indicate the uniformly increasing power of the glasses.

The focal length of a lens is not expressed in the dioptric measurement; we have only to remember that it is the inverse of the refracting power; so that by dividing 100 cm. by the number of the lens, we obtain its focal length in centimetres, for example, if the lens be 2 D. then the focal length will be 50 cm., if 10 D. then 10 cm.

The intervals between dioptrés is somewhat large, so that decimals .25, .50, .75 of a dioptré were introduced; these work easily.

Convex glasses magnify and concave ones diminish the size of objects.

Cylindrical lenses have already been referred to on page 437.

Accommodation.—In the normal eye, in a condition of complete repose, parallel rays come to a focus exactly on the rods and cones of the retina, and the object from which they come is therefore seen distinctly.

Rays from a near object proceed in a divergent direction, and come to a focus behind the retina; the object would not then be clearly seen, unless the eye possessed within itself the power of bringing rays which are more or less divergent into union on the retina.

This power of altering the focus of the eye at will, is called *accommodation*, and is due to an alteration in the form of the

lens. That the eye possesses this power can easily be proved in many ways, apart from the conscious muscular effort; perhaps as simple a way as any to demonstrate it to oneself, is to look through a net held a short distance off, at some distant object. Either the net or the object can be seen distinctly, but not both at once. If the meshes of the net be looked at, then the distant object becomes indistinct, and on looking at the object the meshes become confused.

Accommodation, therefore, increases the refraction of the eye and adapts it to near objects. The changes which take place in the lens during accommodation are—

1st. The anterior surface becomes more convex and approaches the cornea.

2nd. The posterior surface becomes slightly more convex, but remains equally distant from the cornea.

That these changes take place may be proved in the following manner: a small candle flame, or other convenient object, being held on one side of the eye, so as to form an angle of 30° with its visual axis, an observer looking into the eye from a corresponding position on the other side, will see three images of the flame, the first upright, formed by the cornea, the second larger, upright and formed by the anterior surface of the lens, the third smaller and inverted, formed by the posterior surface of the lens; when accommodation is put in force, images one and three remain unchanged in shape and position; image two, which is that formed by the anterior surface of the lens, becomes smaller, more distinct, and approaches image one, proving that this surface of the lens has become more convex and has approached the cornea. In an emmetropic eye adapted for infinity, it has been proved that the radius of curvature of the anterior surface of the lens is 10 mm., when accommodated for an object 13.5 cm. off, it is changed to 6 mm.

The pupil also becomes smaller, the central part advances, while the peripheral part slightly recedes.

The alteration in the shape of the lens is due to the contraction of the ciliary muscle, which draws forward the choroid, thereby relaxing the suspensory ligament and allowing the elasticity of the lens to come into play. This elasticity is due to the peculiar watchspring arrangement of the lens fibres.

When the ciliary muscle is relaxed, the suspensory ligament returns to its former state of tension, and so tightens the

anterior part of the capsule, flattening the front surface of the lens.

FIG. 100.

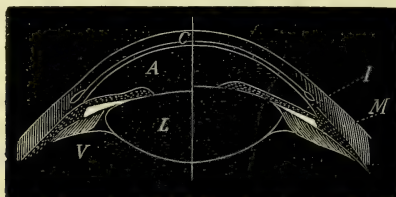


Diagram of lens, cornea, &c. The right half is represented as in a state of accommodation, the left half at rest. A. The anterior chamber. C. The cornea. L. The lens. V. The vitreous humour. I. The iris. M. Ciliary muscle.

When the muscle is thus relaxed to its uttermost the lens has assumed its least convexity, and the eye is then adapted for its far point (*punctum remotum*) (*r*).

In this condition the eye is spoken of as being in a state of complete repose.

When the ciliary muscle has contracted as much as it can, the lens has assumed its greatest convexity, and its maximum amount of accommodation is now in force. This point is the nearest for which the eye can accommodate itself, and is called the *punctum proximum* (*p*).

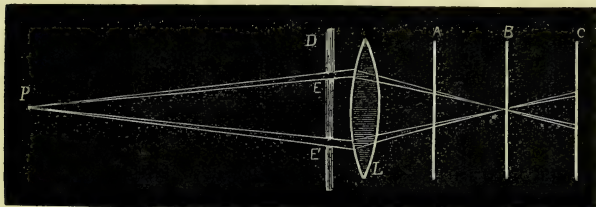
In the emmetropic eye the *punctum remotum* is situated at infinity.

The position of the *punctum proximum* can be determined in several ways; the ordinary plan is to place in the patient's hand the small test-type and note the shortest distance at which he can read No. 1 with each eye separately; or we may measure it with the wire optometer, which consists of a steel frame crossed by thin vertical wires; this is supported in a handle to which a tape measure is attached, the tape is placed against the temple, and held there while the frame is made gradually to recede from the patient's eye we are examining, stopping as soon as the wires become distinct, and reading off the number of centimetres on the measure. Another excellent plan by which to find the position of the *punctum proximum* is that of Scheiner; close in front of the eye we wish to examine, is placed a card

pierced with two small pin-holes, which must not be further apart than the diameter of the pupil, through these two holes the patient is directed to look at a pin held about one metre away (the other eye is of course excluded from vision during the experiment); the pin will be clearly and distinctly seen, we then gradually approach it to the eye; at a certain place it will become double, the point at which the pin ceases to appear single will be the punctum proximum.

In Fig. 101 the biconvex lens *L* represents the eye, *D* the perforated card, *P* the pin, *E E'*, the two sets of rays from *P*, which focus exactly at *B* the retina. If, however, the pin be brought nearer, so that the accommodation is unable to focus the two sets of rays, they will form instead of one, two images of the pin on the retina as at *A*. These will be projected outwards as crossed images.

FIG. 101.



The distance between the punctum remotum and the punctum proximum is called *the range of accommodation*.

The force necessary to change the eye from its punctum remotum to its punctum proximum is styled the *amplitude of accommodation*. The amplitude of accommodation therefore is equal to the difference between the refracting power of the eye when in a state of complete repose, and when its maximum amount of accommodation is in force, and may be expressed by the formula

$$a = p - r.$$

A convex glass placed in front of the eye produces the same effect as accommodation, *i.e.*, it increases its refraction and adapts the eye for nearer objects. We can easily understand, that the lens which enables an eye to see at its near point without its accommodation, is a measure of the amplitude of accommodation, giving to rays which come

from the near point, a direction as if they came from the far point.

The amplitude of accommodation is much the same in every kind of refraction. If we wish to measure it in an *emmetrope*, we have merely to find the nearest point at which the patient can read small print. A lens whose focal distance corresponds to this, is a measure of the amplitude of accommodation. Thus, supposing 20 cm. the nearest distance at which he is able to read small print, we divide this into 100 cm. to find the focal distance of the lens ($\frac{100}{20} = 5$ D.); and in this case a lens of 5 D. is the measure we require.

Or we can measure it in an inverse manner, by looking at a distant object through a concave glass; the strongest with which we can see this distant object distinctly, is the amplitude of accommodation; the concave glass giving to parallel rays coming from the distant object such an amount of divergence, as if they came from a point situated at the principal focal distance of this glass.

Therefore, the amplitude of accommodation in emmetropia is equal to the refraction when adapted to its punctum proximum and may be expressed by the formula

$$\begin{aligned} a &= p - \infty^* \\ \text{or } a &= p - 0 \\ \text{or } a &= p. \end{aligned}$$

The Accommodation of Hypermetropes.—A hypermetrope requires some of his accommodation for distant objects; we must, therefore, in order to find the amplitude of accommodation in his case, add on to the lens whose focal length equals the distance of the near point, that convex lens which enables him to see distant objects, without his accommodation, and we express it by the formula

$$a = p + r.$$

Thus, to take an example, we will assume the patient's near point to be 25 cm. ($\frac{100}{25} = 4$ D.), and that he has to use 4 D. of accommodation for distant objects, then the amplitude of his accommodation would be 4 D. + 4 D. = 8 D.

The Accommodation of Myopes.—In a myope we have to subtract the glass which enables him to see clearly distant

* ∞ is the sign for expressing infinity.

objects, from that whose focal length equals the distance of the near point. The formula will then be

$$a = p - r.$$

Thus, to find the amplitude of accommodation in a myope of 2 D., the near point being at 10 cm., we subtract from ($\frac{1.00}{10} = 10$) 10 D. the amount of the myopia 2 D. and the resulting 8 D. is therefore the amplitude of accommodation.

Hence it is obvious that with the same amplitude of accommodation, the near point is further away in hypermetropia than in emmetropia, and further in emmetropia than in myopia. Thus an emmetrope, with an amplitude of accommodation of 5 D. would have his near point at ($\frac{1.00}{5} = 20$) 20 cm., a hypermetrope of 2 D., whose amplitude equalled 5 D. would require 2 D. for distance, leaving him 3 D., which would bring his near point to ($\frac{1.00}{3} = 33$) 33 cm.; and a myope of 2 D., who would require a concave glass of this strength to enable him to see at a distance, would have near point of 14 cm. ($\frac{1.00}{7} = 14$) with the same amplitude.

FIG. 102.

Diopres.

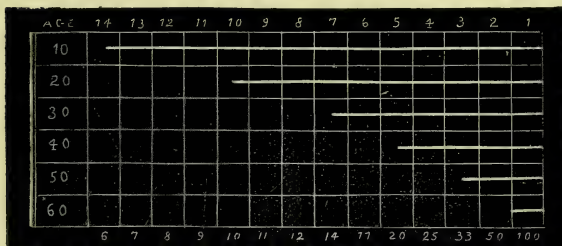


Diagram showing by the number of squares through which the thick lines pass, the amplitude of accommodation at different ages in emmetropia. The figures above, represent the number in diopres of accommodation; those below, the near point for each amount; and those on the left, the age of the individual.

Accommodation is spoken of as *absolute*, *binocular*, and *relative*.

Absolute, is the amount of accommodation which one eye can exert, when the other is excluded from vision.

Binocular, that which the two eyes can exert together, being allowed at the same time to converge.

Relative, that which the two eyes can exert together for any given convergence of the visual lines.

As age advances the elasticity of the lens diminishes, the accommodation therefore becomes less, and the near point gradually recedes. These changes commence at a very early age, long before the individual has come to maturity.

The following table gives the amplitude of accommodation at different ages.

Fig. 102 diagrammatically represents the amplitude of accommodation in emmetropia.

Years.	Amplitude of accommodation.
10	14 D.
15	12 D.
20	10 D.
30	7 D.
40	4.5 D.
50	2.5 D.
60	1 D.
75	0.

Convergence.—This is the remaining element of distinct binocular vision, and with it accommodation is very intimately linked, so that usually for every increase of the convergence, a certain increase in the accommodation takes place.

Convergence is the power of directing the visual axes of the two eyes, to a point nearer than infinity; and is brought about by the action of the internal recti muscles.

When the eyes are completely at rest, the optic axes are either parallel, or more usually, slightly divergent. The angle thus formed between the visual and the optic axis is called the angle a , and varies according to the refraction of the eye. In emmetropia the angle is usually about 5° ; in hypermetropia it is greater, sometimes about 7° or 8° , giving to the eyes an appearance of divergence; in myopia the angle is less, often about 2° , or the optic axis may even, in extreme cases, fall on the inside of the visual axis, when the angle a is spoken of as negative (p. 405); so that in myopia there is frequently an appearance of convergence, giving one the idea of a convergent squint; hence the mere look of the patient's eyes, with regard to their axes, is not always quite reliable.

The object of convergence is the directing of the yellow spot in each eye towards the same point, so as to produce singleness of vision. Diplopia, or double vision, at once resulting, when the image of an object is formed on parts of the retina which do not exactly correspond in the two eyes.

To test the power of convergence prisms are held with their bases outwards. The strongest prism which it is possible to overcome, that is, the prism which does not produce diplopia on looking through it at a distant object, is the measure of the convergence, and varies in different persons, usually between prisms of 20° and 30° , divided between the two eyes.

In considering convergence, we have not only to bear in mind the condition of the internal recti muscles, but also the state of equilibrium, produced by them and the action of their antagonists—the external recti.

The nearer an object, the more we have to converge, and so also with the accommodation. Hence, on converging to any particular point, we usually also involuntarily accommodate for that point, the internal recti and ciliary muscles acting in unison.

Nagel has proposed a very simple and convenient plan, by which we may express the convergence in metres, calling the angle formed by the visual and median lines as at M' , the *metrical angle*. In Fig. 103 E, E' represent the centres of rotation for the two eyes; EHE' is the base line between the eyes. When the eyes are fixed on some distant object, the convergence being passive, the visual lines are parallel or almost so, as $EA, E'A'$, the angle of convergence is then at its minimum, and it is said to be adapted to its *punctum remotum*, this then, being at infinity is expressed, $C^* = \infty$.


If the eyes be directed to an object one metre away, the metrical angle $EM'H$ equals one, *i. e.* $C = 1$. If the object is 50 cm. off, then $C = 2$; if 10 cm. then $(\frac{100}{10} = 10) C = 10$. If the object had been beyond 1 metre (our unit), but not at infinity, say 4 metres, then $C = \frac{1}{4}$.

When the visual lines, instead of being parallel, diverge, then the punctum remotum is found by continuing these lines backwards till they meet at c , behind the eye; the convergence is then spoken of as *negative*.

* C is the sign for convergence.

When the eyes are directed to the nearest point at which they can see distinctly, say at M''' , the angle of convergence

FIG. 103



is at its maximum, and it is said to be adapted to its *punctum proximum*.

The distance between the *punctum proximum* and the *punctum remotum* is the *range of convergence*. The amplitude of convergence is the whole convergence that can be put in force, and we express it by the formula.

$$c = p - r.$$

The *punctum remotum* of convergence is seldom situated at a finite distance, sometimes it is exactly at infinity, but in the majority of cases it is situated beyond infinity, *i. e.* the visual lines diverge slightly. In order to measure this divergence, and so obtain the *punctum remotum* of convergence, we place before the eyes prisms bases inwards (abducting prisms), and the strongest with which the person is still able to see singly is the measure of the negative convergence.

Prisms are numbered in degrees according to the angle of the prism. The deviation produced by a prism is equal to half its angle, thus prism 8 will produce a deviation of the eye of 4° , and prism 20 a deviation of 10° .

When a prism is placed before one eye, its action is equally divided between the two eyes.

To take an example, if an abducting prism of 8° placed before one eye (or what is the same thing 4° before each eye) be found to be the strongest through which a distant object can be seen singly, then each eye in our example has made a movement of divergence equal to 2° , and the *punctum remotum* of convergence in this case is therefore negative, and is expressed -2° . By referring to the table on page 457, it will be seen that when the centres of rotation of the eyes are 6.4 cm. apart, then the metre angle equals $1^\circ 50'$, so we reduce the 2° to metre angles, thus—

$$\frac{2}{1 \ 50} = \frac{120}{110} = 1.09 \text{ m. a.}$$

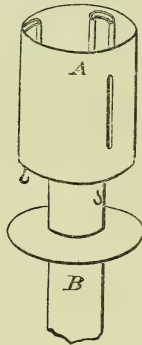
or it is sufficient to remember to divide the prism placed before one eye by seven; thus in our example we should divide prism 8° by seven, and this would give us approximately the same result.

To find the *punctum proximum* of convergence, hold a prism, base outwards (adducting prism) before one eye, and

the strongest which can be so employed without producing diplopia divided between the two eyes, gives the punctum proximum of convergence in degrees. This can be reduced to metre angles as before.

Or a simpler plan is to measure it with Landolt's ophthalmodynamometer, which is a small instrument consisting of a black metallic cylinder, A, made so as to fit upon a candle, B. The cylinder has a vertical slit .3 mm. in breadth, covered by ground glass; the candle being lighted, this forms a luminous line, and will serve as a fixation object. A tape measure is conveniently attached, being graduated in centimetres on one side, and on the other in the corresponding numbers of metre angles.

FIG. 104.



To find the punctum proximum of convergence, the measure is drawn out to about 70 cm., its case being held beside one of the eyes of the patient, while the object of fixation is placed in the median line. If the illuminated line is seen singly, by pressing the knob of the case, the spring rolls up the tape and the fixation object is brought nearer the eye. So soon as the patient commences to see double, the nearest point of convergence is obtained, and the maximum of convergence is read off the tape in metre angles. This experiment should be repeated several times.

In a normal case the minimum of convergence is usually about $-1\ m. a$; the maximum $9.5\ m. a$; so that the amplitude of convergence equals $10.5\ m. a$.

We know that the accommodation increases the nearer the object approaches, hence we see, that both the convergence and accommodation increase and decrease together; and in recording the convergence in the manner proposed by Nagel, it will be seen that in the emmetropic eye the number which expresses the metrical angle of convergence, expresses also the state of refraction for the same point—this is a great advantage. Thus when looking at a distant object, the angle of convergence is at infinity, $C = \infty$, and the refraction is also at infinity, $A = \infty$. When the object is at 1 metre the angle of convergence = 1, and the amount of accommodation put into play = 1·D. When the object is at 25 cm. then the angle of convergence = 4, and the amount of accommodation = 4 D.

The amplitude of convergence is somewhat greater than the amplitude of accommodation, passing it both at its punctum remotum and its punctum proximum.

The following table shows the angle of convergence in degrees, for different distances of the object, when the eyes are 6·4 cm. apart :

Distance of the object from the eyes.		The metrical angle.		Value expressed in degrees.
1 metre	..	1	..	1° 50'
50 cm.	..	2	..	3° 40'
33 "	..	3	..	5° 30'
25 "	..	4	..	7° 20'
20 "	..	5	..	9° 10'
16 "	..	6	..	11°
14 "	..	7	..	12° 50'
12 "	..	8	..	14° 40'
11 "	..	9	..	16° 30'
10 "	..	10	..	18° 20'
9 "	..	11	..	20° 10'
8 "	..	12	..	22°
7·5 "	..	13	..	23° 50'
7 "	..	14	..	25° 40'
6·5 "	..	15	..	27° 30'
6 "	..	16	..	29° 20'
5·5 "	..	18	..	33°
5 "	.	20	..	36° 40'

Although accommodation and convergence are thus intimately linked together, it can easily be proved that they may have a separate and independent action. If we suspend the accommodation with atropine, the convergence is not interfered with, or an object at a certain distance being seen

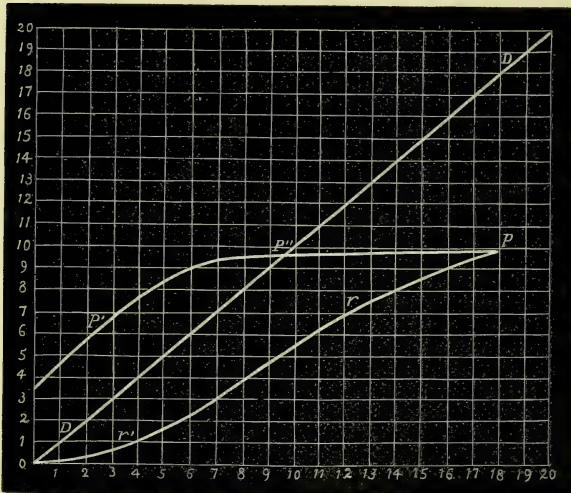
clearly without a glass, can still be seen distinctly with weak concave and convex glasses.

It may, therefore, be stated that although the accommodation and convergence are intimately associated, they may be independent of each other to a certain degree, in order to meet the ordinary requirements; thus the changes which take place during advancing life, when for the same amount of convergence, a greater contraction of the ciliary muscle is necessary to produce the requisite change in the accommodation, owing to diminishing elasticity of the lens.

It is obvious also that the relations between accommodation and convergence must necessarily be very different in ametropia, and this relation will be again referred to when treating the varieties of ametropia in detail.

The following diagram (Fig. 105) shows the relative

FIG. 105.



amount of accommodation for different points of convergence in an emmetrope, aged fifteen. The amount of accommodation in excess of the metrical angle of convergence is called *positive*, and the amount below *negative*.

The diagonal $D D$ represents the convergence from infinity

to 5 cm.; it is also a record of the accommodation. The line $P P' P''$ indicates the maximum accommodation for each point of convergence, and the line $r r'$ the minimum. The numbers on the left and below the diagram are dioptries and metrical angles of convergence; thus, when the visual lines are parallel, it will be seen that 3.5 D. of positive accommodation can be put into play, *i.e.*, the object can still be seen distinctly with a concave glass of that strength; 3.5 D. is therefore the relative amplitude of accommodation for convergence adapted to infinity; or the metrical angle C being 5, which is a distance of 20 cm. away, the accommodation for that point would equal 5 D.; the positive amount that can be put in force while angle C remains the same, would be 3 D., and the negative also 3 D., the object being seen clearly with a concave or convex glass of 3 D., therefore, the relative amplitude of accommodation for C 5 is 6 D. When the angle $C = 10$ or any larger angle, the accommodation that can be put in force will be seen to be entirely on the negative side.

Thus, the convergence being fixed, the amount of accommodation which can be brought into play for that particular point, is the sum of the difference between the strongest concave and convex glass employed.

The eye being accommodated for an object at a certain distance, the amount of convergence for that particular point may be measured by placing in front of the eyes, prisms bases outwards; the strongest with which the object is still seen singly, is the measure of the positive part of the amplitude of convergence. Prisms, bases inwards, give us the negative part—the sum of these is the amplitude of relative convergence.

CHAPTER XIX.

METHODS OF DETERMINING THE REFRACTION.

I NOW propose to enter into the practical part of the subject, by considering the following subjective and objective methods by which the condition of the refraction may be determined.

1. The acuteness of vision.
2. Scheiner's method.
3. The ophthalmoscope.
 - (a) The indirect method.
 - (b) The direct method.
 - (c) Retinoscopy.

In every case that presents itself we must proceed in a systematic manner, and before commencing to take the patient's visual acuteness, something may be gained by noticing the general appearance of the patient, the form of the face, head, &c.; thus, a flat-looking face is sometimes an indication of hypermetropia; a head elongated in its antero-posterior diameter, with a long face and prominent nose, may indicate myopia. If the two sides of the face are not symmetrical, or if there be some lateral displacement of the nose from the median line, astigmatism may be suspected. We should also notice the shape of the eyes themselves, if large and prominent, or small, in the former case we may suspect myopia, in the latter hypermetropia. In high degrees of astigmatism it can often be seen that the curvature of one meridian exceeds that of the other. The distance between the eyes should also be noted, as well as the direction of their axes.

We next listen to the patient's own statement of the troubles from which he suffers; he may say that he sees

distant objects well but has difficulty in reading, especially in the evenings, or that after reading for some time the type becomes indistinct so that he must rest awhile, here we suspect hypermetropia; or he may be able to read and do near work but sees badly at a distance, then we suspect myopia; or both near and distant vision may be defective, in this case our first object must be to decide whether the imperfect vision is due to some error of refraction or to some structural change in the eyes themselves; and we possess an exceedingly simple method by which to differentiate between them, and this method we will call the **Pin-hole** test. A black diaphragm having a small perforation in its centre (the box of trial glasses usually contains such a diaphragm) is placed quite close to the eye under examination, the perforation gives passage to a small pencil of rays which passes through the axis of the refracting system of the eye, so that the image formed is clearly defined for all distances; if then the pin-hole improve vision, the refractive system is at fault, but if, on the contrary, vision is not improved, then we suspect that the transparency of the media or that the retinal sensibility is defective; thus we possess a very simple and reliable plan, which if used systematically may save much loss of time. The points to notice when applying this test are, that the illumination is good, and that the pin-hole is immediately in front of the centre of the pupil. Having then, found out that our patient's refraction is defective, we proceed to our first method, the acuteness of vision.

The Acuteness of Vision.—This must not be confused with the refraction, it is necessary clearly to understand the difference between them. The acuteness of vision is the function of the nervous apparatus of the eye, while the refraction is the function of the dioptric system; so that the acuteness of vision may be normal, even if the refraction be very defective, provided it has been corrected by glasses. The refraction, on the other hand, may be normal even though the eye is unable to see, as in cases of optic atrophy, &c.

We may define the *acuteness of vision* as that degree of sight which an eye possesses after any error of its refraction has been corrected, and the glasses necessary for this correction are therefore a measure of the error of refraction.

In order to find out the acuteness of vision, we have to determine the smallest retinal image, the form of which can

be distinguished ; it has been discovered by experiments that the smallest distance between two points on the retina which can be separately perceived is 0.00436 mm., about twice the diameter of a single cone ; but it is only at the macula and the part immediately around it, which is the most sensitive part of the retina, that the cones are so close together as 0.002 mm. ; in the periphery of the field of vision the two points must be further apart to appear distinct.

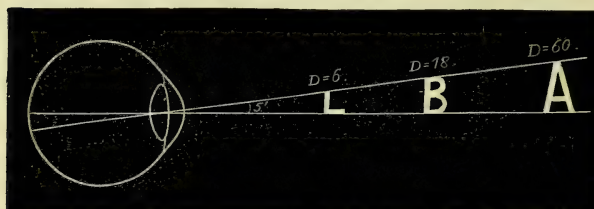
It is probable that rays from two points must fall upon two different cones in order to be visible as two distinct points.

The smallest retinal image which can be perceived at the macula corresponds to a visual angle of $1'$, so that two stars separated by an angular interval of less than $1'$ would produce upon the eye the effect of one star only.

The visual angle has been shown to be an angle included between two lines drawn from the two opposite edges of the object through the nodal point (Fig. 99).

Test-types have been constructed upon these principles for determining the acuteness of vision ; Snellen's being those ordinarily used. Every letter is so made that when at its proper distance each part of it is separated from the other parts by an interval equal to not less than the arc subtending an angle of $1'$ at the nodal point, and the whole letter subtending an angle of $5'$.

FIG. 106.



In order to estimate the refraction by the acuteness of vision, the test object must be placed in a good light, and so far away as to exclude as much as possible the accommodation, 6 metres has been found to be a sufficient distance, and rays coming from an object so far off, may be assumed to be parallel, and falling on an emmetropic eye at rest, would come to a

focus on the retina. The smallest letter which can be seen distinctly at this distance will represent the patient's vision.

Snellen's type consists of rows of letters, each being marked above with the distance in metres at which it should be read. The top letter should be distinct at 60 metres, the next at 36, and each succeeding row at 24, 18, 12, 9, and 6 metres respectively. The patient placed at 6 metres should, without any accommodation, be able to read the bottom line with either eye. This is expressed in the form of a fraction in which the numerator is the distance at which it is read, and the denominator, the number of the line. We note down the result found for each eye separately, if the bottom line is read, $\frac{6}{6}$ expresses it; if the next $\frac{6}{9}$; the top $\frac{6}{60}$, &c.

If our patient, however, be not able even to see the large letter at the top, we allow him to approach the board, telling him to stop as soon as the letter becomes visible. Supposing he stop at 2 metres from the board, we express that as $\frac{2}{60}$, if he is not able to read it at all, we see how far off he can count fingers. If unable to do this, a lower degree of visual acuteness is found out by determining the ability to distinguish the different sorts of light, as to colour, &c. This is called "qualitative perception of light," whereas a still lower degree is to distinguish the difference between light and darkness, this is "quantitative perception of light."

Although the capability of reading the bottom line at 6 metres is the average of acuteness at different ages, yet it is not the maximum, since many young people will be found who are able to read line six at 7 metres, in which case their acuteness is $\frac{7}{6}$.

Savages also often have an acuteness of vision much in excess of the normal.

Thus we have a standard of normal vision, and a convenient method of expressing it in a numerical manner.

We put our patient then, with his back to the light, in front of the test-types, which must hang well illuminated at 6 metres distance, and having armed him with a pair of trial frames, we exclude the left eye from vision, by placing in front of it a ground glass disc, and proceed to test the right eye by asking him, how much of the type he is able to read; if he read the line marked 6, then his vision is $\frac{6}{6}$ or 1, that is to say his distant vision is normal; we may, therefore, assume the absence of *myopia* or *astigmatism*, but he may have *hypermetropia*, and only be able to read $\frac{6}{6}$, by using his accommo-

dition, this we decide, by holding a weak convex glass (+ .5 D.) in front of the eye, when, if he still be able to read the same line $\frac{6}{6}$, he has hypermetropia, and the strongest convex glass with which $\frac{6}{6}$ can be read, is the measure of the *manifest* hypermetropia; supposing + 1 D. the strongest glass with which $\frac{6}{6}$ can be read, then we record it thus: R. V. $\frac{6}{6}$ Hm. 1 D. = $\frac{6}{6}$.

I say manifest hypermetropia, because in all cases occurring in young people, this is not the total hypermetropia; a great part being latent, which can only be discovered by using atropine. Many cases will come before us having two or three dioptries of hypermetropia, who complain that the weakest convex glass impairs distant vision, in these cases the hypermetropia is wholly latent.

We may say, therefore, that a patient who is able to read $\frac{6}{6}$ with one eye must be—

Emmetropic

or

Hypermetropic

in that eye. If hypermetropic, a part of it is usually *manifest*, as found out by the *strongest* convex glass which does not impair distant vision, or it may be wholly *latent*, when it is necessary to atropise the patient before we can demonstrate it.

Supposing, however, our patient's vision is below the normal, and instead of reading $\frac{6}{6}$, he is only able to read, say the third line ($\frac{6}{24}$), and that this is blurred with a weak convex glass, he may have:

Myopia,

Astigmatism,

or

Spasm of accommodation.

We try if a weak concave glass helps him, and if it does so, the case is one of myopia, and we find the *weakest* concave glass with which he sees best; thus we take an example in which the patient is a myope and sees only $\frac{6}{24}$, but with -2 D. $\frac{6}{6}$, we repeat the examination with the second eye, and record it accordingly.

$$\text{R. V. } \frac{6}{24} - 2 \text{ D.} = \frac{6}{6}.$$

$$\text{L. V. } \frac{6}{24} - 2 \text{ D.} = \frac{6}{6}.$$

If our patient is not improved with concave glasses, then

we assume that some astigmatism is present, pre-supposing of course that there is no other cause for bad vision.

To estimate this astigmatism we must call to our aid some of the methods described in the chapter on astigmatism, or we may find out the spherical glass with which he is able to see best, then rotate in front of it a weak convex cylindrical glass; no improvement occurring we do the same with a weak concave cylinder, finding thereby, the glass and its particular axis, which gives the best result. It is necessary that the eye be thoroughly under the influence of atropine, in order to enable us to arrive at definite and reliable results by this method. With practice one is able, in this way, to work out simple cases of astigmatism accurately and quickly.

The object in view is always to bring up the vision of each eye, as nearly to the normal standard of $\frac{6}{6}$ as possible. Frequently, however, we have to be satisfied with $\frac{6}{9}$ or $\frac{6}{12}$.

Should the case appear, however, to be a difficult one, it is better perhaps for the student not to waste time, but proceed at once to retinoscopy.

When trying the patient at the distant type, it is often convenient to have two sets on the opposite sides of the same board, so that it may be reversed when the patient gets too much accustomed to the letters on one side.

The near type is chiefly used to estimate the accommodation, by finding out the far and near point, at which any particular line is read. Snellen and Jaeger's are the types most commonly in use, many preferring Jaeger's, owing to the letters being of the ordinary shapes, but they have the disadvantage, that they are not arranged on any scientific plan, but are simply printer's type of various sizes: the set of reading type at the end of the book is so arranged that when held at the distance for which it is marked, each letter subtends an angle of $5'$ at the nodal point. It must, however, be remembered that sentences are an inferior test to letters, many people recognising the words by their general appearance, whereas they would be unable to see distinctly each letter, of which the sentence was composed.

Having tested our patient's vision at the distant type and recorded the result, we place in his hand the reading type, and note the near and far point at which any particular line can be read.

In cases of myopia we may thus get a valuable hint as to the amount of the defect; we will take for an example a case,

in which the patient could read $\frac{6}{24}$ with the right eye, we give him the near type and if he can read the smallest, only by holding it at a *nearer* point, than the distance for which it is marked, we note the *greatest* distance at which he is able to read it; we will take a case in which the type marked for 1 metre, cannot be read further off than 25 cm., our patient has then most likely myopia of 4 D., because 25 cm. is probably his far point. In this case a glass - 4 D. would give to rays coming from a distant point, the same amount of divergence, as if they came from 25 cm. ($\frac{1.00}{25} = 4$).

We try the patient at the distant type with -4 D.; if he now read $\frac{6}{6}$ the myopia is confirmed, and the weakest glass with which he reads it, is the measure of his myopia.

If the patient read $\frac{6}{6}$, but be unable to read the near type, except it be held at a further distance than that for which it is marked, the case is one of paralysis of the accommodation or presbyopia; and as the latter only commences in emmetropia about the age of forty-five, it will be clear according to the age of the patient to which division the case belongs.

As objects seen through convex glasses appear enlarged, and through concave glasses diminished, it follows that these, when placed before the eye, will exercise some influence on the size of the retinal image. Now the hypermetropic eye sees objects smaller, and the myopic eye larger than the emmetrope, and if glasses which are to correct the ametropia be placed at the anterior focal point, *i.e.* about 13 mm. in front of the cornea, the retinal image of the ametropie, should be of the same size as that of the emmetrope.

Before leaving this subject of the acuteness of vision, the following directions may be given:

1st. The test-type must be in a good light.

2nd. Commence with the right eye, or that which has the best vision, covering up the other with an opaque disc placed in a spectacle frame, and do not be contented to allow the patient to close one eye, as he may not do so completely, or he will probably unconsciously slightly diminish the palpebral aperture of the eye under examination, whereby the circles of diffusion may be somewhat diminished and so give misleading results. Neither should he close the eye with his hand, he may look between the fingers, or exercise some pressure, however slight, on the eyeball, which may interfere temporarily with the function of the retina and so cause delay.

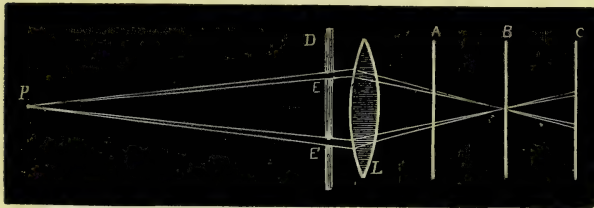
3rd. Having noticed what each eye sees without glasses, always begin the examination with *convex* ones, so as to avoid calling the accommodation into action.

4th. Having noted the result found for each eye separately, we try the two together, the binocular visual acuteness being usually slightly greater than that for one eye.

5th. Test the patient with the reading type, noting the farthest point at which the smallest type can be read.

Scheiner's Method.—Although this plan for detecting ametropia is now but little used, it is necessary the student should understand the principles upon which it is based. A diaphragm having two small perforations is placed in front of the eye we wish to examine; the perforations must be so near together that rays passing through them will enter the pupil (Fig. 107). The patient is directed to look at a small flame 6 metres off; rays emanate from this flame in all directions, some fall on the diaphragm, the greater number are thus cut off, but a few rays pass through the two openings, and if the eye be adapted for the flame, *i.e.*, if it is emmetropic, these two sets of rays will meet exactly on the retina, forming there one image of the flame (B, Fig. 107); if, however,

FIG. 107.*



the eye be hypermetropic (with suspended accommodation) then the two sets of rays will reach the retina before meeting, each set forming an image of the flame (A, Fig. 107). The greater the hypermetropia the further apart will the images be formed; these are projected outwards as crossed images, and the patient sees two images of the flame. That convex glass (from our trial box) which, held behind the diaphragm,

* In the above diagram, P is represented as a near object with rays diverging from it; it should be a distant object with parallel rays.

causes the flame to be seen singly, is a measure of the hypermetropia. If the eye be myopic, then the two sets of rays will have crossed and are diverging when they reach the retina, where two images of the flame are therefore formed (c, Fig. 107). These images are crossed again as they are projected outwards, and having twice crossed, homonymous images are the result. To find the amount of myopia we have only to find the concave glass which, behind the diaphragm, brings the two images into one. To enable us to tell if the images are crossed or homonymous, it is usual to have in front of one of the perforations a piece of coloured glass. We will suppose the diaphragm held so that the two openings are horizontal, that to the patient's right having in front of it a piece of red glass; if only one flame is seen the case is one of emmetropia, if two images of it appear, one white, the other red, with the red to the left of the other, the images are crossed and the case is one of hypermetropia. If the red appears on the right then the case is one of myopia. The further apart the images are, the greater is the ametropia.

CHAPTER XX.


THE OPHTHALMOSCOPE.

The Ophthalmoscope furnishes us with several methods for determining the refraction of the eyes.

- a. The indirect method.
- b. The direct method.
- c. Retinoscopy.

The Indirect Method.—By the indirect method we obtain an inverted image of the disc by means of a biconvex lens placed in front of the eye. In emmetropia (Fig. 107A)

FIG. 107A.



rays coming from A, emerge from the eye parallel, and are focussed by the biconvex lens at *a*, and rays coming from B are focussed at *b*, so also with rays coming from every part of A B, forming an inverted image of A B at *b a*, situated in the air at the principal focus of the biconvex lens.

In hypermetropia (Fig. 108) the rays from A emerge divergent, so also of course those from B; if these rays are continued backwards, they will meet behind the eye (at the punctum remotum) and there form an enlarged, inverted

($a \beta$) of $A B$; it is of this imaginary projected image, that we obtain by the help of the biconvex lens a final inverted image ($b a$), situated in front of the lens beyond its principal focus.

In myopia (Fig. 109) the rays from A and B emerge from the eye convergent, forming an inverted aerial image in front of the eye at βa , its punctum remotum. It is of this image we obtain, with a biconvex lens placed between it and the eye, a final image ($b a$), situated within the focus of the biconvex lens.

With this method we are able to detect the form of

FIG. 108.

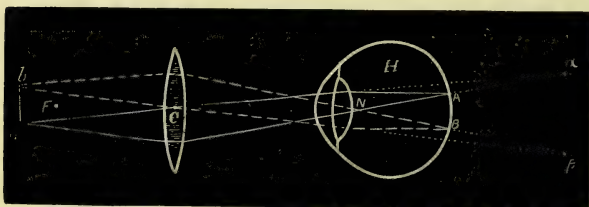
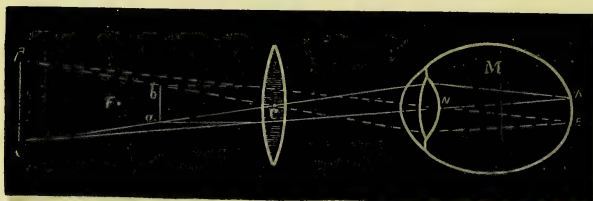


FIG. 109.



ametropia, by the changes which take place in the size and shape of the optic disc, always remembering that the inverted image of the disc, produced by a convex lens at a certain fixed distance from the cornea, is larger in hypermetropia, and smaller in myopia, than in emmetropia. The lens should be held close to the patient's eye, and as it is gradually withdrawn, the aerial image of the disc must be steadily kept in view; the rapidity with which any increase or decrease takes place in the size of this image, gives us an indication of the amount of the refractive error.

If no change takes place in the size of the image on thus

withdrawing the objective, the case is one of emmetropia, because rays issue from such an eye, parallel, and the image formed by the object-glass will always be situated at its principal focus, no matter at what distance the glass is from the observed eye (Fig. 110). As the relative distance of the image and the object from the lens is the same, the size of the image will also be the same.

If diminution take place in the size of the image, the case is one of hypermetropia, and the greater the diminution the higher is the hypermetropia.

This change in size may be explained by remembering that in hypermetropia, the image of the disc is projected backwards (Fig. 114), and it is of this projected image, we obtain a final image with the help of the objective. The two diagrams show images formed by the object glass, when held at 4 cm. and at 12 cm. from the cornea, the latter image being the smaller.

The following explains this :

The ratio of $a \beta$ to $a b$ varies directly as the length $c a$, and inversely as the length $c a$; on withdrawing the lens c from the observed eye, $c a$ diminishes and $c a$ increases; therefore the ratio of $a \beta$ to $a b$ diminishes, *i.e.*, the size of the image diminishes.

If the image becomes larger on withdrawing the object-glass, the case is one of myopia, the greater the increase of the image, the higher the myopia.

This increase in the size of the image can also be explained with the help of mathematics, remembering that in myopia, an inverted image is formed in front of the eye (Fig. 115), and it is of this we obtain an image, with a convex glass placed between the eye and the inverted image, which we must regard as the object; the object and its image being both on the same side of the lens.

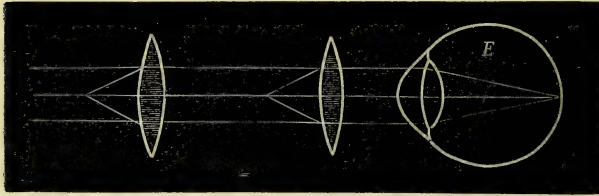
In astigmatism the disc, instead of appearing round, is frequently oval. If one meridian decrease, while the other remain stationary as the objective is withdrawn, it is a case of simple hypermetropic astigmatism. If the whole disc decrease in size, one meridian diminishing more than the other, it is compound hypermetropic astigmatism, the meridian being most hypermetropic which diminishes most.

Increase in one meridian, the other remaining stationary, indicates simple myopic astigmatism.

Increase in disc, but one meridian more so than the other,

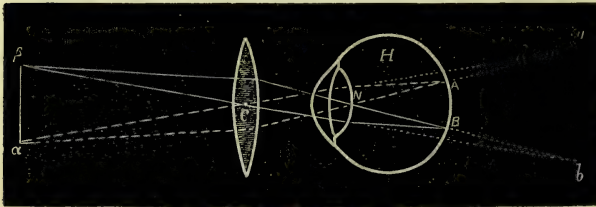
indicates compound myopic astigmatism, that meridian being most myopic which increases most.

FIG. 110.



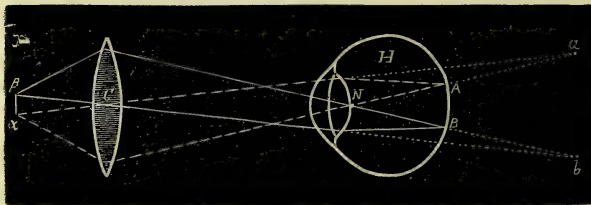
E. Emmetropic eye. Rays issuing parallel, image formed at the principal focus of lens, no matter at what distance the lens is from the eye.

FIG. 111.



Lens at 4 cm.

FIG. 112.



Lens at 12 cm.

11. Hypermetropic eye. c. The centre of the lens. A B. Image on retina. $a\ b$. Projected image. $\beta\ a$. The final image formed by the objective.

If one meridian increase while the other decrease, mixed astigmatism is our diagnosis.

The Direct Method.—By the direct examination we obtain much more important information, not only of a qualitative but also of a quantitative character.

The observer first of all corrects any ametropia that may

FIG. 113.




FIG. 114.

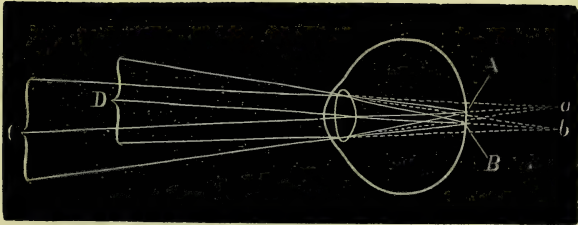



FIG. 115.



exist in his own eye. If he be able to see the disc or some of the vessels, with the mirror alone at a distance from the patient, the case is one of hypermetropia or myopia. The explanation of this is, that in emmetropia (Fig. 113) the rays which come from the two extremities of the disc (A B), emerge as two sets of parallel rays in the same direction as the rays

A C, B D, which having passed through the nodal point, undergo no refraction. These two sets of rays soon diverge, leaving a space between them, so that an observer, unless he be quite close to the observed eye, is unable to bring these rays to a focus on his retina; and, therefore, at a distance from the eye the observer sees only a diffused and blurred image.

In hypermetropia (Fig. 114), the rays from the two points A B, emerge from the eye in two sets of diverging rays, in the same direction as the rays A C, B D, which undergo no refraction. These diverging rays have the appearance of coming from two points (*a*, *b*) behind the eye, where an erect imaginary image is formed (*a b*).

The more the rays diverge on exit, the sooner they will meet when prolonged backwards; and hence, the greater the hypermetropia, the nearer will the image be to the nodal point.

The observer at a distance sees a clear, erect image which is formed behind the eye.

In myopia (Fig. 115), the rays from the two points (A B) emerge as two converging sets of rays, which meet at *a b* on their secondary axes, thus forming an inverted image in front of the eye. This image can be distinctly seen by the observer, if he be at a sufficient distance from the point, and accommodating for the particular spot at which the aerial image is formed, and the higher the myopia the nearer to the eye will this image be formed.

If the observer now move his head from side to side, and the vessels of the disc are seen to move in the same direction, the case would be one of hypermetropia, the image formed being an erect one.

Had the vessels moved in the opposite direction to the observer's head, the case would be one of myopia, the image being an inverted one formed in the air in front of the eye.

If the vessels of one meridian only are visible, then we have a case of astigmatism, hypermetropic if moving in the same, and myopic if moving in the opposite direction to the observer's head, that meridian being ametropic which is at right angles to the vessels seen.

In mixed astigmatism the vessels of one meridian move against the observer's movements, and those of the other meridian with them; this is difficult to see.

Thus we have obtained an indication of the form of ametropia. We may, however, estimate the amount of error, by means of a refracting ophthalmoscope, of which there are many.

In endeavouring thus to estimate the refraction, it is essential that the accommodation of both the patient and observer be suspended. The observer places both himself and the lamp on the same side as the eye he is about to examine, then with the mirror close to the patient's eye, so that the ophthalmoscope may occupy as nearly as possible the position of the spectacle glass, he looks for the disc. We really wish to estimate the refraction at the macula, but to this there are several obstacles; the light falling on this, the most sensitive part of the retina, has a very dazzling, unpleasant effect for the patient, and causes the pupil to contract vigorously, the reflex from the cornea and the lens is exactly in the line of vision, and further, there are no convenient vessels in this part which we may fix as test objects, whereas the disc is but little sensible to light, and the vessels of this part, as well as the margins of the disc itself, are very convenient for our purpose; and although occasionally the refraction of the macula and disc are not exactly the same, still, practically it is sufficiently accurate to take that of the latter. Having relaxed the patient's accommodation by making the examination in a dark room, and directing him to look with the eye, not under examination, into space, or, what is better, having paralysed it by atropine, then, if the observer's own accommodation be suspended, and the image of the disc appear quite clear and distinct, the case is one of emmetropia. This we know, because rays coming from an emmetropic eye (Fig. 116, E) in a state of repose, issue parallel according to the law of conjugate foci, and the observing eye receiving these rays will, if emmetropic with its accommodation suspended (which often requires great practice), be adapted for parallel rays, so that a clear image of a in the observed eye, will be formed at b on the retina of the observing eye.

Supposing the image does not appear clear and distinct without an effort of accommodation, then we turn the wheel of the ophthalmoscope so as to bring forward convex glasses in front of the observing eye. The *strongest* positive glass with which we are able to get a perfectly clear image, is a measure of the hypermetropia, because rays coming from a

(Fig. 117) in the hypermetropic eye (H) issue in a divergent direction as though coming from R, the punctum remotum behind the eye. The convex lens (L) renders them parallel and they then focus at *b*, on the retina of the observing emmetropic eye (E).

In practice many observers find it difficult or impossible to tell if their own accommodation be completely relaxed, so

FIG. 116.

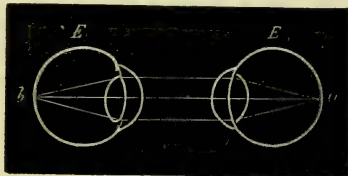


FIG. 117.

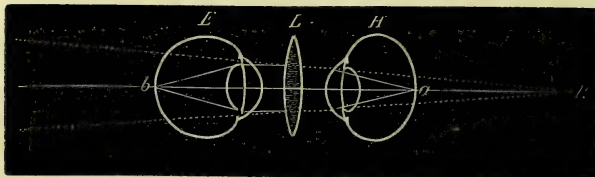
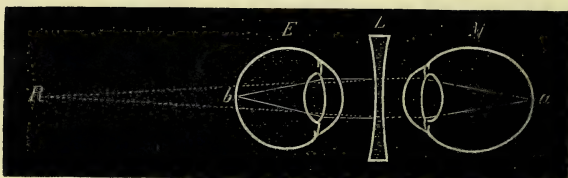


FIG. 118.



that if they see clearly the disc of the patient under examination, they do not at once assume that he is emmetropic, but only do so on finding that the weakest convex glass behind the ophthalmoscope impairs the clearness of the image.

If, however, the image of the disc appear indistinct, and the convex glass, instead of rendering the image clearer, have

the opposite effect, we must turn the wheel of the ophthalmoscope in the other direction, and so bring forward the concave glasses. The *weakest* glass with which we can see the details of the fundus clearly is a measure of the myopia, because any stronger glass merely brings into play the accommodation of the observer. Rays from *a* (Fig. 118) leave the myopic eye (M) so convergent, that they would meet at (R) the punctum remotum. The concave lens (L) renders them parallel before falling on the relaxed eye (E) of the observer.

If the ophthalmoscope is not held very close to the eye, we must deduct from the focal distance of the lens the distance between the cornea and the instrument in hypermetropia, adding them together in myopia.

If astigmatism exist, the plan is to find the glass which enables the vertical vessels and lateral sides of the disc to be seen distinctly, and then the glass with which the vessels at right angles are best seen.

Suppose the vertical vessels and lateral sides of the disc appear distinct without any glass, then the horizontal meridian, *i.e.* the meridian at right angles to the vessels clearly seen, is emmetropic; and suppose, also, that the horizontal vessels with the upper and lower borders of the discs, require a convex or concave glass to render them clear and distinct, then the vertical meridian is hypermetropic or myopic, and the case is one of simple hypermetropic or myopic astigmatism.

If both the vertical and horizontal vessels require convex glasses, but a stronger one for the horizontal than for the vertical, then the case is one of compound hypermetropic astigmatism, the vertical meridian being the more hypermetropic.

If both meridians had required concave glasses, but of different strengths, then the case would be one of compound myopic astigmatism.

If the vertical vessels and the lateral sides of the disc require a convex glass to render them distinct, while the horizontal vessels require a concave glass, the case is one of mixed astigmatism, the horizontal meridian being hypermetropic, the vertical meridian myopic.

The essential point to remember is that the glass with which the vessels in one direction are seen, is a measure of the refraction of the meridian at right angles to them.

The estimation of the refraction by the direct ophthalmoscopic method is exceedingly valuable, but requires great practice. In cases of hypermetropia and low myopia, one is able to estimate the amount of error within half a dioptré, and in cases of astigmatism where the chief meridians are horizontal and vertical, one can come very near the exact correction, and without subjecting the patient to the inconvenience of having his accommodation paralysed with atropine, which in many cases is of great advantage; some observers are able to find out the exact meridians, even when oblique, and estimate correctly the most difficult cases of regular astigmatism; in such I must say that I have found this method of examination give less satisfactory results than retinoscopy, and I never venture to order glasses for astigmatism on the result of my direct ophthalmoscopic examination without confirming the result by some other method, but I am aware that some ophthalmic surgeons do so. No doubt the direct ophthalmoscopic examination requires much greater practice than any other method of examination; probably many observers can never relax their accommodation so completely as to give satisfactory results. It is also an additional advantage that one can estimate the refraction at the same time that one makes an examination of the fundus.

The comparison of the direct and indirect methods of examination is also very useful in astigmatism. If, for instance, the disc is elongated horizontally in the erect, and oval vertically in the inverted image, we know that the curvature of the cornea is greater in the horizontal than in the vertical meridian.


The ametropic observer must always remember, when using the direct method, for the estimation of errors of refraction, that he must correct his own defect, either by wearing spectacles or by having a suitable glass in a clip behind his ophthalmoscope; he is then in the position of an emmetrope: but, if he prefer it, he may subtract the amount of his own hypermetropia or myopia from the glass with which he sees clearly the patient's discs. Thus, if the observer have 2 D. of hypermetropia and require +3 D. to see the fundus clearly ($3 \text{ D.} - 2 \text{ D.} = 1 \text{ D.}$), the patient would have 1 D. of hypermetropia; had he required -2 D. then ($-2 \text{ D.} + (-2 \text{ D.}) = -4 \text{ D.}$) the observed would have 4 D. of myopia.

The same with the myopic observer, if his myopia amount

to 3 D., then he will require -3 D. to see clearly the emmetropic fundus; if he sees well without a glass, then the eye under examination has 3 D. of hypermetropia; if he require a $+2$ D., then the hypermetropia will be 5 D., and so on.


Ametropia may also be easily recognised in the following manner: the fundus being illuminated by a mirror about 1 metre from the patient, if the eye be emmetropic the rays of light will return parallel to one another, and a red reflex can only be obtained when the observing eye is in the path of these rays, that is, behind the perforation of the mirror. If hypermetropic the returning rays will diverge (Fig. 119),

FIG. 119.



and the observer will notice as he moves his eye (B) from behind the mirror at L (and at right angles to the visual axis of the patient who should fix on the centre of this mirror), that the last ray of light ($a' b'$) is seen, or in other words, the red reflex disappears, on the same side of the pupil as that to which the observer moves his head. If myopic, the rays will converge, cross, and diverge (Fig. 120);

FIG. 120.



when the error is 1 D. or more, the last ray of light is seen, or the red reflex disappears on the opposite side of the pupil. A single trial of this will prove its correctness.

The endeavour to estimate the amount of myopia or

hypermetropia by measuring the distance between the perforation of the mirror, and the point at which the last ray was seen, has been unsuccessful, owing to the varying size of the pupil.

The ophthalmometer of Javal and Schiötz and Tweedy's optometer, can, I think, be more conveniently considered when treating of astigmatism.

CHAPTER XXI.

RETINOSCOPY.

RETINOSCOPY or the shadow test is deservedly one of the most popular methods of estimating refraction here, though in some countries it is less used than the direct method.

The chief advantage is that it is entirely objective, and is therefore very useful in the cases of young children, in those that are amblyopic, and in malingerers: besides the method is very easily learnt and quickly carried out, saving much time in difficult cases of astigmatism.

If light be reflected into the eye by means of a concave mirror, at a distance of a metre or so, an observer looking through the sight hole of the mirror will notice the ordinary red fundus reflex; on slightly rotating the mirror the illuminated area of the pupil may disappear (or, what may be more easily seen, the edge of the shadow bounding this illuminated area may appear), on the same side as the rotation or in the opposite direction, according to the refraction of the eye under observation; thus, if the mirror be rotated to the right and the edge of the shadow move across the pupil also to the right, *i.e.*, in the same direction as the rotation of the mirror, the case is one of myopia, whereas if the shadow had moved in the opposite direction to the mirror, the case would be one of hypermetropia.

This method of employing retinoscopy is so simple that a few practical trials will suffice to make it understood, although, of course, as in all other manipulations, some little practice is required in giving to the mirror the necessary movements, and enabling one to appreciate what is seen.

Atropine is not absolutely essential; still, when we have

to examine young people and children, its use is most certainly advisable. In the first place, the consequent dilatation of the pupil renders our examination so much easier; and secondly, atropine helps us to a more definite conclusion by thoroughly paralyzing the accommodation; for although the examination takes place in a dark room, and with the patient looking into distance, it must be remembered that there is often (especially in the case of children) some accommodation, due to the normal tone of the ciliary muscle, or to a condition of spasm common in hypermetropia and myopia—it also enables us easily to detect small degrees of astigmatism which frequently exist, and but for this method, would probably escape notice.

Another great advantage of atropine is that it allows the refraction at the macula to be measured, whereas when the pupil is not dilated we have to be satisfied with the refraction at the optic discs, which may occasionally vary considerably from that found at the macula; and the estimation of the refraction at the macula constitutes one of the chief advantages that retinoscopy possesses over the measurement obtained by the direct method.

To examine the patient then, we dilate his pupils, and seat him in a dark room, with a lamp placed over his head, so far back that it throws no direct rays upon his face, and consequently requires no moving during the examination of either eye. Then the observer takes up a position about 120 cm. in front of the patient, and directing him to look at the perforation in the mirror, which should be a concave one and of 25 cm. focus, he will be enabled to reflect the light along the visual axis, and thus obtain the ordinary red fundus reflex.

If atropine has not been used, this procedure will cause the pupil so to contract, that it will be difficult to see the shadows, and in that case the observer must make the patient look a little inwards, so that the light may be reflected along the optic axis. If we now rotate the mirror slightly from side to side on its vertical axis, we see a shadow come out from behind the pupil, moving horizontally across the illuminated part. The edge of this shadow may be linear or somewhat crescentic; its direction may vary, being either vertical, or oblique if astigmatism exist. The shadow moves either in the same or the opposite direction


to the mirror, so that when the latter is tilted to the right, the shadow may come from the left, or *vice versa*.

Thus, assuming the shadow's edge to be vertical, if it move with the mirror, the case is one of myopia; but if it move against or in the opposite direction to the mirror, it is either one of hypermetropia, emmetropia, or low myopia.

What is this shadow whose edge we see? How and where is it formed? and what influences its movements and clearness.

To enable us to answer these questions we will place before a screen a convex lens, at such a distance from it that converging rays from a concave mirror, having crossed and become divergent, are brought to an exact focus, and there is then formed a very small, erect, well-defined image

FIG. 121.



- a.* The concave mirror. *b.* The candle. *c.* The lens. *e.* The screen.
d. Small image of candle formed on screen. *f.* Dense shadow around.

on the screen of the lamp, from which the concave mirror received its rays; erect, because it has suffered two inversions.


This image of the lamp is surrounded by a sharply defined and dense shadow.

If we move the lens nearer to, or farther from, the screen, the area of light becomes larger, and the illumination feebler, owing to the circles of diffusion on the screen.

The mirror being rotated on its vertical axis, the image of the candle, with the surrounding shadow, will always be found to move in the opposite direction to the mirror, whatever be the distance of the lens from the screen.


This is exactly what takes place in the eye, of which our screen and lens are a representation.

FIG. 122.



At *e* a small image of the candle is formed ; at *d*, and *f*, circles of diffusion.

FIG. 123.




M. The mirror. *M'*. The mirror after rotation. The extremities of the dotted line have moved in the opposite direction to the rotation of the mirror.

It may therefore be stated, that the illumination and shadows which we see, are an enlarged image of the lamp with the surrounding shadow, brought more or less to a focus on the retina according to the refraction of the eye. They always move against the mirror, but as these movements are seen through the transparent media of the eye, and thereby undergo refraction, the "apparent" may differ from the "real" movements. The image we see of the lamp, and its surrounding shadows, are formed in the same manner as all other images ; and it may here be well to repeat what has already been said with regard to the formation of these images.

In emmetropia the image is formed at infinity, thus the rays which come from the two extremities A, B, emerge as two sets of parallel rays, in the same direction as the rays A C, B D; which, having passed through the nodal point, undergo no refraction. These two sets of rays soon diverge,

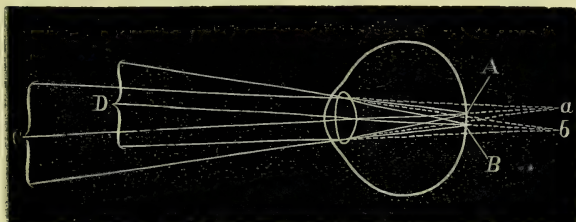
FIG. 124.



leaving a space between them, so that an observer, unless he be quite close to the observed eye, is unable to bring these rays to a focus on his retina; and, therefore at a distance from the eye the observer sees only a diffused and blurred image.

In hypermetropia the image is formed behind the eye, thus, the rays from the two points, A, B, emerge from the eye in two sets of diverging rays, in the same direction as

FIG. 125.



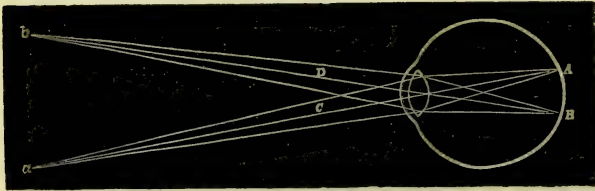
the rays A C, B D, which undergo no refraction. These diverging rays have the appearance of coming from two points, *a*, *b*, behind the eye, where an erect image is formed, *a b*.

The more the rays diverge on exit, the sooner they will meet when prolonged backwards; and hence, the greater the hypermetropia, the nearer will the image be to the nodal point.

The observer, at a distance, sees a clear, erect image, which is formed behind the eye.

In myopia an inverted image is formed in the air in front of the eye, thus, the rays from the two points, A, B, emerge

FIG. 126.



as two converging sets of rays, which meet at *a*, *b*, on their secondary axis, thus forming an inverted image in front of the eye. This image can be distinctly seen by the observer, if he be at a sufficient distance from the point, and accommodating for the particular spot at which the aerial image is formed.

We have already seen that the real movements of the shadows on the retina are against the mirror.

In hypermetropia the final image of the candle and its surrounding shadow, produced by the concave mirror, is an erect one formed behind the eye, and as it is viewed through the dioptric system of the eye, it therefore moves against the mirror.

In myopia the final image is an inverted one, projected forwards. This, therefore, moves with the mirror, it having undergone one more inversion.

To this rule, that in myopia the image moves with the mirror, there are two exceptions:

1st. If the observer be nearer the patient than his far point, but not within the focal distance of the mirror, the image will move against the mirror. This is frequently the case in low degrees of myopia, where the patient's far point is beyond 120 cm.

2nd. If the observer be within the focal distance of the mirror, although beyond the far point of the patient, the image will in this case also move against the mirror. This latter source of error can always be avoided by using a


concave mirror of 25 cm. focus, and keeping 120 cm. from the patient.

Therefore, if the image move with the mirror, the case is certainly one of myopia. If it move against the mirror, it is most likely one of hypermetropia; but it may be emmetropia, or a low degree of myopia.

The movements tell us the form of ametropia we have to deal with. The extent of the movements on rotation of the mirror, the clearness of the image and the brightness of its edge, enable us to judge approximately the amount of ametropia to be corrected; some practice, however, is required before we can form an opinion with anything like accuracy.

The extent and rate of movement is always in inverse proportion to the ametropia; the greater the error of refraction,

FIG. 127.



the less the movement, and the slower does it take place. This may be explained in the following way:

Suppose A to be the image of a luminous point formed on the retina, and that a line be drawn from A through the nodal point B to C. Now, if the case be one of myopia (Fig. 127), an inverted projected image of A is formed somewhere on this line, say at c. The higher the myopia, the nearer to the nodal point will this image be; and hence we may suppose it formed as near as D. If the mirror be now rotated, so that it takes up the position of the dotted line M', C will have moved to c, and D to d; whence it is clear, that c has made a greater movement than D.

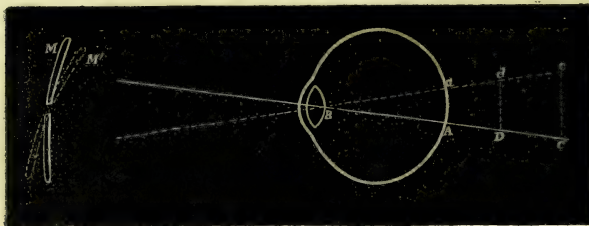
Had the case been one of hypermetropia (Fig. 128), the image would have been projected backwards, and as in myopia, the higher the degree of hypermetropia, the nearer to the nodal point is the image formed.

In this case, the line from the nodal point *B* to *A* is prolonged backwards, and the image of the luminous point in a low degree of hypermetropia is formed, say at *c*, and in a higher degree, say at *D*. On moving the mirror into the position of the dotted line *M'*; *c* moves to *c* and *D* to *d*; whence it is clear that *c* has made a greater movement than *D*.

Therefore, as the ametropia increases, the extent of the movement of the image decreases. The clearness of the image and the brightness of its edge decrease, as the ametropia increases.

It is shown in Fig. 121, that on placing before a screen a convex lens at such a distance that converging rays from a concave mirror, having crossed and become divergent, are brought to an exact focus, forming a small, erect, well-defined image on the screen of the lamp from which the concave

FIG. 128.



mirror received its rays. On moving the lens nearer to or farther from the screen, the larger becomes the area of light, and the feebler the illumination, owing to the circles of diffusion formed on the screen.

Therefore, in the case of the eye, the greater the ametropia, the larger is the circle of diffusion and the weaker the illumination, so that the image we see is less bright and its edge less distinct.

It is, therefore, in the lower degrees of ametropia that we get the brightest and best-defined shadows; and, when we thus see them, we may assume that we are approaching the stage of correction.

Having thus answered the questions concerning the shadows which we see in retinoscopy, we are in a position to pursue further the practical working of the subject, with

special reference to the correction of any existing error of refraction by glasses.

The patient, then, being seated in the dark room, the pupils dilated, and the lamp over his head, as before described, we take up our position 120 cm. in front, with a concave mirror of 25 cm. focus (a Galezowski mirror is the one commonly used, and is found convenient). The patient is then directed to look at the centre of the mirror, so that the light from the lamp may be reflected along the visual axis. On looking through the perforation of the mirror, we get the ordinary fundus reflex, bright if the patient be emmetropic, less so if he be ametropic, and the greater the ametropia, the less bright will the fundus reflex be. We now rotate the mirror on its vertical axis to the right. If a vertical shadow come across the pupil from the patient's right, *i.e.*, in the same direction as the movement of the mirror, or what is the same thing, if the shadow move in the same direction as the circle of light on the patient's face, the case is one of myopia. Should the edge of the image appear well defined and move quickly, in addition to a bright fundus reflex, we infer that the myopia is of low degree and proceed to correct it.

Each eye must of course be tried separately.

The patient having put on a pair of trial spectacle-frames, we place a weak concave glass, say -1 D., before the eye we are about to correct. If the image still move with the mirror, we place in the frame -1.5 D., then -2 D., and so on, until we find the point at which no distinct shadow can be seen. Supposing this to be -2 D., and that on trying -2.5 D. the image move against the mirror, -2 D. is assumed to be the correcting-glass. This, however, will be found not to be the full correction of the myopia, because, being situated at 120 cm. from the patient, when his far point approaches that distance, we are unable to distinguish the movements of the shadow; and when the far point of the observed, though not situated at infinity, is still at a greater distance than the observer, we get a shadow moving in the opposite direction. Hence it is customary in cases of myopia to add on $-.5$ D. to the correcting-glass, and this would give us -2.5 D. as the proper glass for our case.

In correcting myopia, it is a convenient and reliable plan to stop at the weakest concave glass which makes the image move against the mirror, and put that down as the correcting-glass.

When the myopia is of high degree and a strong concave glass has to be used for its correction, the light reflected from the mirror is so spread out by the concave glass, that fewer rays pass into the eye, and therefore the illumination is not so good as in other states of refraction.

Had we obtained a reverse shadow, we should then try convex glasses, when, if $+5$ D. neutralised, we should assume the case to have been one of low myopia. Had it required $+1$ D., then it would be one of emmetropia; above this hypermetropia. We proceed exactly as before, putting up stronger and stronger glasses, until we are unable to make out the movements of the image. This is assumed to be the correcting-glass, and, just as in the above case the myopia was under-corrected, so in this the hypermetropia is slightly over-corrected; and hence it is usual to deduct from this glass $+1$ D., or we may stop at the strongest convex glass with which we still get a reverse shadow.

To sum up, therefore, if the shadow move with the mirror, it is a case of "myopia;" if against, it may be weak myopia if $+5$ D. cause the image to move with the mirror; emmetropia if $+1$ D. neutralised it; hypermetropia if a stronger glass is required.

The points to be observed, are—(1) the direction of the movement of the image, as indicating the kind of ametropia; (2) the rate and amount of movement; (3) the brightness of the edge of the image; (4) and the amount of fundus reflex, all indicate the degree of ametropia.

We have taken notice only of the horizontal axis, but any other meridian will, of course, do equally well, if the case be one of hypermetropia or myopia simply. If, however, the case be one of astigmatism then the axes are different.

In astigmatism, the flame of the candle on the retina, instead of being, as in emmetropia, a small, well-defined image, or as in myopia or hypermetropia, a circle of diffusion, is distorted so as to be more or less of an oval form, according to the position of the retina and the maximum and minimum curvatures of the cornea.

In the normal eye, the focus of the vertical meridian of the cornea, is slightly shorter than that of the horizontal. So long as no impairment of vision occurs, the eye is said to be normal. When, however, the acuteness of vision is diminished, then astigmatism is said to exist.

Parallel rays, passing through a convex spherical lens, disregarding some slight irregularities due to aberration, form a cone, any section of which, perpendicular to its axis, will be a circle. The size of the circle depends upon the distance of the point at which the lens is from its focus. If beyond the focus the cone be divided, as in myopia, the rays having crossed and become divergent, a circle of diffusion is formed on the retina. In hypermetropia the cone is divided before having come to a focus, and thus forms a diffusion circle. But in astigmatism the divided cone is circular only at one point, No. 4 in Figs. 141 and 142. To explain this, we place in front of the convex spherical glass, a weak convex cylindrical glass, with its axis horizontal. The result of this is, that parallel rays passing through this combination do not form a circular cone, because the rays which pass through the vertical meridian come to a focus before those passing through the horizontal, as shown in Fig. 141.

The ray being divided at 1, an oblate oval is formed; at 2 a horizontal straight line, the vertical rays having come to a focus; at 3, 4, 5 the vertical rays have crossed and are diverging, and the horizontal rays are approaching; at 4 a circle is formed; at 6, a vertical straight line, the horizontal rays having met and the vertical still diverging; a large prolate ellipse is formed at 7.

So that in astigmatism, the image on the retina is more or less of an oval, instead of being either a small, well-defined image of the candle, or a circle of diffusion, according to whether the eye be emmetropic, myopic, or hypermetropic. This oval may have its edges horizontal and vertical, frequently, however, they are more or less oblique.


The oblique movements of the shadow, are independent of the direction in which the mirror is rotated.

This obliquity is produced thus: (Fig. 129) if behind a circular opening, which is to represent the pupil, we place obliquely an oval piece of card, which is to represent the image on the retina, so that that part of its edge, which occupies with regard to the circular opening an oblique position; on moving the card across in the direction $o d$, it has the appearance of moving in the direction, $c o$, at right angles to the edge of the card. Hence the direction of the shadow's movement is deceiving, and its oblique edge is due to the fact that only that edge which coincides in direction with one of the principal meridians is seen well defined by

the observer. Therefore the apparent movements are always at right angles to the edge of the shadow.

The same takes place in astigmatism, the two chief meridians of which, are parallel and perpendicular to the

FIG. 129 (*Charnley.*)



shadows. In retinoscopy, therefore, when the edge of the image is oblique, we know at once that the case is one of astigmatism. If, however, it should be horizontal or vertical, we judge if one shadow be more distinct or quicker in its movements than the other, though we are not always able to say at once, that astigmatism exists. We therefore proceed to correct one meridian. If the shadow move against in all meridians, we first take the vertical, and put up in front of the patient, in a spectacle-frame, convex spherical glasses, until we find the *strongest* with which the shadow still moves against the mirror. We put this down as the correcting-glass for this meridian, and let us suppose that glass to be + 2 D. We next take notice of the horizontal meridian, and if + 2 D. is also the highest glass with which we still get a reverse shadow, then of course we know the case is one of simple hypermetropia. But supposing the highest convex glass had been + 4 D., we indicate it conveniently thus :

$$\begin{array}{c} + 2 \text{ D.} \\ - \\ + 4 \text{ D.} \end{array}$$

The case is one of compound hypermetropic astigmatism, and should require for its correction + 2 D. spherical combined with + 2 D. cylinder axis vertical.

We will take another case—that in which the vertical meridian requires - 2 D. to give a reverse shadow, and the horizontal + 2 D., this being the highest glass with which

we still obtain a reverse shadow. Here we have a case of mixed astigmatism which can be corrected in either of the three following ways :

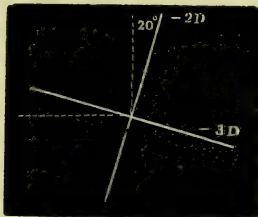
1st. -2 D. cylinder axis horizontal combined with $+2$ D. cylinder axis vertical; this is a plan seldom used, and is not so easy to work with as a sphere and a cylinder.

2nd. -2 D. sphere combined with $+4$ D. cylinder axis vertical, or

3rd. $+2$ D. sphere combined with -4 D. cylinder axis horizontal. This last is perhaps the preferable plan. Opticians like working $-$ cylinders on to $+$ spheres, rather than $+$ cylinders upon $-$ spheres.

Supposing the axis of the shadow to be oblique, we know at once that astigmatism exists, and we proceed to correct each meridian separately, moving the mirror at right angles

FIG. 130.



to the edge of the shadow, not horizontally and vertically. We judge of the amount of obliquity by the eye, and can frequently tell within a few degrees. If the vertical meridian be 20° out, and require for its correction -2 D., and the axis at right angles to this (which will be therefore at 110°) require -3 D. we express it as Fig. 130, and correct it with sphere -2 D. combined with cylinder -1 D. axis 20° , the case being one of compound myopic astigmatism.

Often one is able to put up the cylinder in the spectacle-frame with the exact degree of obliquity.

Having found the glasses which correct the two meridians, we put up the combination in a spectacle trial frame, and if we now get only a slightly reversed shadow in every direction, the glasses are assumed to be the right ones, and we proceed to confirm it by trying the patient at the distant type, making any slight alterations that may be necessary.

I cannot too strongly recommend the use of atropine in solution, gr. iv to $\bar{3}j$, frequently dropped into the eyes for three days prior to the examination, so as thoroughly to relax the accommodation. It can be used without fear, and without a great amount of inconvenience in most young people, under twenty years of age. I have worked out a great many cases of astigmatism, and feel more and more the necessity of using this drug to enable one to arrive at exact results. I might almost say, that I have never seen a young person whose astigmatism has been worked out without atropine wearing the right correction; and the inconvenience entailed upon the patient for two weeks by its use, is not to be compared to the trouble and asthenopia from which he or she is so liable to suffer, if the glasses worn are not the proper ones.

In old persons with small pupils, in whom it is difficult to see the movements of the shadow, and in whom solutions of atropine of the ordinary strength are dangerous, on account of the occasional occurrence of that much dreaded disease "glaucoma," which has been clearly traceable to its use, I have often found it convenient to dilate the pupil with homatropine in solution, gr. ij to $\bar{3}j$ of water, or with an exceedingly weak solution of atropine $\frac{1}{40}$ gr. to $\bar{3}j$ of water.

I will now briefly describe two modifications of retinoscopy which have been suggested and carried out.

First, Mr. Story has proposed the use of a plane mirror, in the place of the concave one already described; it certainly possesses several advantages and is preferred by many surgeons.

With this mirror the movements of the shadow are in the same direction as those of the disc and bloodvessels, as seen by the direct ophthalmoscope at a distance from the eye viz., in the same direction as the observer's movements in hypermetropia, and in the opposite direction in myopia.

No additions or subtractions have to be made to the glass found by this method.

The disadvantage is the distance at which the observer must work, viz. 4.5 metres from his patient.

The second modification of retinoscopy has been proposed by Dr. Jackson, of Philadelphia, who uses a plane mirror, and thus describes the practical application of this modification in the various states of refraction.

“*Simple myopia.*—Rays of light from any given point of the retina emerge from the myopic eye convergent, and meet at the point in front of the eye, for which the eye is optically adjusted. The accommodation being in abeyance, this will be the far point of distinct vision. So that there is formed at the far point of the myopic eye an inverted image of the retina. If now the eye of the observer be placed between the patient’s eye and its far point, there will be seen an erect image of the patient’s retina; but if the observer view the patient’s eye from somewhere beyond its far point, he will see, not an erect image, but the inverted image formed at that far point. In the first case, the boundary of light and shade which marks the border of the retinal area will appear to move with the facial area; in the second case, against it. In practice, the surgeon begins the examination somewhat more distant from the patient than the far point of the eye under examination. Then he slowly approaches the patient, all the while watching the apparent movement of the retinal area produced by slightly rotating the mirror from side to side about its axis. As long as this apparent movement is opposed to that of the facial area, the surgeon knows he is watching the inverted image at the patient’s far point. Presently, however, the direction of the movement of the retinal area cannot be distinguished, the far point has now been reached; and coming still closer the apparent movement again becomes distinct, but is seen to correspond in direction with the real movement, the far point has now been passed, and the patient’s retina is being viewed in the erect image. By noting the point at which this reversal occurs, the surgeon notes the far point of the eye under observation; by measuring the distance from this point of reversal to the eye, he measures the distance from the patient to his far point of distinct vision; and the reciprocal of this distance, of course, expresses the degree of his myopia. Thus, supposing the point of reversal to be one-fourth of a metre in front of the eye, one divided by one-fourth equals four, the number of dioptries of myopia present.

“Theoretically, the method as now described is complete, but for convenience and accuracy in its application, one or two other points must be attended to. When the observer’s eye has come quite close to the patient’s, say to within one-eighth of a metre, and the inverted image is still seen

between them, it is best to place a concave lens (-8 D.) before the patient's eye, and then to estimate the amount of myopia remaining uncorrected; and by adding it to the amount which the lens used has corrected, determining the total myopia present. When the observer has approached so near the inverted image that it lies closer to his eye than his near point of distinct vision, he can no longer see that image distinctly. Still he can distinguish in which direction the retinal area appears to move, until he approaches somewhat nearer to the image, when the circles of diffusion upon his own retina become so large that the retinal area of light, seen in the patient's pupil, seems very diffuse and faint, and the direction of its apparent movement uncertain. Because of this, there is great practical difficulty in determining exactly where the point of reversal is situated. Now it is evident that if the point of reversal is within a few inches of the eye, an error of two or three inches as to its position entails an error of some dioptries in the amount of myopia present. Therefore, when by the method above described the degree of myopia has been approximately ascertained, place before the patient's eye a concave lens strong enough to remove the point of reversal a metre or more from the eye. At such a distance, an error of two or three inches as to the position of the point of reversal is of no consequence; and an accurate determination of the remaining, and hence of the total myopia, can readily be made. Having determined the amount of myopia present, the surgeon will of course be guided by the rules he would follow had the myopia been measured by any other method.

Hypermetropia.—On viewing the fundus reflex it is found that at all distances the erect image is seen and the retinal area appears to move with the facial area. Place before the patient's eye a convex lens strong enough to over-correct the hypermetropia. Then, by the method given above, determine the degree of myopia so produced. Deduct this amount of myopia from the strength of the convex lens used; and the remainder will express the degree of hypermetropia present. Suppose, for example, the hypermetropia amounts to four dioptries. Placing a five dioptry convex lens before the eye, it is found that one dioptry of myopia is produced, the point of reversal being at one metre. Then five, minus one, equals four, which expresses in dioptries the amount of hypermetropia present. Should it be found that

the + 5 D. lens leaves the eye hypermetropic so that the erect image is seen at all distances, replace it by a + 10 D., and proceed as before. As in myopia, however, the final accurate determination should be made at a distance of not less than one metre. It may be noticed that low degrees of myopia may be measured without the use of any lens, but that to determine the degree of hypermetropia present, a convex lens is always necessary.

"*Emmetropia* is determined by the method for measuring hypermetropia. The convex lens being placed before the eye, the resulting myopia is found to equal exactly the strength of the lens in use.

"*Regular Astigmatism*.—In applying the test to the measurement of regular astigmatism, instead of rotating the mirror about any axis, vertical, horizontal, or oblique, as may be done when the curvature of the cornea is the same in all directions, it is rotated about axes perpendicular to the directions of the principal meridians of curvature, and the point of reversal thus found for each principal meridian. To determine the direction of these principal meridians, the eye, if not previously so, should be rendered myopic in all meridians, and then viewed from different distances. It will then be found that at certain points the fundus reflex takes the shape of a more or less distinct band of light stretching across the pupil, while on one or both sides of it may be seen a shaded area 'the somewhat linear shadow' of Bowman. This band of light is very readily moved in a direction perpendicular to its length, but in the direction of its length cannot be made to move at all. The point where this appearance is presented is the point of reversal for that principal meridian of the cornea, whose direction coincides with the length of the band. The other principal meridian is, of course, at right angles to this; and the observer by placing his eye at its point of reversal will be in position to see a similar band extending in a direction perpendicular to that of the band first observed. This use of the shadow-test may be made clearer by the consideration of what occurs in a particular case. Suppose the patient's cornea to have such a curvature as to cause in the horizontal meridian (axis vertical) a hypermetropia of four dioptries, and in the vertical meridian (axis horizontal) a myopia of one dioptre. Place before the eye a + 5 D. spherical lens. On approaching it from a distance, it is found that the retinal area moves

against the facial area in all directions. But as the distance of one metre is approached, it is noticed that the retinal area takes the form of a horizontal band, readily movable upward or downward, but difficult to move to the right or left; and when the point of one metre is reached, all movement to the right or left ceases, and the band is more distinct. Going still closer, the point of reversal for the horizontal meridian being passed, movement to the right or left reappears, but it is now with the facial area. The movement upward or downward is still against that of the facial area. As the patient is still approached, the appearance of a horizontal band fades out, and presently is replaced by that of a vertical band. The vertical band moves readily to the right or left, but less distinctly upward or downward, and at one-sixth of a metre all vertical motion is lost. This is the point of reversal for the vertical meridian. On approaching still closer, vertical movement reappears, but like the horizontal movement it is now with the facial area, not against it. Thus it is found that for the horizontal meridian the point of reversal is one metre distant from the eye, and that for the vertical meridian the point of reversal is one-sixth metre distant. That is, the use of the convex lens has made the eye myopic in the one meridian one dioptré, in the other meridian six dioptrés; and by taking into account the effect of the spherical lens used, the mixed astigmatism is seen to be what we supposed it. But for accurate work, as in simple myopia and hypermetropia, the degree of ametropia for each meridian should be finally determined with such a lens before the eye as would place the point of reversal, for that meridian, one metre or more distant."

A few cases from my note-book will do more than any description to make the subject of retinoscopy clear.

CASE 1. *Spasm of Ciliary Muscle*.—Boy, aged 11 years.

$$\text{R.V. } \frac{6}{12} - 1 \text{ D.} = \frac{6}{6}.$$

$$\text{L.V. } \frac{6}{12} - 1 \text{ D.} = \frac{6}{6}.$$

Bright fundus reflex, shadow moves with the mirror, but with $- .5 \text{ D.}$ a reverse shadow is seen. The case, therefore, looks like one of weak myopia. Ordered guttæ atropiæ gr. iv to ʒj, three times a day; on the third day, with retinoscopy, $+ 1 \text{ D.}$ still gives an opposite shadow. On trying the patient at the distant type with $+ 1 \text{ D.}$ both eyes read $\frac{6}{6}$ well. This, therefore, was a case of hypermetropia simulating weak myopia, due to ciliary spasm: such cases are not rare.

CASE 2. *Hypermetropia*.—Girl, aged 13, suffering from “tinea tarsi.”

$$\text{R.V. } \frac{6}{8} \text{ Hm. } 1 \text{ D.} = \frac{6}{8}.$$

$$\text{L.V. } \frac{6}{8} \text{ Hm. } 1 \text{ D.} = \frac{6}{8}.$$

Guttæ atrop., gr. iv to ʒj. Fundus reflex, moderate; a reverse shadow is seen moving somewhat slowly. On trying + 2 D. shadows become much more distinct and the movements quicker; + 4 D. is found to be the strongest glass with which we still get a reverse shadow. With + 4 D. $\frac{6}{8}$ was read, but with no stronger glass, this therefore is the measure of the patient's total hypermetropia.

CASE 3. *Hypermetropic Astigmatism*.—Young man, aged 20.

$$\text{R.V. } \frac{6}{24} \text{ Hm. } 4 \text{ D.} = \frac{6}{9}.$$

$$\text{L.V. } \frac{6}{24} \text{ Hm. } 4 \text{ D.} = \frac{6}{12}.$$

Under atropine; right eye at distant type sees only $\frac{6}{60}$. Fundus reflex very dull, movements of shadow slow and against the mirror. On putting up + 5 D. the reflex is much brighter, the edge of shadow distinct and its movements quicker. We try + 6, 7, 8, 9, and the last gives a shadow moving with the mirror. + 8 D. is the highest which still leaves the shadow moving against. On trying the eye at the distant type $\frac{6}{9}$ and 4 letters of $\frac{6}{9}$ are once read. No alteration in the glass improves sight.

Left eye. Fundus reflex, and movements as in right. We commence by trying + 8 D. which we found the other eye required. In the vertical meridian the movement is against the mirror, while + 9 D. causes it to move with it. In the horizontal meridian with + 8 D. the shadow moves with the mirror, and + 7 D. causes it to move against. We express it thus—

$$\begin{array}{c} | + 8 \text{ D.} \\ - | + 7 \text{ D.} \end{array}$$

and on trying the combination at the distant type,

$$+ 7 \text{ D. sp.}$$

$$+ 1 \text{ D. cylinder axis horizontal.}$$

the patient is able to read $\frac{6}{9}$; and on decreasing the sphere from 7 D. to 6.5 D., $\frac{6}{9}$ is read, so that the proper correction for this eye is,

$$+ 6.5 \text{ D. sp.}$$

$$+ 1 \text{ D. cy. axis horizontal;}$$

in this case, therefore, hypermetropia was present in one eye, compound hypermetropic astigmatism in the other.

CASE 4. *Astigmatism*.—Young woman, aged 17, sees with either eye $\frac{6}{24} - 1 \text{ D.} = \frac{6}{18}$. Retinoscopy without atropine—

$$\begin{array}{l} \text{R.} \begin{array}{|l} -3.5 \text{ D.} \\ -1 \text{ D.} \end{array} \end{array} \quad \begin{array}{l} \text{L.} \begin{array}{|l} \text{---} \\ \text{---} \\ \text{---} \end{array} \end{array} \begin{array}{l} \text{---} \\ \text{---} \\ \text{---} \end{array} \begin{array}{l} -2 \text{ D.} \\ +1 \text{ D.} \end{array}$$

In this case the glasses were again tried after atropine was recovered from, and the following glasses ordered, which were of course to be worn constantly:

$$\begin{array}{l} \text{R. } +1 \text{ D. sp.} \\ \quad -6 \text{ D. cy. axis } 175^\circ. \end{array} \qquad \begin{array}{l} \text{L. } +1.5 \text{ D. sp.} \\ \quad -5.5 \text{ D. cy. axis } 170^\circ. \end{array}$$

CASE 6. *Mixed Astigmatism*.—Mr. C.—, aged 24, has noticed that for the past few years, the eyes become very tired at night, especially when much writing or reading has been done, he thinks he sees distant objects less clearly than formerly.

R. V. $\frac{6}{24}$ not improved with convex or concave glasses; with pin-hole test $\frac{6}{12}$.

L. V. $\frac{6}{18}$ not improved with convex or concave glasses; with pin-hole test $\frac{6}{12}$.

After using atropine for four days, retinoscopy gave the following results:

$$\begin{array}{l} \text{R. } \left| \begin{array}{l} +3 \text{ D.} \\ -+ .5 \text{ D.} \end{array} \right. \end{array} \qquad \begin{array}{l} \text{L. } \left| \begin{array}{l} +2.5 \text{ D.} \\ -+ .5 \text{ D.} \end{array} \right. \\ \\ \text{R. } \frac{+.5 \text{ D. sp.}}{+2.5 \text{ D. cy. axis } 160^\circ} = \frac{6}{6}. \qquad \text{L. } \frac{+.5 \text{ D. sp.}}{+1.5 \text{ D. cy. axis } 165^\circ} = \frac{6}{5}. \end{array}$$

We direct the patient to return after the effects of the atropine have passed off, which he does in ten days; we then try our correction, deducting + 1 D. sphere for the atropine.

$$\begin{array}{l} \text{R. } \frac{-.5 \text{ D. sp.}}{+2.5 \text{ D. cy. axis } 160^\circ} = \frac{6}{6}. \qquad \text{L. } \frac{-.5 \text{ D. sp.}}{+1.5 \text{ D. cy. axis } 165^\circ} = \frac{6}{5}. \end{array}$$

This correction was accordingly ordered to be worn constantly.

CASE 7. *Astigmatism*.—Sarah K.—, aged 21, complains that her eyes have of late been very painful, and she has also suffered much from headaches, which have sometimes ended with an attack of sickness.

$$\text{R. V. } \frac{6}{18} - 1 \text{ D.} = \frac{6}{12}. \qquad \text{L. V. } \frac{6}{24} - 2 \text{ D.} = \frac{6}{12}.$$

After atropine. Retinoscopy gave

$$\begin{array}{l} \text{R. } \left| \begin{array}{l} -1.25 \text{ D.} \\ -+ 1 \text{ D.} \end{array} \right. \qquad \text{L. } \begin{array}{l} \text{X} \\ \vdots \\ + 1 \text{ D.} \\ -3.5 \text{ D.} \end{array} \\ \\ \text{R. } \frac{+1 \text{ D. sp.}}{-2.25 \text{ D. cy. axis horiz.}} = \frac{6}{6}. \qquad \text{L. } \frac{+1 \text{ D. sp.}}{-4 \text{ D. cy. axis } 125^\circ} = \frac{6}{6}. \end{array}$$

After the effects of atropine had passed off the correction which gave the best results was—

$$\text{R. } -2.25 \text{ D. cy. axis horiz.} = \frac{6}{6}. \qquad \text{L. } \frac{+.25 \text{ D. sp.}}{-4 \text{ D. cy. axis } 125^\circ} = \frac{6}{6}.$$

These spectacles were ordered to be worn constantly.

CASE 8. *Simple Hypermetropic Astigmatism*.—Jane Q—, aged 11, has always seen near things badly, she turns her head to one side, instead of looking directly at the object.

R.V. $\frac{6}{24}$ not improved with spheres, with pin-hole $\frac{6}{18}$.

L.V. $\frac{6}{24}$ not improved with spheres, with pin-hole $\frac{6}{18}$.

Retinoscopy after atropine gives

$$\text{R.} \left| \begin{array}{l} +1 \text{ D.} \\ \hline +5 \text{ D.} \end{array} \right. \qquad \text{L.} \left| \begin{array}{l} +.75 \text{ D.} \\ \hline +4 \text{ D.} \end{array} \right.$$

$$\text{R.} \frac{+1 \text{ D. sp.}}{+4 \text{ D. cy. axis vert.}} = \frac{6}{12}. \qquad \text{L.} \frac{+.75 \text{ D. sp.}}{+3.5 \text{ D. cy. axis vert.}} = \frac{6}{12}.$$

After the atropine had passed off.

$$\text{R.} +4 \text{ D. cy. axis vert.} = \frac{6}{12}. \qquad \text{L.} +3.5 \text{ D. cy. axis vert.} = \frac{6}{12}.$$

Spectacles of this strength were ordered for constant use.

CASE 9. *Myopic Astigmatism*.—Jane P—, aged 23, has always seen rather badly, and has had a good deal of pain and discomfort in the eyes for the past six months, especially when using them by gas-light; about a week ago noticed that on closing the left eye, the vision of right was almost gone; though she admitted never having tried them separately before; occasionally the right eye turns outwards.

$$\text{R.V.} \frac{1}{60} -4 \text{ D.} = \frac{6}{60}.$$

$$\text{L.V.} \frac{6}{24} -1 \text{ D.} = \frac{6}{18}.$$

Homatropine was applied once and at the end of half an hour retinoscopy gave

$$\text{R.} \left| \begin{array}{l} -5.5 \text{ D.} \\ \hline -3 \text{ D.} \end{array} \right. \qquad \text{L.} \left| \begin{array}{l} -1 \text{ D.} \\ \hline -\text{Em.} \end{array} \right.$$

With glasses:

$$\text{R.V.} \frac{-3 \text{ D. sp.}}{-2.5 \text{ D. cy. axis } 175^\circ} = \frac{6}{12}.$$

$$\text{L.V.} -1 \text{ D. cy. axis } 5^\circ = \frac{6}{6}.$$

This correction was ordered for constant use.

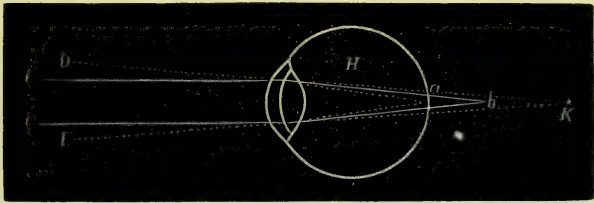
In most cases thus worked out, the glasses may be ordered at once, without waiting for the effects of the atropine to pass off, in fact experience teaches that it is a good plan to continue the atropine until the spectacles have been made; remembering only that in hypermetropia and hypermetropic astigmatism the spherical glass will require slightly diminishing, usually about 1 D.: in myopia and myopic astigmatism the spherical glass has to be slightly increased.

CHAPTER XXII.

HYPERMETROPIA.

HYPERMETROPIA (H) ('Υπέρ, in excess; μέτρον, measure; and ὤψ, the eye) may be defined as a condition in which the antero-posterior axis of the eyeball is so short, or the refracting power so low, that parallel rays are brought to a focus behind the retina (the accommodation being at rest). In other words, the focal length of the refracting media is greater than the length of the eyeball.

FIG. 131.



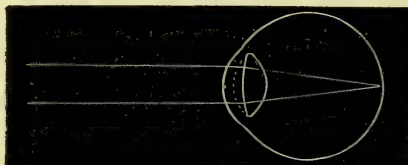
Parallel rays focus at b behind the retina; those coming from the retina emerge as divergent rays, D, E.

In the passive hypermetropic eye, therefore, parallel rays c and g come to a focus behind the eye at b , forming on the retina at a , a circle of diffusion instead of a point. Rays coming from the retina of such an eye, emerge having a divergent direction (D and E); these, if prolonged backwards will meet at a point (κ) which is the punctum remotum, and being situated behind the eye it is called *negative*.

The distance of the punctum remotum behind the eye will equal the focus of the convex lens which corrects the

hypermetropia; thus, supposing it is situated 20 cm. behind the retina ($\frac{100}{20} = 5$), 5 D, will be the convex glass which will render parallel rays so convergent that they will focus on the retina, or cause rays from the retina to be parallel after passing through it; allowance must be made for the distance between the cornea and the convex lens.

FIG. 132.




Parallel rays focussed on retina by accommodation. The dotted line shows the lens more convex as a result of the contraction of the ciliary muscle.

The hypermetropic eye at rest, is only able to bring *convergent* rays to a focus on the retina. All rays in nature are divergent, some so slightly so, that when coming from a distant object, they are assumed to be parallel. Rays can be made convergent by passing them through a convex lens placed in front of the eye, or the refraction of the dioptric system may be increased by the accommodation, so that parallel rays may focus on the retina of an hypermetropic eye.

Therefore a hypermetrope with relaxed accommodation, sees all objects indistinctly. So that such a person having to use some of his accommodation for distance, starts with a deficit for all other requirements, equal to the amount of hypermetropia.

FIG. 133.



Parallel rays rendered so convergent by passing through a convex lens that they focus on the retina.

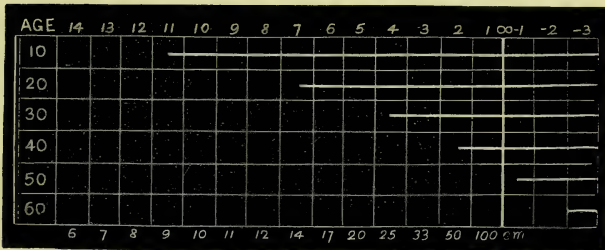
Thus, supposing an individual, hypermetropic to the extent of four dioptries, and possessing 6 D. of accommodation, he will by the exercise of this power to the extent of 4 D., be able to bring parallel rays to a focus on the retina, and so see distant objects clearly ; this leaves him 2 D. of accommodation for near objects, which will bring his near point to 50 cm., a distance at which he will be unable to do near work.

Besides, it must be remembered, than only a part of the accommodation can be used for sustained vision, fatigue soon resulting when the whole of the accommodation is put in force.

The following diagram is intended to show by the number of spaces, each representing a dioptre, through which the thick lines are drawn, the amount of accommodation in a hypermetrope of 3 D., at different ages as given on the left of the diagram. The figures above, indicate the number of dioptries, and those below, the near point for each increasing dioptre of accommodation.

FIG. 134.

Dioptries.



The amount of hypermetropia is calculated and expressed, by that convex glass which makes parallel rays so convergent, that they meet on the rods and cones of the retina, the accommodation being suspended.

The commonest amount of error is about 2 D. Small degrees may require some trouble to discover, and can only possibly be found out after the eye has been atropized.

Hypermetropia is divided into *latent* and *manifest*. The

manifest, Donders subdivides into *absolute*, *relative*, and *facultative* :

Absolute, when by the strongest convergence of the visual lines accommodation for parallel rays is not attained, in other words, when distant vision is impaired; this variety is seldom met with in young people.

Relative, when it is possible to accommodate for a near point by converging to a point still nearer, in fact by squinting.

Facultative, when objects can be clearly seen with or without convex glasses.

In youth the hypermetropia may be facultative, becoming in middle age relative, and in old age absolute.

Causes of Hypermetropia :

1. The antero-posterior diameter of the eyeball is too short (axial hypermetropia). This is by far the most common cause and is congenital.
2. A flattened condition of the cornea, the result of disease or occurring congenitally.
3. Absence of the lens (aphakia).
4. Detachment or protrusion of the retina, owing to a tumour or exudation behind it.
5. A diminution in the index of refraction of the aqueous or lens.

Hypermetropia, therefore, is usually due to shortening of the axis of the eyeball.

The following table shows the amount of shortening for each dioptré of hypermetropia, the axial line in emmetropia being estimated at 22·824 mm.

For ·5 of D. of H. there is a diminution in the axial line of ·16 mm.

1·D.	”	”	”	·31	”
1·5	”	”	”	·47	”
2·	”	”	”	·62	”
2·5	”	”	”	·77	”
3·D.	”	”	”	·92	”
3·5	”	”	”	1·06	”
4·	”	”	”	1·21	”
4·5	”	”	”	1·35	”
5·	”	”	”	1·5	”
6·	”	”	”	1·76	”
7·	”	”	”	2·03	”
8·	”	”	”	2·28	”
9·	”	”	”	2·53	”
10·	”	”	”	2·78	”

Hypermetropia is by far the most frequent condition of the refraction, it may be looked upon as a congenital defect, frequently also it is hereditary, several members of the same family suffering from it.

Hypermetropia is usually due to an arrest of development, which varies from the slightest degree to the extreme condition known as "microphthalmos."

The following are some of the chief points in which the hypermetropic differs from the emmetropic eye: the eye looks small, being less than the normal in all its dimensions, especially the antero-posterior, the sclerotic is flat and makes a strong curve backwards in the region of the equator, which can easily be seen on extreme convergence, or can be felt by the finger. The lens and iris are more forward, the anterior chamber is shallow and the pupil small; the centre of motion of the eye is relatively further back, while the angle α , which is formed between the visual and optic axis is invariably greater, averaging about 7° (see p. 405). The result of the large angle α , in hypermetropia, is that the eyes often have an appearance of divergence, which has often been mistaken for real divergence, whereas in myopia, the small angle causes the eyes to look as if they converged.

The ciliary muscle, upon the action of which the accommodation depends, is much larger than in emmetropia, the anterior portion, which consists chiefly of circular fibres, being especially developed, no doubt hypertrophied by the constant state of contraction in which it is kept. This contraction is called into action by the instinctive desire for clear images which all eyes possess, the accommodation having to be used for distant, as well as for near objects. Another result of the constant and excessive accommodation, is that the convergent power, with which it is so intimately linked, is kept in a state of constant tension, so that in many children *convergent strabismus* is gradually produced. To fully understand how this convergent strabismus becomes developed, I must refer the reader to the chapter on that subject.

When the hypermetropia is of high degree the optic nerve is smaller and contains fewer fibres, so that the visual acuteness is frequently below the normal.

Sometimes the face also has a characteristic appearance, being flat looking, with depressed nose, shallow orbits, and the eyes set far apart. Frequently, however, there is no distinctive physiognomy.

The hypermetropic eye is very liable to asymmetry, as will be shown when speaking of astigmatism.

Symptoms of Hypermetropia.—The patient usually sees well at a distance, but has difficulty in maintaining clear vision for near objects: and since the hypermetropia can be more or less corrected by accommodation, if the error be of a low degree (as 2 or 3 D.), no ill-effects may for some time be noticed; at length, however, a point is reached, when the accommodation is not equal to reading and near work, and accommodative asthenopia is the result (Chapter 26). This is especially liable to show itself after an illness, or if the patient's health has deteriorated from over-work, anxiety, or other causes. He then complains that after working or reading for some time, especially during the evenings, the type becomes indistinct, and the letters run together: after resting awhile the work can be resumed, to be again shortly laid aside from a repetition of the dimness: the eyes ache, feel weak, water, &c., frequently headache supervenes; there is a feeling of weight about the eyelids and a difficulty of opening them in the morning. When the hypermetropia is of high degree, the patient may be said by his friends to be shortsighted, because when reading, he holds the book close to his eyes; by doing this he increases the size of his visual angle, and thus gets larger retinal images; this is counter-balanced by increase in the circles of diffusion, but as the pupils also contract by approaching the book to his eyes, some of these are cut off; so that the advantage is in favour of holding the book close, especially as the patient is probably not accustomed to clear, well-defined images. In some cases the ciliary muscle contracts in excess of the hypermetropia, so that parallel rays focus in front of the retina, and the patient therefore presents many of the symptoms of myopia: we should always be on our guard against such cases. The manner in which the patient reads the distant type is often a guide to us in hypermetropia, he takes a considerable time to make out each line, and yet if not hurried, eventually reads the whole correctly. On looking at the eyes one notices that they are red and weak, the lids look irritable, and on eversion the conjunctiva is hyperæmic, especially that of the lower lids, the papillæ being frequently enlarged, and the edges of the lids sometimes affected with sycosis. All these symptoms are probably the commencement of troubles, which, if allowed to go on, may develop into granular lids,

derangements of the lachrymal apparatus, &c., this much we can see; how much more injurious must be the changes which are liable to take place in the interior of the eyeball from prolonged hyperæmia! It cannot be too forcibly insisted on, that in all ophthalmic cases, except those of an acute character, the refraction should be taken and recorded as a matter of routine, since complaints which prove very intractable, are often easily and quickly cured when the proper glasses have been prescribed.

As the patient advances in age he becomes prematurely presbyopic, so that at thirty-five he may suffer from the same discomforts as an emmetrope of fifty.

To **test** the hypermetropia and measure the amount, we take the patient's visual acuteness, each eye separately, and having found that they are alike in their refraction, we try the two together; stronger glasses being often borne when both eyes are used, than when one is excluded from vision.

The *strongest* convex glass with which he is able to read $\frac{6}{6}$, or with which he gets the greatest acuteness of vision, is the measure of the *manifest* hypermetropia (Hm.). This is not, however, the total hypermetropia, for if the accommodation be paralysed, by applying a solution of atropiæ sulph., gr. iv to $\bar{3}j$, three times a day for four days (when we may feel sure that not the least vestige of accommodation remains), a much stronger glass can be tolerated, and will be required to enable the patient to read $\frac{6}{6}$. This strong glass represents the total hypermetropia, the additional amount to that found as Hm. being called *latent* (Hl.).

The following plan is an excellent one for measuring the manifest hypermetropia. Place in spectacle-frames before the eyes such convex glasses as over correct the Hm. (+4 D. will usually do this); then hold in front of these, weak concave glasses, until we find the *weakest*, which thus held in front of +4 D. enables $\frac{6}{6}$ to be read; the difference between the glasses is then the measure of the Hm. By this plan the ciliary muscle is encouraged to relax, and we get out a larger amount of manifest hypermetropia than is obtained by the ordinary method. Thus, supposing -2 D. the weakest glass which held in front of the convex 4 D., enables the patient to read $\frac{6}{6}$, +2 D. is the measure of the Hm. (+4 D. -2 D. = +2 D.).

As age advances the accommodation diminishes, and the

latent hypermetropia becomes gradually manifest. Thus, a person may have 6 D. of hypermetropia latent at ten years of age, 3 of which may have become manifest at thirty-five, and the whole of it at about sixty-five or seventy, when the total hypermetropia is represented by the manifest.

With the advance of age certain changes take place in the structure of the crystalline lens, by which its refraction becomes diminished; this change takes place in all eyes, and at a regular rate; thus at fifty-five the refraction has diminished .25 D., at sixty-five .75 D., at sixty-eight 1 D., and at eighty as much as 2.5 D. Hypermetropia when thus occurring in eyes previously emmetropic is styled *acquired hypermetropia*, in contradistinction to the congenital form, which is called *original hypermetropia*.

The normal refraction of the eye in early childhood is hypermetropic; some remain so, a considerable number become emmetropic as they get older, and a certain percentage of these pass on to myopia.

In the diagnosis and estimation of hypermetropia several methods are useful. We first estimate the *acuteness of vision*, remembering that being able to read $\frac{6}{6}$ does not exclude hypermetropia, and that we must in all cases try convex glasses, and if the same letters can be seen with, as without them, then the patient certainly has hypermetropia, and the *strongest* convex glass with which he sees them is the measure of his Hm.; we next proceed to *retinoscopy*, with this method we get a reverse shadow, the quicker the movement and the brighter its edge, the lower is the degree of hypermetropia (see p. 490).

With the ophthalmoscope by the *indirect method* of examination, the image of the disc is larger than in emmetropia and diminishes on withdrawing the objective from the eye (p. 471).

By the *direct* examination at a distance, an erect image of the disc is seen, which moves in the same direction as the observer's head (p. 474). On approaching the eye, the accommodation of the observer and observed being relaxed, a convex glass is necessary behind the ophthalmoscope, to enable the observer to bring the diverging rays from the observed, to a focus on his retina; the *strongest convex* glass with which it is possible to see the details of the fundus clearly, is the measure of the total hypermetropia (Fig. 117).

The **treatment of hypermetropia** consists obviously, in prescribing such convex glasses as will give to rays passing through them an amount of convergence, so that they will meet on the retina without undue accommodation. It might be thought that having obtained the measure of the *total* hypermetropia, nothing remained but to give such positive glasses as exactly neutralize the defect, and that we should then have placed the eye in the condition of an emmetropic one. Such at first was thought to be the case, though it is by no means so, because persons who have been accustomed to use their accommodation so constantly, both for near and distant objects, as is the case with hypermetropes, have very large ciliary muscles which they cannot suddenly completely relax; possibly also the elasticity of the lens capsule is somewhat impaired.

In children and patients under twenty years of age it is much better to atropize them at the first, and so measure once and for all, the amount of total hypermetropia; otherwise it will frequently be found that the spectacles have to be constantly changed, the asthenopia is unrelieved, and probably the patient has to be atropized after all, or becomes dissatisfied and goes off to someone else. Another reason in favour of atropine is, that with it we cannot possibly mistake cases of spasm of the ciliary muscle in hypermetropia for myopia, which might otherwise happen, since the spasm causes the lens to become so convex that parallel rays are even made to focus in front of the retina, thus simulating myopia.

It must always be borne in mind, that it is dangerous to atropize patients above the age of thirty-five, many well-marked cases of "glaucoma" having been traced to the use of this drug; moreover, as age advances the latent hypermetropia gradually becomes manifest, so that the necessity for paralysing the accommodation becomes less.

There exists some difference of opinion among ophthalmic surgeons, as to the amount of the total hypermetropia we ought to correct; some give such glasses as neutralise the *manifest* hypermetropia only, while others, after estimating the total, deduct perhaps 1 D. from this. It will be found that patients vary much as the amount of correction which is most comfortable for them.

A good practical rule is to prescribe such glasses for

reading as correct the *manifest* and one-fourth of the *latent* hypermetropia.

For example, a child having 6 D. of hypermetropia of which 2 only are manifest, will require +3 D. for reading. At the age of twenty, about 4 D. will have become manifest, and the patient will then want +4.5 D.; at forty, 5 D. will be manifest, and he may then be able to bear full correction.

Hence it will be seen that, as age advances, the spectacles will have occasionally to be changed for stronger ones, as the latent hypermetropia gradually becomes manifest.

The question arises, should spectacles be worn constantly or only for near work? So long as distant objects ($\frac{6}{6}$) can be seen comfortably without them, their use is unnecessary except for reading and near work; this is generally the case in young persons where the hypermetropia does not exceed 3 or 4 D. When a convex glass improves distant vision, then such can be constantly worn; somewhat stronger ones may be required for reading, &c.; this is usually the case with old people.

The disadvantage of using spectacles constantly is, that after wearing them for some time, the patient finds he is unable to see without them, which is a serious inconvenience, so that the plan is, not to give spectacles for constant use, until the hypermetropia has become relative or absolute.

In cases of concomitant squint, spectacles which correct the hypermetropia are to be worn constantly, and here our object must be to give as near the full correction as is consistent with the patient's comfort; this we can only find out by experiment in each case; the best plan is to measure, under atropine, the total hypermetropia, deduct 1 D., and give this correction for constant use: the reason for making this deduction is that the ciliary muscle is never so completely relaxed as when under atropine.

Asthenopia and convergent strabismus, two of the most frequent results of hypermetropia, are treated of in Chapters 16 and 26.

See Cases 1 and 2, p. 498; also 10, 12 and 17, Chapter 27.

APHAKIA.

APHAKIA ('A, priv., φακός, lens) is the name given by Donders to that condition of the eye in which the lens is absent. There are several causes, by far the most frequent being one of the various operations for cataract, extractions, needle operations, &c. Besides these, aphakia may be caused by dislocation of the lens from injury, or dislocation may occur spontaneously, and this is probably the cause of those congenital cases where no lens can be seen.

Aphakia necessarily converts the eye into a very hypermetropic one. The length of the eyeball which would be required (the curvature of the cornea being normal and the lens absent) to bring parallel rays to a focus on the retina is 30 mm., whereas normally the antero-posterior diameter of the eyeball is only about 23 mm.

To test aphakia; when a bright flame is held in front of and a little to one side of a normal eye, three images of the flame are formed, one erect on the cornea, another erect on the anterior surface of the lens, and a third inverted, and formed on the posterior surface of the lens. On moving the flame up and down, the erect images move with it, and the inverted one in the opposite direction. In aphakia two of these images are absent, viz., those formed on the two surfaces of the lens.

Treatment.—Strong convex glasses will be required to take the place of the absent lens, the previous refraction of the eye of course influencing their strength. If hypermetropic, stronger glasses will be required; if myopic, weaker.

The glass usually required by an eye previously emmetropic, to bring parallel rays to a focus on the retina, is from 10 to 13 D.

As every trace of accommodation is lost with the lens, stronger glasses will be required for reading or near work, and to find out the necessary glass for a certain distance, we have only to add to the distance glass, one, whose focal length equals the distance at which we wish our patient to see. Thus, if he require + 10 D. for distance, and wish to see to read at 25 cm., we add + 4 D. to his other glass, and the resulting + 14 D. will bring up his vision to 25 cm.

The patient may be taught a sort of artificial accommodation by moving the spectacles along his nose, nearer or

farther from the eyes, his working point being thereby moved away or brought nearer to him.

In correcting aphakia it will often be found that the vision is below the normal. Frequently also there is some astigmatism, especially in cases after cataract extraction.

See Case 23, Chapter 26.

CHAPTER XXIII.

MYOPIA (M).

MYOPIA (*Mύω*, I close ; *ὄψ*, the eye) or short sight, is the opposite condition to hypermetropia.

We saw that the hypermetropic eyeball was too short, so that parallel rays focussed behind the retina, it is therefore not adapted to any real distance, because in order to see any object clearly, it is necessary that the defect should be corrected either by its accommodation or by means of a convex glass ; now in myopia, although the eyeball is too long to allow of distant objects being seen clearly, it is perfectly adapted for near vision, so that a low degree of myopia may not be a very serious disadvantage.

We spoke of hypermetropia as congenital, due to an arrest of development ; myopia is an acquired defect, and may be looked upon as an effort of nature to adapt the eye to near objects, as a result of civilization and its incessant demands on near vision.

Myopia is peculiar to the human race and is met with much more frequently in civilized than in uncivilized races.

Low degrees such as 1 D. may have no very serious drawbacks, because although the full visual acuteness can only be obtained by the help of concave glasses, many people go half through life, playing cricket, tennis, shooting, &c., without finding out the defect, their near vision is really better than that of the emmetrope, for they obtain larger retinal images, and they have to accommodate less ; against these advantages it may be stated that many myopes suffer from asthenopia, the result of disturbance of the harmony between the two functions, accommodation and convergence, though this disturbance will be more marked in the higher degrees of ametropia.

Medium degrees of myopia, from 2 to 6 D., are exceedingly common, the visual defects are more pronounced, it becomes necessary to use glasses for many things; often they have to be worn constantly. Such patients are liable to suffer from asthenopia or from divergent strabismus and its accompanying evil—loss of binocular vision.

The higher degrees of myopia which increase steadily and constantly from an early age, reaching often a very high degree, and carrying in its wake destruction and damage to important ocular tissues, must be looked upon as a serious

FIG. 135.





FIG. 136.



disease; it is designated by the name *malignant* or *progressive* myopia.

We must now refer to the optical condition of the myopic eye.

Parallel rays, falling on a myopic eye, focus in front of the retina, cross and form circles of diffusion (Fig. 135), in place of a clear image.

Only divergent rays focus on the retina, and hence it is necessary, that the object looked at be brought so near, that rays coming from it are sufficiently divergent (Fig. 136), or

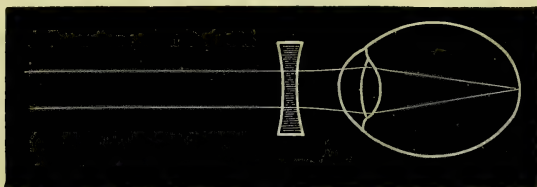
they must be rendered so by passing through a concave lens (Fig. 137).

We may say then, that in myopia the retina is at the conjugate focus of an object, situated at a finite distance. The accommodation being at rest, an object situated at this point will be distinctly seen, further off it will be indistinct, nearer, it can still be seen clearly by putting in force the accommodation.

The greatest distance at which objects can be seen clearly, is called the far point (punctum remotum) and is always at a definite distance. The higher the myopia the nearer to the eye is its punctum remotum (p. r.).

The nearest point of distinct vision is the punctum proximum (p. p.) and is determined by the amount of the accommodation. To find out the punctum proximum, we place in the patient's hand the near type, and note the shortest

FIG. 137.



distance for each eye separately at which the smallest type can be read, or we measure it by the wire optometer in the manner before described. The amplitude of accommodation is often equal to that in emmetropia, but in the higher degrees of myopia it becomes considerably diminished.

The greatest distance at which an object can be clearly seen, is the exact measure of the myopia, for instance, if the far point be at one metre, a concave glass of that strength (-1 D.) would render parallel rays as divergent as if they came from a distance of one metre, and with a glass of this focus, the person would be able to see distant objects clearly.

Myopia was for a long time thought to be due to an increase in the convexity of the cornea, but as a matter of fact the cornea is usually less convex, and as a rule, the greater the myopia, the less the convexity.

Causes of Myopia :

1. The antero-posterior diameter of the eyeball is too long (axial myopia). This is usually the cause.
2. Increase of the index of refraction of the lens. This may occasionally occur in the development of cataract.
3. Conical cornea simulates myopia at its commencement.

It may therefore be stated that myopia almost invariably depends upon a lengthening of the visual axis, accompanied in many cases by the formation of a *posterior staphyloma*, which further increases the antero-posterior diameter of the eyeball. This bulging when it occurs, takes place at the outer side of the optic nerve towards the macula, and consists of an extension and thinning of the sclerotic and choroid backwards, with more or less atrophy of the latter.

So constant is this lengthening of the visual axis in myopia, that from the number of dioptries of myopia can be calculated the increase in the length of the eyeball.

The following table gives the calculation up to 10 D.

Degree of myopia.	Distance of the p. r. in millimetres.	Increase of length of the myopic eye in millimetres.
5 D.	2000	·16
1	1000	·32
1·5	666·6	·49
2	500	·66
2·5	400	·83
3	333·3	1
3·5	285·7	1·19
4	250	1·37
4·5	222·2	1·55
5	200	1·74
6	166·6	2·13
7	142·8	2·52
8	125	2·93
9	111·1	3·35
10	100	3·80

Fig. 138 shows a section of a myopic eye, in which the outside measurements were :—Antero-posterior diameter $30\frac{1}{2}$ mm. ; vertical diameter 25 mm. ; transverse diameter 25 mm.

It will be remembered that the emmetropic eye measures in the antero-posterior diameter 22·824 mm.

In Fig. 139 the amount of accommodation is indicated in a myope of 2 D. by the number of spaces through which the thick lines pass ; thus, at the age of thirty the accommodation is equal to 7 D., and the near point will be 11 cm. ; the distance of the punctum proximum is given for each dioptre at the bottom of the diagram.

FIG. 138.

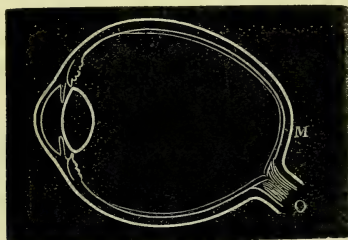


FIG. 139.

Dioptres.




Diagram showing the amount of accommodation at different ages in a case of myopia of 2 D.

As the punctum remotum in myopia is situated at a finite distance, therefore, for the same amplitude of accommodation, the punctum proximum is nearer the eye in myopia than in emmetropia. The near point gradually recedes with advancing age at the same rate whatever the refractive condition of

the eye; it is clear then, that the near point in myopia will be longer in reaching that point (22 cm.), at which presbyopia is arbitrarily stated to commence than in emmetropia, so that in prescribing glasses for presbyopia, the amount of myopia has to be deducted from the glass, which the emmetrope would require at any given age.

If the myopia amount to 4.5 D., then the patient can never become presbyopic, because his punctum remotum is only 22 cm. away, so that he will always be able to see at that distance. Most people imagine, that those who do not require glasses with advancing age, have very strong eyes; how frequently does one hear the remark, when inquiring of a patient's family history, "Oh! my father had excellent sight, he was able to read at sixty without glasses." This is proof positive that he had myopia, though probably you will be unable to convince the patient of this fact.

In hypermetropia it was shown, that the power of accommodation had to be used in excess of the convergence. In myopia, we have the opposite defect, the patient having to converge in excess of his accommodation; thus, if he be myopic 4 D. his far point will be at 25 cm., when looking at an object at this distance it is necessary for him to converge to this particular point, his angle of convergence being 4, while his accommodation remains passive.

Determining Causes.—The chief factors in the production of myopia are: the constant use of the eyes for near work, especially at an early age when these organs are developing; disturbances of nutrition in the tissues of the eye, together in some cases with a peculiar conformation of the skull.

In a large majority of cases, myopia is acquired, but in a small proportion of cases it may be congenital; this latter form frequently attains a high degree in early life, may occur in one or both eyes, and bears no relation to the occupation of the patient. Though seldom congenital it not unfrequently happens that one or other of the parents has suffered from myopia. There is little doubt that in many cases there is an hereditary tendency to it, which, transmitted through several generations, under favourable circumstances for its development, becomes very decided.

As in the greater number of cases of myopia the factor which tends to produce it, is the prolonged use of the eyes on near objects, especially while young; we may set down

myopia as one of the results of civilization and education, and in these days of high pressure and competitive examination, it is constantly on the increase. The result of the very numerous statistics that have been collected, especially by German ophthalmologists (myopia in Germany is exceedingly common), points to the production of myopia in direct proportion to the amount of education. The amount of myopia was found to be much greater in town than in country schools, no doubt because the general health was better amongst those living in the country. Erismann has come to the pleasant conclusion, that if myopia increase in the same ratio as it has done during the last fifty years, in a few generations the whole population will have become "myopic."

The normal refraction of the eye in childhood is hypermetropic, some few remain so, a great number becoming emmetropic as they get older, and a large percentage of these pass on to myopia.

In proof of this hereditary tendency to myopia, Dr. Cohn has summarised the statistics of various German writers on this subject. Thus in public schools myopia was found to exist without predisposition in 8 per cent., with predisposition in 19 per cent. In the higher schools the result was: without predisposition 17 per cent., with predisposition 26 per cent.

Residence in towns is also conducive to short sight by causing people to gaze constantly at near objects.

The cause why myopia when once established is very liable to increase, is that the extreme convergence, which is necessary to enable the patient to see at the limited distance, to which he is confined, causes the weakest part of the globe (that part in fact which is least supported) to bulge, forming a posterior staphyloma. In support of this method of production of myopia, may be stated the well-known fact, that people, such as watchmakers and jewellers, who habitually use a strong convex lens before one eye, and work at the focal distance of that lens, are not especially liable to myopia, proving that close work without convergence does not tend to produce it. As the eyeball becomes elongated its movements become more difficult, and the pressure produced by the muscles during prolonged convergence, tends still further to increase the myopia.

The stooping position which so many myopes take up, causes an accumulation of blood in the eyeball, which tends to raise the tension as well as materially to interfere


with its nutrition. Hence results a state of congestion, softening, and extension, leading to a further increase of the myopia. The more advanced these changes, the more difficult is it for the myopia to become stationary.

In addition to these two causes, extreme convergence and the stooping position, it is possible, that as a result of the constant convergence, the optic nerve may be somewhat pulled upon, and thus further assist in producing myopia.

Cases of *nebulæ*, cataract, and other causes of imperfect sight in children, may give rise to myopia by causing them to hold objects they wish to see close to the eyes.

Symptoms.—The patient sees distant objects badly and near objects well. The eyes look prominent; the pupils are usually large in young people; as age advances they contract,

FIG. 140.



- A. The retina in an emmetropic eye. B. The retina in a myopic one.
 c. The visual angle. N. The nodal point. The distance from NB is greater than NA, and the image of OP is greater at B than at A.

thus diminishing the circles of diffusion, and so slightly improving vision. Eserine acts in the same manner, so does the nipping together of the eyelids, which is so characteristic of patients suffering from myopia, and to which the disease owes its name. The acuteness of vision is frequently below the normal, though objects within the patient's far point appear larger than they do to the emmetrope; the distance between the nodal point and the retina being greater in myopia (Fig. 140). This, however, may be partly counterbalanced by the stretching of the retina, so that, although the image may be somewhat larger, it may not cover a greater number of cones than would be the case in an emmetropic eye.

If the myopia be progressive, frequent limitations in the field of vision occur, in the form of scotomata due to patches of retinal atrophy.

Besides seeing distant objects badly, the patient complains of pain, fatigue, and intolerance of light, with a state of irritation, especially after using the eyes by artificial light. There may be hyperæmia of the eyes and lids, spasm of the accommodation (which increases the apparent amount of myopia), pain in the eyeballs on pressure, photopsia, an appearance of convergence due to the small size of the angle α (p. 405), together with "*muscæ volitantes*." These are often a source of great anxiety; the patient may, however, be assured, that although they cannot be removed, there is no cause for uneasiness: these *muscæ* are probably the remains of vitreous cells which, being situated a considerable distance in front of the retina, throw shadows on it, and are projected outwards as much larger images than would be the case in an emmetropic eye: they appear to the patient as black spots.

The ciliary muscle is smaller than in emmetropia, the circular fibres (which are so hypertrophied in hypermetropia) being almost absent.

The internal recti muscles often act badly, so that convergence becomes painful and difficult, often going on to strabismus divergens.

When the myopia is of high degree, the patient often uses one eye only for reading, then of course he does not require to converge.

The refraction diminishes slightly with advancing age (see p. 510); the pupils also become smaller, thus cutting off some of the patient's circles of diffusion, so that frequently a marked improvement takes place in the vision of myopes as they get older.

Ophthalmoscopic Appearances.—With the ophthalmoscope, a crescentic-shaped patch of atrophy is frequently seen on the outer side of the optic disc, embracing it by its concave edge; this is called the "*myopic crescent*."

In an early stage the crescent looks somewhat white, showing the large choroidal vessels often more distinctly than on the adjoining parts; gradually, the blood-vessels disappear, leaving the white sclerotic, which shows up plainly against the red of the fundus. Some remains of pigment about the convex border of the crescent are often seen, and

frequently there is some thinning of the choroid beyond. The retina seems to participate in this atrophy much less than might have been expected.

Although the atrophy usually assumes the crescentic form, as shown in Plate 1 which was drawn from the fundus of a young man, aged twenty, with a myopia of 4 D., yet it may vary much, sometimes forming a complete ring round the optic disc (II), or it may extend outwards (III), the broadest part being usually between the disc and the macula; sometimes there is excavation of the atrophic part.

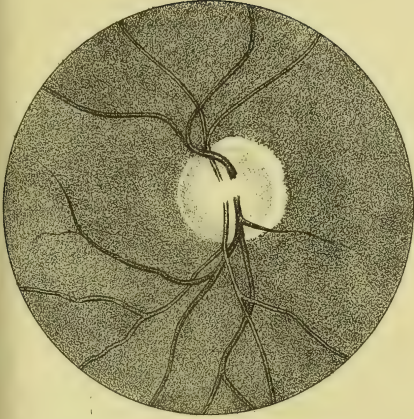
The optic nerve is occasionally displaced, somewhat inwards, and the disc, instead of being directed forwards, looks forwards and outwards, making it appear oblong in shape from its being seen obliquely (III); the retinal vessels that pass over the atrophied part are often straight in their course, and show up very clearly against the white sclerotic.

The formation of the crescent is much influenced by the amount of myopia. In slight degrees in young people it is often absent, but in cases of 6 D. or more, at the age of twenty, we invariably find a well-marked crescent.

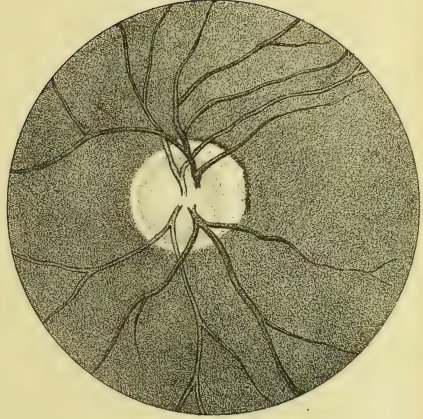
In very high degrees of myopia, the epithelial layer of the choroid atrophies, secondary changes may take place in the yellow spot, as shown in Plate IV; when such changes take place they cause great impairment of vision, due either to extension of the atrophy outwards, or to disease commencing there independently. If the disease be progressive, the vitreous becomes disorganised, with floating opacities; the nutrition of the lens may suffer, opacities forming in it, especially at the posterior pole; hæmorrhages may occur, and detachment of the retina sometimes takes place.

Further it may be said that myopes, owing to their defective vision, are especially liable to accidents.

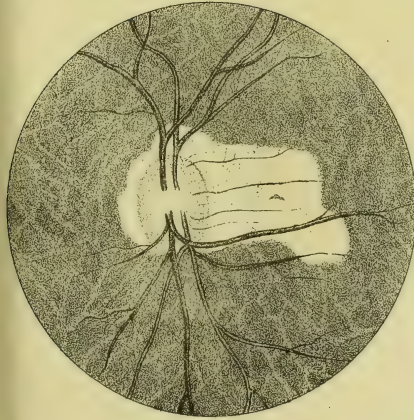
The **diagnosis and estimation** of myopia is easy. At the distant type the patient requires a concave glass to enable him to read $\frac{6}{6}$. The *weakest* lens with which he is able to read it, is the measure of his myopia; always remember the patient is apt to choose too strong a glass if left to himself; to prevent this and enable us to make an exact record of the condition of the refraction, by which we may judge if the myopia is stationary or progressive, it is much the best plan in young people to atropize them in the manner previously described. Great differences will be found in myopes when testing them at the distant type, in some each increase in the



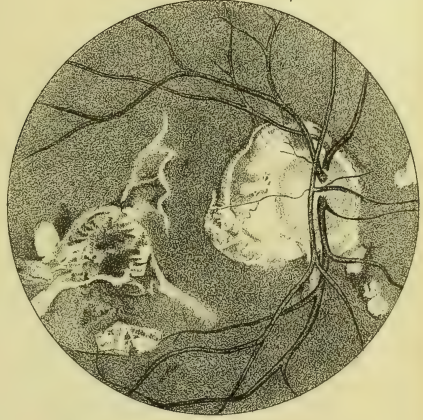1.




2.



3.



4.



strength of the glass causes a corresponding increase of vision; while in others with the same amount of myopia, but little improvement takes place until nearly the full correction is reached, when it suddenly becomes almost normal: hence it is not sufficient after applying two or three concave glasses without any visual improvement, to at once assume the absence of myopia. On placing the near type in his hand, he will be found to be able to read the smallest print, though at a shorter distance than that for which it is marked. The extreme distance at which he is thus able to read it, is his far point, the measure of which is also a measure of his myopia: this is a most useful guide to us; for instance, he reads No. 1 at 25 cm. but no farther; ($\frac{100}{25} = 4$ D.), therefore 4 D. is the measure of the myopia, and such a glass will render parallel rays so divergent, that they will seem to come from 25 cm. Had he been able to read it at 10 cm. only, then ($\frac{100}{10} = 10$ D.) — 10 D. would be the measure of the myopia.

With **retinoscopy** the shadows move in the same direction as the mirror, so long as the observer is beyond the patient's far point (Chap. 21).

With the ophthalmoscope, by the **indirect** examination, the disc looks smaller than in emmetropia and becomes larger on withdrawing the objective farther from the eye.

By the **direct** method of examination at a distance, with the mirror alone, an inverted magnified image of the disc can be clearly seen, provided always that the observer be not nearer the aerial image than his own near point (Fig. 115). The lower the myopia the greater the image, because the longer is the distance between the image and the myopic eye. On moving the head from side to side, the image will always move in the opposite direction, showing that it is an inverted one. When we bring the ophthalmoscope close to the eye, the fundus cannot be clearly seen until a concave glass is placed in front of the observing eye. The *weakest* concave glass with which the details of the macula and disc can be clearly seen (the observer's eye being emmetropic and the accommodation relaxed) is a measure of the myopia (Fig. 118). This test may be relied upon for the lower, but not for the higher degrees of myopia.

The **treatment** of myopia.—The chief indications are:

1st. To prevent the increase of the myopia.

2nd. To enable the patient to see well.

3rd. To prevent the various troubles from which myopes are so liable to suffer, as asthenopia, divergent strabismus, &c.

To carry out the first of these indications, strong convergence and the stooping position, which play so important a part in the production of myopia, must be avoided, the patient being directed never to read in a train or carriage, where every movement requires a change in the accommodation, nor to look at near objects for too long together: the natural tendency for a myope who is excluded in great measure from seeing distant objects, is to devote himself to near ones. In reading, writing, or working, he must keep 35 cm. away from the book or paper, use books printed in good, bold type, and not write too small, while the desk and seat should be conveniently arranged so as to avoid stooping. He should do as little as possible by artificial light; when necessary, it is best to use a reading lamp, so placed that it throws the light down upon the work, leaving the remainder of the room in comparative darkness, so that when the eyes become tired they may be rested by turning them from the light. The stooping position must be strictly avoided, as it causes an increased flow of blood to the interior of the eyeball, and at the same time by compressing the veins in the neck, obstructs the returning blood and so produces hyperæmia with symptoms of irritation, and possibly some slight increase of tension. When reading or writing, he should sit with his back to the window, so that the light may fall on his book or paper over his left shoulder, the shadow of his pen being thus thrown to the right, enabling him to see plainly the letters he is forming.

Attention must be paid to the general health; iron internally often being especially useful, combined with regular outdoor exercise, and good nutritious food.

When symptoms of irritation show themselves, with a rapid increase in the myopia, complete rest must be given to the eyes, and in no way can this be so conveniently carried out, as by dropping into the eyes a solution of atropine (gr. $\frac{1}{2}$ to $\frac{3}{4}$) three times a day, for some two or three weeks; counter-irritation may be applied to the temples and behind the ears in the shape of small blisters, or by a solution of iodine; no spectacles must be allowed. Sometimes where there are symptoms of congestion present, the artificial leech

applied to the temple once a week for a few weeks does much good. As the irritation gradually subsides, the patient may be allowed to do a little reading daily, in a good light, the eyes all the time being kept under atropine; he may require glasses to enable him to do this. Thus, if he have myopia of 3 D. he will not require them, his far point being at 33 cm.; if he has -1.5 D. he would require $+1.5$ D. to enable him to read at about 35 cm. ($+3$ D. -1.5 D. = $+1.5$ D.); if the myopia is 6 D. he will require -3 D. to put back his far point from 16 to 35 cm. ($+3$ D. -6 D. = -3 D.).

So long as the myopia is progressing it must always be a source of anxiety to us.

To enable the patient to see well both near and distant objects, as well as to prevent extreme convergence, we must correct the myopia. In young people with good accommodation and with a low degree of myopia, the full correction may be well borne, the patient wearing such glasses constantly; and it has been observed, that in those, who from their youth have worn their full correction constantly, for both near and distant objects, the myopia has usually remained stationary.

There are two exceptions to this general rule of the full correction of myopia:

1st. Where the myopia is of high degree and the acuteness of vision reduced, then the concave glasses so much diminish the size of the retinal images, that the individual is induced to make these images larger by bringing the object closer.

2nd. When the myopia is of high degree, and the patient has from long custom become used to exercise the function of convergence in excess of his accommodation, the full correction, which gives him perhaps excellent distant vision, causes him pain, when used for near objects; here we must give two pairs of spectacles, one for distant vision, and the other for near objects, the latter may be gradually increased in strength, as the patient becomes accustomed to them, so that after a time, possibly a year or so, the full correction may be comfortable for constant use.

In those cases where the myopia is of high degree, and the patient is unable to bear the full correction for reading, we find out the necessary glass, by subtracting from the lens which gives the best acuteness of vision, that glass whose focus represents the distance at which the patient wishes to

read or work. Thus, for example -9 D. gives the best distant vision, the patient wishes for glasses, with which to read at 33 cm. (-9 D. + 3 D. = -6 D.) -6 D. will be the glass required, and will enable the patient to read at 33 cm. without using his accommodation.

Glasses may also be required for music. When the myopia is of low degree and we are certain that the disease is stationary, folders may be allowed for distance, no glass being used for near work.

Single glasses are occasionally allowed in low degrees of myopia for looking at distant objects; they have the disadvantage that they encourage the patient to give up binocular vision and may so assist in the development of a divergent squint.

When muscular asthenopia is present, prisms with their bases inwards (which diminish the necessity for convergence), with or without concave glasses, are of great value.

When photophobia is a prominent symptom, tinted spectacles may be comfortable.

It is important to impress on the patient, that the glasses for reading are not given to enable him to see better, but to *increase the distance* at which near work can be done.

When the myopia has been estimated under atropine, it is often necessary to add on to the glass so found $-.5$ D., as the full correction under the mydriatic is usually this much weaker than the correction found without it, the reason being that the ciliary muscle is never so completely relaxed as it is by atropine.

I am of course aware that the above optical treatment of myopia is at variance with the teaching of French authorities.

Landolt considers that the action of the ciliary muscle may have a tendency to increase the myopia, and therefore states that myopes should never wear glasses which require the patient to use his accommodation; so that in low degrees of myopia glasses are only allowed for distant objects; in medium degrees, glasses which under-correct the myopia are given for near objects, so as to enable the wearer to see at a given distance without accommodation.

My own opinion is that every case requires treating on its own merits, very many myopes wear their full correction constantly with comfort, and if not with benefit to the eyes most certainly without injury; while other myopes will

occasionally be found who suffer from asthenopia when using their full correction for near vision. In extreme degrees of myopia and in those that are increasing rapidly, rest for the eyes and not spectacles is the essential treatment.

See cases, p. 498, and Chap. 26.

CHAPTER XXIV.

ASTIGMATISM AND ANISOMETROPIA.

ASTIGMATISM, Ἄ, priv. ; *στίγμα*, a point.

Hitherto we have seen, that the cornea usually takes but little part in the defects we have been considering. It has been shown that hypermetropia is almost invariably due to the eyeball being too short, and myopia to its being too long. We now come to a defect in which the curvature of the cornea plays a very important part, with or without some decrease or increase (from the emmetropic standard) in the antero-posterior diameter of the eyeball; I refer, of course, to astigmatism, which is the commonest of all the refractive errors, few cases of hypermetropia being entirely free from it, and still fewer cases of myopia. Astigmatism, then, may be defined as that state in which the refraction of the several meridians of the same eye is different; for instance, the horizontal meridian may be emmetropic, the vertical hypermetropic.

It is usually congenital, but may be acquired, and frequently there is some hereditary tendency.

Astigmatism was first discovered by Thomas Young in 1793, who was himself astigmatic.

Astigmatism may be divided into two chief divisions :

1. Irregular.
2. Regular.

The **irregular** variety, which consists in a difference of refraction in the different parts of the same meridian, may be further subdivided into normal and abnormal:—(a) The normal irregular astigmatism is due in great measure to irregularities in the refracting power of the different sectors of the lens; it causes a luminous point to appear stellate, as is the case when looking at a star, which is in reality round. (b) The abnormal variety may arise from the condition of

the lens or of the cornea; when the lens is in fault it may be a congenital defect, it may be due to changes taking place in the lens itself, or to partial displacement by accident. The changes in the cornea which may produce it, are conical cornea, nebulæ, and ulcers. Little can be done in the way of glasses towards correcting this form of astigmatism, though much improvement of vision sometimes occurs, when stenopaic spectacles are worn, the opening being made to suit the peculiarity of each case.

We now pass on to the much more common variety, which can frequently be exactly corrected by the help of plano-cylindrical lenses.

Regular Astigmatism is due to the curvature of the cornea being different in the two meridians, that of maximum and minimum refraction; these are called the chief meridians, and are always at right angles to each other.

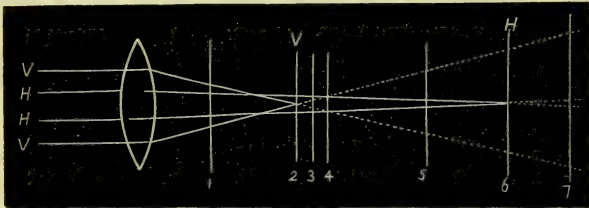
In the normal eye the cornea is the segment of an ellipsoid and not of a sphere, so that there is a slight difference in the refraction of the two chief meridians, the focus of the vertical meridian being slightly shorter than that of the horizontal.

This can easily be proved by looking at a card on which is drawn two lines crossing each other at right angles, the card is held close to the eye and gradually made to recede; both lines cannot be seen at the same time with equal clearness, the horizontal being seen clearly at a shorter distance than the vertical line. So long, however, as the acuteness of vision is not impaired, it goes by the name of normal astigmatism or regular astigmatism of the normal eye.

Parallel rays passing through a convex spherical glass come to a focus at a point. If the cone of light thus formed be divided perpendicular to its axis, at any point between the lens and its focus, or beyond the focus after the rays have crossed and are diverging, a circle is formed. In astigmatism the case is different; if parallel rays pass through a convex lens, which is more curved in the vertical than in the horizontal meridian, those which pass through the vertical meridian come to a focus sooner than those which pass through the horizontal; and the resulting cone instead of being circular, as in the previous case, will be more or less of an oval, forming a circle only at one point (4, Figs. 141 and 142). Let us now divide this cone at different points at right angles to its axis, and notice the shape of the diffusion patches thus produced.


At 1 an oblate oval is formed, at 2 a horizontal straight line, the vertical rays having come to a focus; at 3, 4, 5, the vertical rays have crossed and are diverging, and the horizontal rays are approaching; at 4 a circle is formed; at 6 a

FIG. 141.



vertical straight line, the horizontal rays have met and the vertical are still diverging; a large prolate ellipse is formed at 7.


FIG. 142.



Section of cone of light at 1, 2, 3, 4, 5, 6, 7, Fig. 141.

The space between the two points at which the vertical rays $v v$, focus at v , and the horizontal rays $h h$, focus at h , is called the interval of Sturm (1 Fig. 143).

FIG. 143.



Regular astigmatism was at one time thought to be due to defects in the curvature of the lens, but it has since been proved to depend almost entirely on asymmetry of the cornea. The lens may, however, influence it in two ways:— 1st. Its two chief meridians may not correspond to those of the cornea; 2nd. Owing to the position of the eye the lens may be situated obliquely.

It has been experimentally proved, that slight amounts of corneal astigmatism may be corrected or disguised, by the unequal contraction of the ciliary muscle (one segment of the muscle acting while the rest of the circle remains passive); the curvature of the lens is thus increased, in the direction of the ciliary contraction only.

In astigmatism the vertical meridian has usually the maximum, and the horizontal meridian the minimum of curvature, corresponding to the astigmatism of the normal eye. To this, however, there are numerous exceptions. Thus, the chief meridians may occupy an intermediate position, or the vertical may have the minimum, and the horizontal the maximum of curvature. Whatever the direction of the two chief meridians, they are always at right angles to each other.

There are five varieties of regular astigmatism:

1. Simple hypermetropic astigmatism.
2. Compound hypermetropic astigmatism.
3. Simple myopic astigmatism.
4. Compound myopic astigmatism.
5. Mixed astigmatism.


In the first variety, one set of rays (we will assume the vertical, v) have come to a focus on the retina, while those at right angles, the horizontal (H), focus behind the eye. Thus, instead of a point, as in emmetropia, a horizontal straight line is formed on the retina (Fig. 144).

FIG. 144.



In the second variety, both sets of rays focus behind the retina (Fig. 145).

FIG. 145.



In the third variety, one set of rays (we will assume the vertical) focus in front of the retina, the other set on the retina, thus forming a vertical straight line instead of a point (Fig. 146).

FIG. 146.



In the fourth variety, both sets of rays focus in front of the retina (Fig. 147).

FIG. 147.



In the fifth variety, one set of rays has its focus in front, and the other set behind the retina (Fig. 148).

In the five figures, the focus of the vertical rays has been

placed in front of the focus of the horizontal rays; of course it will be understood that the position of these two foci are frequently reversed.

FIG. 148.



From what has been said it will easily be seen, that when an astigmatic eye looks at a spot, it sees not a spot, but a *line*, an *oval*, or a *circle*, hence its name (*a* and *στίγμα*).

It is necessary that it should be thoroughly understood, how the image of a line is formed on the retina: the clear perception of a line depends upon the distinctness of its edge, and to gain a clear image of this line, it is necessary that the rays coming from a succession of points which make up this line (they of course emerge in every direction) should be brought to a focus on the retina, having passed through the cornea at right angles to its axis. Should they not do so, circles of diffusion are formed, which overlap each other and so render the edges ill-defined. The rays which diverge from the line parallel with its axis, overlap each other on the retinal image, increasing its clearness, except at the extremities, where they overlap and cause some slight indistinctness. Thus, a person with simple astigmatism, myopic in the vertical and emmetropic in the horizontal, sees distinctly *vertical* lines, because the rays coming from the edges of the vertical line, pass through the horizontal or emmetropic meridian, while those which come from the line parallel with its axis, pass through the myopic meridian and overlap each other without causing any indistinctness of its edges. Therefore, a patient with simple astigmatism, sees clearly the line which is parallel with his ametropic meridian, and indistinctly the line parallel with his emmetropic meridian.

Causes:

1. Congenital malformation of the cornea, which may in

astigmatism of high degree, be part of a general malformation of the face and skull.

This variety of astigmatism usually remains unchanged throughout life.

2. Operations involving the cornea or sclerotic such as cataract operations, iridectomy, &c., often cause by their cicatrization a high degree of astigmatism which changes considerably with time.

Symptoms.—There is frequently a want of symmetry about the patient's head or face. If young, and the astigmatism hypermetropic and of low degree, few symptoms may be present; usually, however, the patient complains of defective vision with asthenopia, especially if his work be such, that his accommodation is in constant use; sometimes headache is a very marked symptom, either frontal or occipital; he has probably tried all sorts of spectacles and can find none to suit him. On trying him at the distant type, his acuteness of vision is always below the normal, the mixed variety of astigmatism affecting it most, and next the compound. We sometimes notice when trying the acuteness of vision, that the patient sees much better if allowed to hold his head on one side; by doing this, he places his nose somewhat in the line of vision of the eye he is using, and so cuts off some of the rays which would otherwise enter his pupils; he thus diminishes his circles of diffusion. It is possible also that if his chief meridians are oblique, by thus tilting them, he brings them to correspond with the meridians of the object looked at. Whether this explanation be the correct one, I know not, but we may generally feel pretty confident, when we see the patient looking at the test-type with his head on one side, that astigmatism is present. One frequently hears it said, that images formed on the retina in astigmatism are distorted; this, however, is not the case, as can readily be proved by making one's own eye astigmatic, by placing in front of it a cylindrical glass; a certain amount of blurring and indistinctness is produced, but no actual distortion, the distance between the cornea and retina being insufficient.

Usually both eyes are affected, sometimes quite symmetrically. Frequently, however, there is a great difference, one being almost emmetropic, the other very astigmatic.

In astigmatism when the chief meridians of one eye are at right angles to the chief meridians of the other, binocular may be much better than monocular vision; we will illustrate

this by a simple example. The right eye we will assume to be hypermetropic 2 D. in the vertical meridian, emmetropic in the horizontal; the left emmetropic in the vertical, hypermetropic in the horizontal 2 D. We know that the patient, looking at the fan of radiating lines with the right eye only, will see the vertical lines distinctly, the horizontal only by accommodating; with the left eye the horizontal lines will be clearly seen, the vertical ones indistinctly; with the two eyes all the lines will appear distinct, the image in one eye overlapping that of the other. We seldom find a case in which the correction is so complete as in our example, but we meet with cases where partial correction takes place.

In my experience vision is less impaired when the chief meridians are vertical and horizontal, than when they are oblique.

As hypermetropia is more common than myopia, so also is hypermetropic astigmatism of more frequent occurrence than the myopic variety, though few myopes will be found who are quite free from astigmatism. Mixed astigmatism is the least frequently met with.

If, after trying the patient at the distant type, we are not satisfied with the result, though perhaps we have some improvement with either convex or concave glasses, we may suspect astigmatism and pass on to some of the special tests by which it may be diagnosed and estimated.

If astigmatism exist, our first object must be to find out the direction of the two principal meridians, viz., those of maximum and minimum refraction.

Most of the tests for astigmatism are based upon the facts of the perception of a line. An astigmatic eye, looking at a test object composed of lines radiating from a centre, and numbered for convenience sake like the face of a clock, is unable to see all the lines equally clearly. The line seen most distinctly, indicates the direction of one of the two chief meridians; the other chief meridian being of course at right angles to the one most clearly seen. The fan of radiating lines now very commonly used, as well as the clock face with movable hand of Mr. Brudenell Carter, are all convenient test objects. The striped letters of Dr. Pray are convenient for indicating one of the chief meridians.

To **test** and **measure** the astigmatism, we place our patient at a distance of six metres in front of the clock, Fig. 149, covering up one eye with a ground glass disc. Supposing

he see plainly the three lines from 12 to 6, all the other lines being more or less indistinct, those from 3 to 9 most so, and further, if on placing before the eye a weak positive glass, we find that lines from 12 to 6 are blurred, we know then that the horizontal meridian, that is, the meridian at right angles to the clearly defined line, is emmetropic, as well as being one of the principal meridians. We now direct him to look steadily at the lines from 3 to 9, *i.e.*, those at right angles to the lines first seen; we try what spherical glass

FIG. 149.



enables him to see these lines distinctly and clearly; this glass is the measure of the refraction of the vertical meridian, and therefore also of the astigmatism.


To obtain reliable results, the eye *must* be thoroughly under the influence of atropine.

Supposing lines from 12 to 6 be clearly seen, but that with a weak convex glass they are blurred; and that on looking at lines 3 to 9, no convex glass improves their clearness, while -1 D. renders them quite distinct, the case is one of simple myopic astigmatism.

With the ophthalmoscope the astigmatism may also be

recognised. 1st. With the *indirect* method we find that the shape of the disc, instead of being circular, is more or less oval, changing its shape as the objective, which must be held exactly perpendicular, is withdrawn. 2nd. With the *direct* method we find that the disc appears oval, the long axis of

FIG. 150.

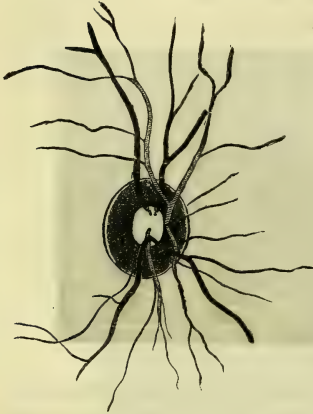

the oval corresponding to the meridian of greatest refraction. Figs. 151 and 152 show the same disc as seen by the direct and indirect examination.

It is, however, the difference in degree of the clearness of the retinal vessels that is to be taken as the guide, not only of the chief meridians, but also of the kind and amount of error. To detect this, assuming that the chief meridians are vertical and horizontal, we take notice first of the lateral margins of the disc, and of a vessel running in the vertical direction, and find out the *strongest* positive, or the *weakest* negative glass, with which these are distinctly seen, using a refracting ophthalmoscope. We then take a horizontal vessel with the upper and lower margins of the disc, and estimate their refraction in the same manner. Thus, a vessel going upwards is first taken; it is seen well with the convex 1, the horizontal meridian therefore is hypermetropic 1 D. A horizontal vessel is now looked at and can be best seen with concave 1, showing that the vertical meridian is myopic to one dioptré; the case is, therefore, one of mixed astigmatism. When the chief meridians are not vertical and horizontal, we must endeavour to find a vessel which coincides with one of the chief meridians, and having estimated this, we next estimate the meridian at right angles to this vessel. Some

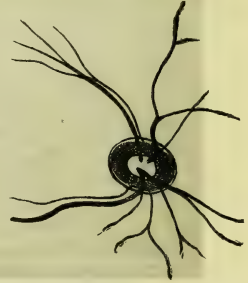observers are able to estimate and order the proper correcting glasses by this method alone. I should, however, be exceedingly sorry to trust to it entirely.

FIG. 151.*



Erect image.

FIG. 152.



Indirect image.

3rd. *Retinoscopy*. This is, I think, the most valuable and trustworthy of all the objective methods. The patient being fully atropized, the principal axes can be seen at a glance, and the proper glasses for correcting the error easily found by anyone who has taken the trouble to familiarise himself with this method of examination. For a full description of retinoscopy, the reader must refer to Chapter 21.

Astigmatism requires for its correction a cylindrical glass, and reference has already been made to such a lens on p. 437.

This cylindrical glass is the segment of a cylinder, whereas a spherical glass is the segment of a sphere; it may be either concave or convex, and is numbered according to the refraction of the meridian of greatest curvature; the result upon the rays will be, that those which pass through the cylinder parallel to its axis, undergo no refraction; all

* I have to thank Mr. Nettleship for these woodcuts, from his work on "Diseases of the Eye."

other rays are refracted, those most so, which pass at right angles to the cylinder. A cylinder thus possesses the power of exactly neutralising the astigmatism.

On referring back to Fig. 144, which represents a case of simple hypermetropic astigmatism, the vertical meridian being emmetropic and the horizontal meridian hypermetropic, it will be seen that a convex cylinder can be found, which with its axis vertical will increase the refraction of rays passing through the horizontal meridian, so that they meet exactly on the retina. Suppose the glass required be + 1 D. cylinder, this not only corrects, but is itself a measure of the astigmatism. If a patient with astigmatism of 1 D. be able to read $\frac{6}{12}$ at the distant type and with the cylinder + 1 D., axis vertical $\frac{6}{6}$, it may be expressed in the following manner: $\frac{6}{12} + 1 \text{ D. cy. axis vert.} = \frac{6}{6}$.

Fig. 145 represents compound hypermetropic astigmatism. We find out the refraction of each chief meridian by retinoscopy or the clock face. Assuming then, the vertical meridian to be + 1 D., and the horizontal + 2 D., if we place our positive cylinder + 1 D. with its axis vertical, we shall have corrected the astigmatism, and the error will be reduced to one of simple hypermetropia, requiring for its correction + 1 D. sphere. This combination of sphere + 1 D. with cylinder + 1 D. axis vertical, is made in one glass, by the optician grinding upon one side the sphere + 1 D., and on the other the cylinder + 1 D. The lens thus formed is called a spherico-cylindrical lens.

Fig. 146 represents simple myopic astigmatism, in which the vertical meridian is myopic and the horizontal emmetropic. To correct this error, it is necessary to cause the rays which pass through the vertical meridian to be so refracted, that they meet *at*, instead of *in front of*, the retina. Here it is obvious that a negative cylinder with its axis horizontal will accomplish this object.

Fig. 147 represents compound myopic astigmatism. Both sets of rays focus in front of the retina, one set in advance of the other. This is corrected by putting back the posterior focus by a negative sphere which reduces the case to one of simple myopic astigmatism, which is corrected by a negative cylinder. This glass is called a negative spherico-cylindrical lens.

Fig. 148 represents mixed astigmatism. One set of rays focus in front of the retina, the other set behind it. The

difference between these is the amount of astigmatism, and may be corrected in three different ways. Thus, supposing the vertical meridian myopic 1 D., and the horizontal hypermetropic 1 D., the correction may be made by -1 D. cylinder, axis horizontal, which puts back the vertical rays so as to focus on the retina, combined with a $+1$ D. cylinder axis vertical, which brings forward the horizontal rays to the retina. This compound lens is called a concavo-convex cylinder. There are, however, some difficulties in using this method of correction; the axes of the cylinders have to be arranged with such exactness, that the slightest variation may upset the whole result. Besides, it is difficult when using such a combination at the distant type, to make alterations with the same facility with which one does other combinations. Moreover, during the grinding very great care is required of the optician, so that either of the following plans seems preferable. By a minus concave spherical glass of 1 D., combined with a convex cylinder of 2 D. axis vertical, or by a $+1$ D. sphere combined with -2 D. cylinder axis horizontal.

Treatment.—Having found out by one of these numerous methods, the refraction of the two chief meridians, we confirm the result by trying the patient at the distant type with the combination so found, making any slight alterations which may be necessary. These glasses may be ordered at once, remembering that in hypermetropic astigmatism, we must reduce the convex sphere about 1 D., while in the myopic variety the concave sphere must be slightly increased by about 1 D.

We frequently have to be satisfied with glasses which do not raise the vision to $\frac{5}{6}$, and if such have been carefully chosen, we often find that after they have been worn for some time the vision improves, due no doubt to the retina becoming more sensitive to well-defined images, a condition of things to which it was previously unaccustomed.

In ordering glasses for astigmatism, we must be careful to give the exact axis of each cylinder; opticians supply us with convenient forms, having a diagram of a frame marked in degrees; we indicate the axis by drawing a line through this diagram.

The **Ophthalmometer of Javal and Schlötz** is an instrument for measuring the amount of corneal astigmatism. Scientifically it may be of much value, as by it we are enabled

to separate astigmatism due to the cornea from that due to the lens, but the price will prevent its coming into general use, especially as we possess so many other methods by which astigmatism may be estimated, and probably the separation of the two forms of astigmatism is a disadvantage practically, when we are seeking to correct the defect.

With the ophthalmometer two objects are reflected on to the cornea of the observed eye; these objects are of white enamel, one quadrilateral in shape, the other of the same size, except that on one side it is cut out into five steps; these two objects slide on a semi-circular arm, which rotates round the tube through which the observer looks, one object on either side of the tube; the observer looking through this tube, which contains a combination of convex glasses and a bi-refracting prism, sees four magnified images in a line on the cornea under examination. First find out the meridian of least refraction; this we are able to do by finding the position of the semi-circular arm, in which the two central images (one quadrilateral, the other with steps) are furthest apart. We slide the two objects together until we see the two central images on the observed cornea just touch, the lowest step of the one with the side of the other; this then is the meridian of least refraction, and we note it down as such; now turn the arm at right angles to this meridian, and notice the amount of overlapping of the two central images, each step in the one figure that is overlapped by the quadrilateral one, is equal to one dioptré; thus if it overlap three steps, there is a difference of 3 D. between the meridians of least and greatest refraction; we know this to be the meridian of greatest refraction, because it is at right angles to the one first found.

As there are only five steps, when there is a difference of 5 D. between the two meridians, the one figure will exactly overlap the other; for higher degrees we have to calculate how much the figure with the steps projects beyond the quadrilateral figure, or we may place in the tube a stronger bi-refracting prism, then each step may be counted as two dioptrés instead of one.

Nordenson has obtained some interesting statistics with this ophthalmometer (*Ophthalmic Review* for July, 1883) in 226 school children. As a result of these statistics he is of opinion:

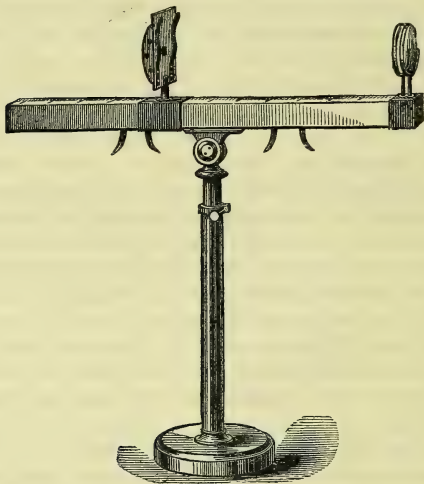
1st. That the correction of corneal astigmatism by means of the lens in young persons is the rule.

2nd. That corneal astigmatism amounting to one and a half dioptries, is incompatible with normal acuteness of vision.

His observations add also to the opinion of Javal, that astigmatism predisposes to myopia.

Tweedy's optometer affords an easy method of estimating the refraction in astigmatism. It consists essentially of a plate carrying the figure of a dial marked with fine dark radiating lines at angles of 15° with each other; the plate is attached to a horizontal bar half a meter long, divided into centimetres on which it may be made to slide; at the

FIG. 153.



proximal end of the bar is a semi-circular clip, marked with degrees corresponding to those on the dial, and intended to hold the cylindrical lens. In order to use the instrument properly, the following instructions must be strictly complied with:

1st. The eye about to be examined having previously been placed completely under atropine, and made artificially myopic to about 4 D. by means of a strong convex lens placed in a spectacle frame, and the opposite eye excluded

by an opaque disc, the patient should sit down before the instrument, place the eye with the lens before it close to the clip, and with the head erect should look straight in front at the radiating lines of the dial.

2ndly. The dial having first been removed beyond the point of distinct vision, should then be gradually approximated along the bar, until at least one of the lines is clearly and distinctly seen; after this the dial should on no account be moved, but its distance from the eye accurately noted.

If all the radiating lines come into view with equal clearness at the same time, there is but slight astigmatism, but if whilst one line is clearly seen, that at right angles to it is blurred, there is astigmatism, which may be corrected, by placing in the semi-circular clip a concave cylindrical lens with its axis parallel to the blurred line, or at right angles to that first distinctly seen.

From the result of (2) we learn (a) the direction of the two principal meridians, of maximum and minimum refraction; (b) the presence or absence of hypermetropia or myopia and the degree; (c) the presence or absence of abnormal regular astigmatism, including its direction and degree. (a) The meridian of greatest refraction is parallel to the line seen at the greatest distance of distinct vision, while the meridian of least refraction is always at right angles to it. (b) The presence or absence of ametropia is determined by the distance at which the radiating lines are clearly seen. If there be emmetropia, the lines will be seen exactly at the distance of the focal length of the lens employed to produce the artificial myopia; if there be hypermetropia, the lines will be seen beyond that point, if myopia within. The degree of ametropia may be estimated by the following calculation: The greatest distance of distinct vision, minus the focal length of the lens, divided by the multiple of these numbers, equals the degree of ametropia.

(c) If, however, there be astigmatism, the above calculation will give the refraction for the meridian of least refraction only; the degree of astigmatism will be represented by the focal length of the weakest concave cylinder, which, placed with its axis parallel to the blurred line, makes this line as clear and distinct as that first seen. The whole ametropia may then be corrected by combining the spherical lens required for the correction of the meridian of least refraction, with the weakest cylindrical lens, which by actual

experimentation has been found sufficient to correct the astigmatism.

Placido's disc, which consists of a circular sheet of tin, on which is painted concentric circles of black and white, gives the chief meridians at a glance. The patient being placed with his back to the light is directed to look at the centre of the disc, while the observer, holding the instrument close to his own eye and at a convenient distance from the patient's, looks through the hole in its centre; he sees an image of the concentric circles reflected on the cornea; if astigmatism exists, the rings will appear elliptical, with the long axis corresponding with the meridian of least curvature. Cases of irregular astigmatism and conical cornea are easily detected by this method.

The **stenopaic slit**, which consists of a metal disc having an oblong opening in it, about 2 mm. broad, is used by some observers for working out cases of astigmatism. The disc is placed in a trial frame in front of the eye we wish to examine; and while the patient looks steadily at the distant type the disc is slowly rotated, so that the slit is brought successively in front of each meridian, the position in which the best vision is obtained is noted, we then try convex and concave glasses in front of the slit, to see if any improvement take place. The slit is now in line with one of the chief meridians; let us turn the disc round 90° , so that the slit may occupy the position of the other chief meridian, and find out what glass most improves vision. Thus, supposing with the slit in the vertical direction, the patient reads $\frac{6}{6}$, while convex glasses in front of the slit make it indistinct, the vertical meridian is emmetropic; and on turning the slit so that it is horizontal, the patient reads $\frac{6}{1\frac{1}{2}}$, but with $+ 2$ D. in front $\frac{6}{6}$, the horizontal meridian is then hypermetropic; and the case is therefore one of simple hypermetropic astigmatism requiring for its correction $+ 2$ D. cylinder axis vertical. On looking through the slit, placed between the principal meridians, circles of diffusion are formed, and the object has the appearance of being drawn out in the direction of the slit.

Dr. Tempest Anderson, of York, has invented an ingenious instrument, by which astigmatism may be estimated in a subjective manner; an image of an illuminated radiating screen is thrown on the retina, and is visible to the oculist, the position of the screen on a graduated bar shows the refraction.

The inventor claims for his instrument the following advantages :

1. The observations and measurements are made by the observer, and are entirely independent of the patient's sensations, though these may be used as an adjunct if wished.

2. An image thrown on the retina being used as an object, the error arising from the vessels or optic nerve being before or behind the retina is avoided.

3. The refraction and accommodation of the observer does not affect the result. It is only necessary that he should be able to see whether certain lines are sharply defined.

In addition to the methods already described for estimating astigmatism, many others are known.

See Cases 3, 4, 5, 6, 7, 8, 9, p. 499, &c. ; also 20 and 21, p. 572.

ANISOMETROPIA.

Anisometropia (A, priv. ; *ἴσος*, equal : *μέτρον*, measure ; *ὤψ*, the eye) is the term applied to cases which frequently occur, where the two eyes vary in their refraction. The defect is usually congenital, but it may be acquired, as in aphakia or loss of accommodation in one eye. Every possible variety may exist, one eye may be emmetropic, the other myopic or hypermetropic ; or one more myopic, hypermetropic, or astigmatic than the other.

When the difference is not very great (1 or 1.5 D.), and vision in both eyes is good, we may give each eye its correction ; for so long as the eye whose refraction is the more defective still co-operates in binocular vision, sight is improved thereby. Especially is this full correction useful in cases of myopia with divergent strabismus, the increased stimulus to binocular vision being sometimes sufficient to prevent the squint. When one eye is emmetropic and the other myopic, no glass will probably be required, the emmetropic eye being used for distance, the myopic for reading, &c. When the difference in the refraction is greater than 1.5 D. we may have to be satisfied with partially correcting the difference, and this result can only be arrived at by trying each case, some people tolerating a much fuller correction than others. When binocular vision does not exist, frequently no attempt can be made to correct the two eyes, and

then we generally give glasses that suit the best eye. In cases of aphakia, &c., where one eye is used almost entirely, while the other though defective still possesses vision, it is an excellent plan to insist on the latter being daily exercised with a suitable glass, the good eye being at the same time covered; by this means, the bad eye is prevented from becoming worse, and can at any time be utilised should occasion require.

See Cases 4, p. 499, 14 and 15, pp. 569 and 570.

CHAPTER XXV.

PRESBYOPIA. Pr. (*πρέσβυς*, old; *ὤψ*, eye).

WITH advancing age many changes take place in the eye. The acuteness of vision becomes less, owing partly to a loss of transparency in the media, and partly also to a diminution in the perceptive and conductive powers of the retina and the optic nerve. At thirty years the acuteness of vision is almost unaltered, the bottom line of the distant type being read at a little over 6 metres; at forty it can still be read at 6 metres, but after this time it diminishes regularly, so that by the eightieth year vision has decreased to one-half. In addition to these changes, the *accommodation* gradually diminishes from a very early period, the near point slowly but steadily receding. This change in the accommodation occurs, in all eyes whatever their refraction, and is due to an increased firmness of the lens, whereby its elasticity is lessened; and perhaps also in some slight degree to loss of power in the ciliary muscle due to advancing age. The lens also approaches the cornea, and becomes somewhat flatter. This failure of the accommodation begins as early as the tenth year, at an age when all the functions of the body are still developing.

So soon as the binocular near point has receded beyond the distance at which we are accustomed to read and write, do we become restricted in our work. Donders has fixed this point at 22 cm.

Presbyopia, therefore, may be arbitrarily stated to exist, when the binocular near point has receded to 22 cm., and this occurs usually in the emmetrope about the age of forty-five. Because in order to see at 22 cm. a positive refractive power of 4.5 is necessary ($\frac{100}{22} = 4.5$), at the age of forty the eye possesses just this amount of refractive power, but if the eye has not so much accommodation, then we must give such a convex glass, which added to it, brings up the positive refraction to 4.5 D.; for example, at the age of fifty-five when the eye possesses only 1.5 D. of accommodation, we give a

convex glass of 3 D., because $1.5 \text{ D.} + 3 \text{ D.} = 4.5 \text{ D.}$ (see table, p. 551).

Fig. 154.

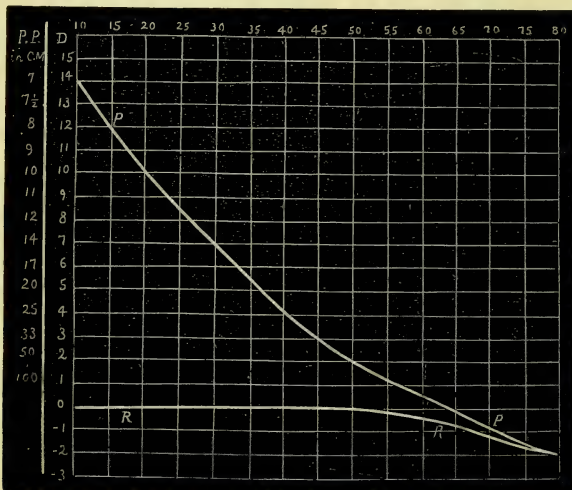


Diagram showing the course of accommodation in an emmetropic eye. The figures at the top of the diagram indicate the age, those at the side the amount of accommodation and the p. p. in centimetres; the oblique line represents the course of the punctum proximum, and the horizontal line that of the punctum remotum; the space between the two lines gives the amplitude of accommodation. From this diagram we can calculate the amplitude of accommodation possessed at any age.

To find the punctum proximum of an emmetrope we have only to divide the number of dioptres of accommodation which he possesses into 100 cm. Thus at twenty there are 10 D. of accommodation; this would give us 10 cm. as the near point. At forty there are 5 D., in which case the near point is 20 cm.

When the punctum proximum has receded to 22 cm.; the point at which it is convenient to read is considerably further away, since for sustained vision only about half of the accommodation can be used. Thus a person with 4 D. of accommodation would have his near point at 25 cm. with the maximum contraction of his ciliary muscle, and if he can

only comfortably use about half this for continuous work, his reading point would be 50 cm.; this is far too great a distance. We bring back the near point by convex glasses, which is practically the same as increasing the accommodation.

Although we have said, that only about one-half of the accommodation can be used for sustained vision, this is not absolutely correct, the amount which must be in reserve, varies much with different individuals; thus in one case with a surplus of 1 D. much work can be done, whereas, in another a surplus of 3 or 4 D. is necessary.

Symptoms.—The presbyope sees well at a distance, but has difficulty in maintaining clear vision for near objects, the chief symptoms are a feeling of weariness in the eyes after reading, especially in the evenings, small objects being less easily seen than formerly, because, having to be held further from the eye they subtend a smaller visual angle. The patient seeks a strong light, or places the lamp he is using between his eye and the book, by doing this he causes his pupils to contract and so lessens his circles of diffusion, he avoids small print, and holds the book or work further away. These symptoms are due to a recession of the near point, and if asthenopia occur, this may be dependent upon a disturbance of the balance between accommodation and convergence; the convergence being the same for any given point, a much greater accommodative effort is necessary than was formerly the case.

The **treatment** of presbyopia consists in prescribing convex spectacles for reading and near work, so as to bring back the near point to a convenient distance. In uncomplicated presbyopia distant vision is, of course, good. We have only to remember to add on 1 D. for every five years up to sixty, commencing at the age of forty-five.

The following table gives approximately the strength of glasses required by emmetropes at different ages, to bring back their punctum proximum to 22 cm. :

Age.	Amount of accommodation possessed at that age.	The near point.	Glass required to bring back p.p. to 22 cm.
45	3·5 D.	28 cm.	+ 1 D.
50	2·5 D.	40 cm.	+ 2 D.
55	1·5 D.	67 cm.	+ 3 D.
60	·5 D.	200 cm.	+ 4 D.
70	·0 D.	infinity.	+ 4·5 D.

To find the glass required in presbyopia, we subtract the glass which represents the receded near point, from the glass whose focus represents the point we wish to make the near point. Thus the near point has receded to 50 cm.; the glass representing this point is + 2 D. ($\frac{100}{50} = 2$). We wish to bring the near point to 20 cm.; this would be + 5 D. ($\frac{100}{20} = 5$); hence + 2 D. from + 5 D. gives + 3 D. as the glass required.

Although glasses can be frequently thus ordered by a sort of rule of thumb, it is always well to bear in mind, that the definition given of presbyopia with reference to its near point is entirely an arbitrary one, and that we must take into account the distance at which the individual has been accustomed to read and work. In this there is great variety. Many small people work and read at 20 cm., whereas, very tall people may be uncomfortable unless the book they are reading is 35 or 40 cm. away. The distance for which the presbyope requires spectacles will also vary much according to the occupation for which he requires them. There exists a popular prejudice against the use of strong glasses, all sorts of maladies having been attributed to their use; this prejudice is quite unfounded. If too strong they may bring the reading point inconveniently near, or they may produce asthenopia, but nothing more.

Before ordering glasses for presbyopia, it is necessary to try the patient's distant vision, so that any hypermetropia or myopia may be recognised. If hypermetropia exist, the amount must be added to the presbyopic glass; if myopia, it must be subtracted. Thus a patient with hypermetropia requiring + 2 D. for its correction, at the age of forty-five will require + 3 D. for reading (H. 2 D. + Pr. 1 D. = + 3 D.).

A myope of 1 D., will require no glass at the age of forty-five (M. 1 D. + Pr. 1 D. = 0.). If the myopia be 4.5 D. then the patient can never require a glass for presbyopia, his far point being 22 cm. always. His near point may recede to this distance when all accommodation is lost, but he will still be able to read at that distance, though at that distance only.

As age advances the refraction of the eye diminishes, in other words, the eye if emmetropic becomes hypermetropic (called acquired hypermetropia). The myopic eye becomes less myopic, so that a real improvement in vision takes

place. The hypermetropic eye becomes more hypermetropic. This change takes place at a regular rate in all eyes, at fifty-five the refraction has diminished $\cdot 25$ D., at sixty-five $\cdot 75$ D., at sixty-eight 1 D., and at eighty as much as 2.5 D. Thus at eighty an emmetrope will have acquired 2.5 D. of hypermetropia, and will therefore require a convex glass of 2.5 D for distant objects to be seen clearly. A myope of 2.5 D. would at eighty have become emmetropic, and require no glass for distance. A hypermetrope of 2.5 D., will add on to his defect 2.5 D., and will require a + 5 D. for distance. This change is due to a sclerosis and enlargement of the crystalline lens, by which its refractive power is diminished.

Dr. Scheffler some years ago proposed the use of what he called orthoscopic lenses, that is, lenses with two elements, a sphere and a prism, so proportioned that the amount of accommodation and convergence should exactly correspond. Thus in the case of a presbyope, aged fifty, requiring + 2 D., to make him read comfortably at 30 cm., it would be combined with a prism base inwards, that would bring the optic axes exactly to that point, the effect being complete repose both for the accommodation and convergence. The results, however, are not so good as might have been hoped; the glasses are too heavy, and on looking at a flat surface some distortion is produced. Nevertheless, cases do occur, in which though the presbyopia is corrected, the patient after reading a short time complains of asthenopia. Such cases are frequently at once and completely relieved by combining with their spheres, prisms of 2° or 3° with their bases inwards, or by having the lenses decentred, so that he looks through the outer part of them, making thereby convex prisms.

Care must be taken to see that the glasses are properly centred, unless they have been ordered otherwise, for if the frames are too broad, the lenses will form prisms with their bases outwards, and are then very apt to give rise to asthenopia, by disturbing the relations between convergence and accommodation.

In cases where the convex glasses have frequently to be changed for stronger ones, "glaucoma," should be carefully looked for; and if any symptoms of it appear, no glasses must be allowed, as it is of the greatest importance to avoid all possible tension.

The commencement of cataract also appears to hasten presbyopia.

In each case of presbyopia, first test the patient's distant vision, so as to detect any hypermetropia, myopia, or astigmatism, and having recorded this, we add the glass which he requires for his presbyopia and try him with the reading type, if they suit we direct the patient to read with them for half an hour or so; if found satisfactory we order spectacles of this strength.

See Cases 12, 16, 17, and 18, pp. 571 and 572.

PARALYSIS OF THE ACCOMMODATION.

Paralysis of the accommodation, either partial or complete, arises from loss of power in the ciliary muscle (cycloplegia), and is due to paralysis of the third nerve, or of that branch of it which supplies the muscle of accommodation and the circular fibres of the iris. Cases do occasionally occur, though very rarely, of paralysis of the ciliary muscle, not involving the constrictor pupillæ. Generally both eyes are affected, frequently, however, only one.

When the paralysis is confined to the ciliary muscle and iris, it goes by the name of ophthalmoplegia interna.

Causes.—Atropine is the most common cause, but it may be due to diphtheria, rheumatism, fever, any complaint of a lowering character, cerebral trouble, syphilis, diabetes, or some reflex irritation, *e.g.* decayed teeth, &c.; the cause may, however, not be apparent. When the whole third nerve is involved, ptosis, external strabismus, &c., occur; but in those cases where the branch supplying the ciliary muscle and the circular fibres of the iris is alone implicated, the indicating symptoms are, asthenopia, dilatation of the pupil, and loss of the power of accommodation, whereby the patient though able to see distant objects well (if emmetropic) is unable to read or do any near work. If hypermetropic, both near and distant vision will be impaired; if myopic he is able to see only at his far point. We try the patient at the distant type, and if he is able to see $\frac{6}{6}$ and yet is not able to read near type, the diagnosis is obvious.

Treatment consists in giving such convex glasses as enable him to read. In order to bring the emmetrope's far point from infinity to 35 cm. + 3 D. is required ($\frac{1}{\frac{1}{3} - \frac{0}{5}} = 3$ nearly). We must bear in mind that by encouraging the action of the ciliary muscle, we hasten the patient's recovery; this we do by giving the *weakest* convex glasses with which

he is able to read, changing them for weaker ones occasionally as the ciliary muscle gains strength. Sulphate of eserine in solution grs. j to $\bar{3}$ j, causes contraction of the ciliary muscle as well as of the iris, and temporarily relieves the symptoms; I think much good sometimes results from its use once every other day for some weeks, the ciliary muscle being made to contract, relaxing again as the effect of the myotic passes off; sometimes the local application of electricity is useful. Attention must be paid to the general health, iodide of potassium or nerve tonics being given, when indicated by the cause.

See Case 13, p. 569.

SPASM OF THE ACCOMMODATION.

Spasm of the Accommodation may be of two kinds, *Clonic* or *Tonic*.

Clonic spasm occurs only when the eye is in use, ceasing as soon as it is in a condition of repose.

Tonic spasm is more permanent, requiring atropine or one of the other mydriates for its relief; the expression *spasm of accommodation* usually refers to this variety of the disorder.

Tonic spasm of the ciliary muscle may be occasionally met with in eyes whatever their refraction, though most commonly in cases of hypermetropia and low myopia, it has the effect of increasing the refraction of the eye, and is found most frequently in children.

Causes.—It may occur as a result of uncorrected ametropia, or in emmetropia from overwork, especially when such work has been done in a bad light; as a result of contusion of the eyeball, and sometimes it occurs with cyclitis.

Symptoms.—It usually affects both eyes, giving rise to symptoms of asthenopia with a feeling of constriction and discomfort in the eyes themselves, there may be an increased secretion of tears with or without blepharospasm; the acuteness of vision is usually diminished and is very variable, while the size of the pupil usually remains unaffected. In emmetropia we may get symptoms of myopia owing to the parallel rays coming to a focus in front of the retina. In hypermetropia the symptoms may also simulate myopia, and for this we should always be on our guard. I have on several occasions seen hypermetropes going about wearing

concave glasses, to correct their supposed shortsightedness. Only a few weeks ago I saw a young man who had worn — 7 D. constantly for years though his refraction was really emmetropic. In myopia the real defect is apparently increased, and we might be in danger of ordering too strong concave glasses, &c. For these reasons the systematic use of atropine in young people (whereby one is enabled to estimate and record the exact state of the refraction) cannot be too strongly insisted upon. The **treatment**, where spasm of the ciliary muscle is suspected, is to drop into the eyes three times a day, a solution of atropine grs. iv to ζ i for two or three weeks, this quickly relieves the spasm and gives the eyes complete rest; to correct any ametropia that may exist; and to attend to the patient's general health, administering tonics if necessary.

A few cases of acute spasm of the accommodation have been recorded which resisted the treatment by atropine, the spasm though relaxed by this means, returned as soon as the atropine was discontinued.

See Case I, p. 498.

ASTHENOPIA.

Asthenopia (A, priv.; *σθενος*, strength; *ὤψ*, the eye), or weak sight, is a term used to designate a group of symptoms, which indicates a condition of fatigue of the intra- or extra-ocular muscular systems.

Asthenopia frequently accompanies hypermetropia, myopia, and astigmatism, and reference has often been made to it when speaking of these errors of refraction. We also meet with it in a certain number of cases where no ametropia exists.

Asthenopia shows itself by the inability to continue a steady and prolonged convergence, and is accompanied with more or less pain; it is exceedingly common, and one may state with confidence that pain in the eyes, unconnected with inflammation, is almost invariably due to asthenopia, and but seldom to any deep-seated disease, and the more acute the pain the more does it point to asthenopia; as a rule, however, the pain is not very severe, it may be situated in the eyes themselves, or around the orbits, and is always increased when the eyes are used for near objects; in some cases no pain is felt, but after reading for a time the type becomes indistinct or double, so that the patient has to stop and look

about the room, or rub his eyes, after which he will be able to resume reading for a short time, to be again quickly interrupted by a repetition of the same symptoms. If the work be still persisted in, the pain around the eyes increases, there is photophobia, a sensation of dazzling and dimness, more or less conjunctival congestion, the eyes becoming red and irritable; all these symptoms are liable to be worse in the evening after a day's work, when there is the additional disadvantage of an artificial light, which is in itself hot and irritating.

Headache is often a prominent symptom of asthenopia; it may take the form of heaviness or pain over the brow (which may or may not be combined with general headache); it is often periodic in character, and is always made worse by reading; frequently there is a tender spot on the top of the head, or pain in the occipital region, occasionally also there is pain in the back of the neck. These symptoms may be associated with dyspepsia, palpitation, and vomiting, and in some cases insomnia is a marked symptom.

This train of symptoms has occasionally been so severe as to lead to the diagnosis of brain disease, hence it is a good rule to test the refraction under atropine in all cases of persistent headache not giving way to ordinary medical treatment, and it must be remembered that a very slight amount of astigmatism left uncorrected, even though the chief portion of it may be corrected, will be sufficient in some cases to keep up the headache.

There is little doubt that frequently reflex nervous disorders are caused by asthenopia.

Asthenopia may be divided into—

1. Accommodative.
2. Muscular.
3. Reflex.

Accommodative Asthenopia is exceedingly common, and is produced by an inability to maintain the necessary accommodation, and may arise (*a*) from a weak condition of the ciliary muscle, (*b*) from excessive use, as in hypermetropia, (*c*) from unequal demand, as in astigmatism, (*d*) from unequal demand in the two eyes, as in anisometropia, (*e*) from diminished elasticity of the lens, as in presbyopia.

When Donders discovered the common occurrence of hypermetropia, he soon became aware of the intimate connection which existed between it and asthenopia; and was

at first inclined to attribute every case to this cause. Where no manifest hypermetropia was present, he gave a solution of atropine to paralyse the accommodation, feeling confident that some latent hypermetropia would then display itself: such cases were usually completely cured by proper convex glasses. This accommodative asthenopia is due in great measure to the constant and excessive action of the ciliary muscle, but partly also to the abnormal relations existing between the two functions accommodation and convergence; this statement is supported by the fact that hypermetropes who squint seldom suffer from asthenopia. An emmetrope looking at distant objects, does so without any accommodation, the ciliary muscle being passive; but the hypermetrope has to use his ciliary muscle even for distant objects, and therefore much more for reading or near work; so that the ciliary muscle practically gets no rest. A young and vigorous patient whose hypermetropia is not very high, may resist asthenopia for a long time, but as he gets old, or his health suffers from any cause, symptoms of this disorder are apt to appear, and when once established they are very liable to continue notwithstanding improvement in the patient's general condition. If the patient be a woman, asthenopia is very apt to come on during lactation.

Treatment.—We order such glasses as are necessary to correct the refraction according to the rules given. In some cases where convex glasses do not produce the desired relief, prisms of 2° bases inwards combined with the spherical correction are of great use, or in slight cases we place the convex glasses somewhat near together so that the patient looks through the outer part of them (Fig. 156). This plan is frequently very useful in presbyopia. Here the asthenopia is due, to a greater muscular effort being required to produce the necessary change in the shape of the less elastic lens, and perhaps also in part to the difficulty of maintaining an exact state of equilibrium between the internal and external recti muscles.

In hypermetropia there is a want of harmony between the accommodation and the convergence, the two functions having to be used in unequal degrees, and when we correct his refraction with glasses, he will have to use these two functions equally, or at least in different proportions to that to which he has been accustomed. Many people are able at once to accommodate themselves to this new state of affairs; but

there are others in whom the force of habit is so strong, that they cannot thus throw off the acquired habit of using the accommodation in excess of the convergence. You must not, therefore, be discouraged if occasionally your patient is not at once and completely relieved of his asthenopia, as soon as you have given him convex spectacles. A fortnight's trial should be made before we can decide that such spectacles will not relieve the patient of his asthenopia.

Asthenopia depends much upon the nervous system of the individual, in some a very slight amount of astigmatism will produce accommodative asthenopia; one hypermetrope will have no uncomfortable feelings, while another whose condition seems exactly similar, will suffer much, so that it is essential to attend to the patient's general health and nervous system.

Muscular Asthenopia is most frequently due to myopia, though it occasionally occurs in emmetropia or even hypermetropia, it is characterised by the inability to maintain prolonged convergence. The patient complains that the eyes become tired, especially during the evenings, reading or writing cannot be continued for any length of time; then he has pain in and around the eyes, with headache; objects look dim and indistinct, and there is a tendency to see objects double; sometimes the patient experiences a sensation as if one eye had turned outwards, which may really be the case; frequently the patient finds relief by closing one eye.

This muscular asthenopia is due to *insufficiency of convergence*, the amplitude of convergence being more or less diminished. The internal recti are weaker than their antagonists the external recti, so that they are obliged to keep up a vigorous action to prevent the eye from deviating outwards; this leads to fatigue of the internal recti with its accompanying symptoms. As in the accommodative variety we find great individual differences, due no doubt to the fact that some individuals are able to dissociate the two functions accommodation and convergence, more than others.

In myopia the disturbance of the two functions accommodation and convergence, may in some measure tend to the production of this form of asthenopia. Thus a patient with 4 D. of myopia has his punctum remotum at 25 cm.; to see an object at that distance, he must converge to that point, maintaining at the same time a passive condition of his accommodation.

The two following tests for detecting this insufficiency of convergence are commonly employed.

The patient is directed to look at some small object (such as the point of a pencil) about 30 cm. off, with one eye, while the other is excluded with a ground glass disc; the pencil is now gradually approached, the covered eye being watched; at a certain point it will be seen to deviate slightly outwards; as soon as the eye is uncovered it makes a corresponding movement inwards to fix the object; on repeating the experiment with the other eye, exactly the same takes place; the reason of this is, that when one eye is covered the stimulus for binocular vision is lost, so that the eye which is excluded from vision is abandoned to the unbiassed action of its muscular system and deviates outwards, returning to its normal position when again allowed to take its part in vision.

The second and more accurate test, is to place a prism of about 15° , with its base downwards, in a spectacle-frame before one eye; by this means we cause a displacement of the eye upwards, and of course also vertical diplopia. The patient is now directed to look steadily at a card on which is drawn a line with a dot in its centre, placed at the patient's ordinary reading distance (Fig. 155). Naturally he will see two dots. If he see one line only with two dots on it, his muscles are assumed to be of the normal strength; if, however, two lines are seen with a dot on each, then insufficiency exists; and the strength of the prism which is necessary with its base inwards to produce fusion, is the measure of the insufficiency.

FIG. 155.

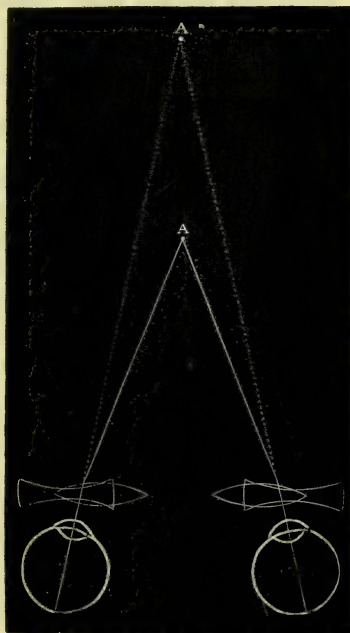


Treatment.—In cases of myopia we give such glasses as correct the refraction, and when worn constantly these frequently succeed in relieving the asthenopia; when such is not the case weak prisms bases inwards, by which we diminish the amount of convergence necessary, often give instant relief. It is sometimes useful to combine the prisms with concave glasses, or by separating the glasses somewhat widely, we may produce the same result. Fig. 156 shows concave spectacles acting also as prisms by being

slightly separated, and convex ones having the same effect when placed so close together that the patient looks through the outer part of the lenses.

When actual divergence of one eye takes place, advancement of the internal rectus with division of its antagonist may be necessary.

FIG. 156.



Reflex Asthenopia.—In addition to these cases of asthenopia occurring with hypermetropia, myopia, and astigmatism, which should be relieved by the glasses which are necessary to correct these errors, and restore the balance of their extra- and intra-ocular muscular systems, everyone will occasionally meet with cases in which no ametropia exists, as proved by placing the patient under atropine and then testing his refraction. *Reflex asthenopia* has been the name given to these cases; they are often exceedingly troublesome, and occur most fre-

quently in young unmarried girls of an hysterical or nervous temperament. If it occur in men, such are usually feeble, hypochondriacal, and nervous. Frequently the only symptom present in addition to the patient's feelings of pain, tension, photophobia, heat, &c., is a certain amount of conjunctival trouble and increased secretion, with a feeling of itching and pricking. Sometimes with the ophthalmoscope, the retinal veins seem rather full, with or without a slight amount of haziness about the edges of the disc. This form of the disorder may be attributed to long hours of working, reading, or writing. I have met with several cases amongst those making gold lace, and no doubt the bright materials here worked with had something to do with the production of asthenopia. Complete abstinence from work does not always bring relief. It seems generally accepted by all authorities on this subject, that in such cases the nervous system is exceedingly sensitive and unstable. Frequently there is disturbance of the uterine organs; when leucorrhœa exists in young unmarried women with troublesome asthenopia, masturbation may be suspected. Irritation of the fifth nerve from carious teeth may also be a cause. The treatment of this reflex form of asthenopia is to endeavour to find out the cause and remove it, with rest for the eyes during certain fixed portions of the day.

CHAPTER XXVI.

SPECTACLES.

HAVING referred to the subject of spectacles, when considering the correction of the different forms of ametropia, I will now briefly recapitulate what was then said, even at the risk of being accused of unnecessary repetition.

Hypermetropia.—So long as $\frac{6}{6}$ can be read with each eye, no glass is necessary for distant vision; for reading, &c., we give such glasses as correct the *manifest* and $\frac{1}{4}$ of the *latent* hypermetropia.

If distant vision be improved by convex glasses then such may be prescribed.

In hypermetropia complicated with strabismus we estimate the total hypermetropia under atropine, then give glasses that correct this within one dioptré; this correction to be worn constantly.

Myopia.—In cases of low degree we may prescribe folders for distance, and allow the patient to read and write without glasses if only he keep a long distance (30 cm.) from his book and suffer no inconvenience. In medium degrees the best results often ensue when the full correction is worn constantly both for near and distant objects.

When the myopia is of high degree, the full correction may be satisfactory for distance, but uncomfortable or impossible for reading, owing to the accommodation being insufficient; such glasses also have the disadvantage of diminishing the size of objects; here we give two pairs of spectacles, one for distance and a weaker pair for reading.

Astigmatism.—Our object is to give as near as possible the full correction (found by atropising the patient); these glasses should be worn constantly.

Atropine is seldom necessary in patients over thirty years of age.

Convex glasses render parallel rays which pass through them convergent, they add therefore to the refraction of the dioptric system and are called *positive*.

Concave glasses render parallel rays divergent, they therefore diminish the refraction of the dioptric system and are called *negative*.

Convex glasses add to the quantity of light entering the eye, while concave glasses diminish it.

The size of the image is modified, thus positive glasses bring forward the centre of refraction and so increase the size of the image, while negative glasses carry this centre backwards and so diminish its size.

Glasses may be made of rock crystal (commonly called pebbles) or crown glass. Those made from the former material have the advantage of being harder and are therefore less liable to be scratched than glass; the weight is much the same in both cases; pebbles absorb more heat and unless cut exactly right, are apt to refract unequally; besides it is difficult to get rock crystal free from striæ, so that glasses made from good crown glass are quite equal to the best pebbles and very much cheaper.

The frames may be made of gold or steel. They should fit the face well. The bridge must suit the nose and be of such a height, that each eye looks exactly through the centre of its glass. When worn for myopia or hypermetropia they should not be further from the eye than 13 mm. For presbyopia the person may be allowed to suit his own convenience and comfort, $2\frac{1}{2}$ cm. being an ordinary distance.

Single glasses may occasionally be allowed in low degrees of myopia for looking at distant objects. They have this disadvantage, however, that sometimes one eye is used so entirely, that the sight in the other may deteriorate from want of sufficient use. Folders (pince-nez) may be used in similar cases to the above, and also to read or work with in presbyopia. Spectacles are as a rule to be preferred, since they are more accurately centred and fit better. For distant vision the glasses should be in the same straight line; for near vision they should slightly converge, so as to be exactly at right angles to the visual axes. In addition to concave, convex, and cylindrical glasses, others are sometimes used.

In cases of astigmatism it has hitherto been the custom to order spectacles and not folders, as in the latter it is difficult to be certain that the cylindrical glasses are always in their

proper axis. Messrs. Pickard and Curry have lately brought out an ingenious pince-nez which is free from this objection. The two glasses slide on a horizontal spring, and are so arranged that they fit on the nose very easily and are exceedingly comfortable.

Stenopaic spectacles consist of an opaque screen with a small central aperture, which may be of any shape according to the case, so that all the peripheral rays are cut off, only such as are in the optic axis being allowed to pass through. They can be combined with convex or concave glasses, and are often exceedingly useful in cases of leucoma, nebulæ, irregular astigmatism, myopia, &c., where the vision is much disturbed.

Prismatic spectacles may consist of prisms alone, or they may be in combination with concave or convex lenses. Their use is called for in certain cases of paralysis of muscles, to prevent diplopia; also in some cases of hypermetropia, when they are combined with convex glasses of the strength of 2° or 3° . With their help the patient is able to converge more, and therefore accommodate more, for a given point. Some myopes, who can read well without glasses, suffer from asthenopia, which can be relieved by prisms, bases inwards; because without them, they have to use their convergent power, while their accommodation is at the same time passive.

Pantoscopic glasses, the upper half of these glasses have one focus, the lower half another. Thus a presbyopic person may also be myopic. The upper half of the glass would then be concave for distance, the lower half convex for near work. Painters sometimes find such glasses very useful.

Tinted glasses are sometimes required for diminishing too much light, in cases of irritation or inflammation of the retina; in some cases of photophobia, arising from various causes, as myopia, &c. Where the aim is to relieve the retina without injuring the distinctness of vision, the light blue glasses are the best, as they cut off the orange rays; where the object is to act on the quantity and not the quality of the light, smoke coloured glasses are to be preferred. Tinted glasses sometimes do real harm, as in cases of asthenopia, by increasing the sensitiveness of the retina; they are always somewhat heating to the eyes, in proportion to the amount of rays they absorb. We sometimes combine them with convex or concave glasses.

There are also various forms of *protectors*; those hollowed out like a watch glass so as to fit closely, are to be preferred to those with wire sides called goggles, or those with sides of glass, which have the disadvantage of being too heavy. Workmen wear different sorts of protectors to keep off dust, fragments of stone, &c., which may be made of glass, talc, or other material.

It is sometimes necessary to find out and record the strength of glasses that are being worn; this is easily done. If convex, we take a concave glass out of the trial box, hold it against the glass we are trying, and look through them at a line, *e.g.*, the bar of a window or any similar object; we move the glasses to and fro in front of the eye; if the line remain immovable the neutralization is complete; if it move in the same direction, the concave glass is too strong; if in the opposite direction it is not strong enough.

CASES.

Commence the examination in a systematic manner:

First, notice the general appearance of the patient, then the shape of the head and face. Next the eyes, as to whether they are large and prominent, or small and sunken looking. Listen patiently to the sufferer's complaints, and having submitted to this ordeal, test the acuteness of vision of each eye separately, and afterwards together, writing down the result, remembering always to commence with convex glasses. Then place the near type in the patient's hand, noting the punctum proximum and the punctum remotum. Next pass on to the ophthalmoscope, first applying the "retinoscopic test," then the "indirect examination," and finally the "direct method," first at a distance, and then close to the eye. If any ametropia exists, the advisability of paralysing the accommodation with atropine must be considered.

In order to illustrate this method of examination, I will give a few cases, in addition to those which will be found at the end of the chapter on retinoscopy.

CASE 10. *Hypermetropia*.—E. M.—, a young woman, a bookbinder, *æt.* 17, suffering from *tinea tarsi*, complains that her eyes get very tired at night, so much so, in fact, that she is unable to read for any length of time. Her general appearance is healthy, and nothing special is noticed about her face, except that the eyes are small. The acuteness of vision for both eyes is normal. On placing +1 D. in front of the right eye $\frac{5}{6}$

is seen more distinctly than without, with +2 D. $\frac{6}{8}$ is still read, with +2.5 D. vision is not so good; the same result is obtained with the left eye. +2 D. for each eye, is the strongest convex glass with which $\frac{6}{8}$ can be read, and is therefore the measure of her Hm. We record it thus—

$$\begin{aligned} \text{R.V. } \frac{6}{8} \text{ Hm. } 2 \text{ D.} &= \frac{6}{8}. \\ \text{L.V. } \frac{6}{8} \text{ Hm. } 2 \text{ D.} &= \frac{6}{8}. \end{aligned}$$

On placing the patient in the dark room, and directing her to look at some distant object or at a black wall, so as to relax as much as possible the accommodation; with retinoscopy the shadow we perceive moves slowly against the mirror, we put +2 D. in a spectacle frame, in front of the eye. The shadow is more distinct, and moves more quickly. We try stronger glasses and then find that +3.5 D. is the highest with which we still get a reverse shadow. Both eyes are alike.

Next examine with the ophthalmoscope. By the indirect method the disc becomes smaller on withdrawing the objective from the eye. With the mirror alone at a distance, we see an image of the disc which moves with the observer's head, proving the image to be an erect one. On approaching the eye the disc is not seen well, unless we put in force our own accommodation; with our accommodation suspended, we turn the wheel of the ophthalmoscope so as to bring forward convex glasses, the clearness of the fundus is improved; +3 D. is the strongest convex glass with which the details can be distinctly and clearly seen by myself.

We might be satisfied with this result, assuming 3.5 D. to be the amount of total hypermetropia; but in young people it is much more satisfactory to be able to record once and for all the total hypermetropia beyond doubt. Atropine (grs. iv to $\bar{3}$ j) was therefore ordered, one or two drops to be placed in both eyes three times a day for four days, warning her that she will be unable to see well, and that the pupils will be dilated during their use. We also recommend a shade to be worn to protect the eyes from the light.

On her return she reads only $\frac{6}{80}$ with each eye, and she now requires +5 D. to enable her to read $\frac{6}{8}$. We also find with retinoscopy that +5 D. is the strongest glass with which we get an opposite shadow.

Our patient, therefore, has a total hypermetropia of 5 D., two dioptres of which were manifest and three latent. For work and reading we order her spectacles +3 D. At present she will not require them for distance. About thirty she will probably require her glasses increased to +4 D.; about forty she may be able to bear her full correction, and may then begin to wear them constantly.

We must remember that when atropine has been used, it is necessary to take off 1 D. from the measurements thus found, as before explained.

CASE 11. *Myopia*.—A young man, $\text{æt. } 20$, next presents himself. He has a long intellectual face with prominent nose; the palpebral apertures are wide; and on directing him to look inwards as much as possible, the eyeballs seem elongated in the antero-posterior diameter.

His eyes, he says are excellent, but he is unable to recognise people as well as formerly. We test the acuteness of vision, and find then he reads $\frac{6}{36}$ with each eye. Convex glasses make even that line indistinct. Our patient is probably myopic. We place in his hand the near type, and he reads No. 1, at once and easily. The farthest point at which he can read

it, is 25 cm. ($\frac{1 \cdot 0 \cdot 0}{2 \cdot 5} = 4$ D.) - 4 D. should be the measure of his myopia. We try - 4 D., directing him again to look at the distant type. He reads with each eye $\frac{6}{6}$; we reduce the glass to find the *weakest* with which he reads the same, and with - 3·5 D. he reads it, though hardly so well; with - 3 D. he reads only $\frac{6}{6}$; - 3·5 D. is therefore the measure of his myopia, and we record it thus—

$$\begin{aligned} \text{R.V. } \frac{6}{3 \cdot 6} - 3 \cdot 5 \text{ D.} &= \frac{6}{6}. \\ \text{L.V. } \frac{6}{3 \cdot 6} - 3 \cdot 5 \text{ D.} &= \frac{6}{6}. \end{aligned}$$

If we employ retinoscopy - 3·5 D. is the weakest concave glass with which a reversed shadow is produced.

We next subject the eye to the indirect ophthalmoscopic examination. The image of the disc becomes larger on placing the objective near the eye and gradually withdrawing it, and in addition we see also a slight myopic crescent on the apparent inner side of the disc. From this case, disc No. 1 was drawn (p. 524).

With the direct ophthalmoscope at a distance from the eye, the disc cannot be well seen, because in our case the aerial image will be formed about 25 cm. in front of the patient's eye. To enable us to see this aerial image it is necessary we should be some 30 cm. away from it; so that we should require to be $25 + 30 = 55$ cm. from the observed eye, and at that distance the illumination will be very weak. With the mirror close to the patient's eye the details appear blurred, until we put on a concave glass, by turning the wheel of our refracting ophthalmoscope. The weakest concave glass with which we are able to see the details of the fundus clearly is the measure of the myopia. Thus we have four distinct plans of measuring our case of myopia:

1st. The farthest distance at which the near type is read 25 cm. ($\frac{1 \cdot 0 \cdot 0}{2 \cdot 5} = 4$ D.).

2nd. The *weakest* concave glass which gives the greatest acuteness of vision.

3rd. The *weakest* concave glass with which we get a retinoscopic shadow moving in the opposite direction to the movement of the mirror.

4th. The *weakest* concave glass with which the details of the fundus can be distinctly seen by the direct ophthalmoscopic examination *close* to the eye.

Should any of these results vary much, we should suspect that the myopia is increased by spasm of the accommodation, and we atropise the patient in the manner before described, and at the end of four days go over the ground again, remembering that when atropine has been used, it is necessary to add on about - 5 D. to the glass found, because the ciliary muscle is probably never so completely relaxed as when it is under the influence of atropine.

Having found then that our patient's myopia amounts to - 3·5 D. we give spectacles of that focus for constant use. In addition to ordering spectacles we give him also some very important general directions, he must always hold his book or work 35 cm. away, bring the work to his eyes, and not his eyes to the work; writing should be done at a sloping desk; he should sit with his back to the window so that the light comes over his left shoulder on to his work, and do as little near work as possible by artificial light.

CASE 12. *Hypermetropia and Presbyopia.*—A gentleman, *æt.* 56, comes with the complaint that he cannot see to read as comfortably as formerly, though he sees distant objects well. We try his acuteness of vision and find that he reads $\frac{6}{6}$ badly. With + 1 D. he sees much better, reading some of the letters of $\frac{6}{6}$. We then try 1.5 D. and these he rejects. Hence we conclude that he has Hm. 1 D. We know from his age that he will also be presbyopic 3 D. and we add on to this, + 1 D. for hypermetropia, directing him to read the newspaper with + 4 D. for half an hour. He thinks these rather strong for him, as they make his eyes ache. With + 3.5 D. he feels quite comfortable, and we therefore give him + 3.5 D., telling him that he will require them changed for slightly stronger ones in about five years.

CASE 13. *Paralysis of the Accommodation.*—Kate L—, *æt.* 12, has been very ill from diphtheria, but is now much better. She complains that she is unable to read or work, though able to see distant objects well. The pupils are very large and act badly to light. Hence we suspect paralysis of the accommodation. We test her acuteness of vision, and she sees $\frac{6}{6}$ with each eye. We try convex glasses .5 D. and she still reads $\frac{6}{6}$, but 1 D. she rejects. Our diagnosis is therefore confirmed. We next find the weakest glass with which she is able to read, *weakest* because we are anxious to encourage the ciliary muscle to act, since by replacing it entirely we should prolong the patient's recovery.

The glasses must be changed for weaker ones as the ciliary muscle recovers tone.

We saw that she had a slight amount of hypermetropia and also that there was some accommodation left, enough at least to correct this, otherwise she could not have read $\frac{6}{6}$ without + .5. A tonic containing iron and strychnine was also prescribed.

CASE 14. *Anisometropia.*—A young woman, *æt.* 20, has never seen well, either at a distance or near at hand, has tried spectacles of all sorts, but never been able to find any that suited her. The eyes look somewhat irritable, but there is nothing conspicuous about their size or shape. There is some want of symmetry about the face, the nose being deviated from the median line slightly to the left.

We first try the acuteness of vision of the right eye. She reads $\frac{6}{1\frac{1}{2}}$ and with + 1 D. vision is somewhat improved; with + 1.5 D. it is made worse. Still armed with + 1 D. we direct the patient to look at the fan of radiating lines (Fig. 539). She sees plainly the horizontal lines, whilst all the others are more or less indistinct, the vertical line most so; still looking at the horizontal line, we alternately hold in front of + 1 D. which is before the eye under examination, + .25 D. which makes it worse, then — .25 D. which she says at once makes it perfectly clear and distinct. We, therefore, put down + .75 as the correction for the vertical meridian, and pass on to the horizontal. Our patient is directed to look steadily at the vertical line. We try convex glasses, which improve it, + 3 D. making it quite clear; a stronger glass than this renders it slightly indistinct. It is evident, therefore, that her horizontal meridian is hypermetropic + 3 D. We put up the correction found, + .75 D. sp., + 2.25 D. cylinder axis vertical, and direct her again to look at the distant type, $\frac{6}{6}$ is read, though with some difficulty. This result is not, however, reliable, and we proceed to confirm it by retinoscopy, obtaining + 2 D. for the vertical, and

+ 4 D. for the horizontal meridians. On trying this correction, however, the vision is not so good. We now test the acuteness of vision in the left eye. She sees $\frac{6}{36}$, and neither convex nor concave glasses improve it. On looking at the fan of radiating lines all seem indistinct, and having thus far no data to go upon, we, instead of wasting time, at once pass on to retinoscopy. We get oblique shadows, the horizontal moving with the mirror and the vertical against it; here then is a case of mixed astigmatism. We find out that - 2 D. is the weakest concave glass with which we get a reverse shadow horizontally, and + 3 D. the strongest convex with which an opposite shadow is still obtained in the vertical meridian, the degree of obliquity being about 25° . This result is noted down thus—

$$\text{L. } \left. \begin{array}{l} \diagup \\ \diagdown \end{array} \right\} 25^\circ \begin{array}{l} + 3 \text{ D.} \\ - 2 \text{ D.} \end{array}$$

We, therefore, place in a spectacle frame + 3 D. spherical combined with - 5 D. cylinder, axis deviating outwards from the vertical 25° . With this correction the patient at once reads $\frac{6}{18}$. We are not to be satisfied with this result, but give the patient a solution of atropine grs. iv to \mathfrak{z} j with directions to come again in four days. At the end of that time she returns, and we find with retinoscopy—

$$\text{R.} \left| \begin{array}{l} + 2.5. \\ - + 4.5 \text{ D.} \end{array} \right. \quad \text{L. } \left. \begin{array}{l} \diagup \\ \diagdown \end{array} \right\} \begin{array}{l} + 3.5 \text{ D.} \\ - 2 \text{ D.} \end{array}$$

The right eye with this correction reads $\frac{6}{6}$ and the left also $\frac{6}{6}$. This result is very satisfactory. We now allow the patient to recover from atropine, and at the end of a week confirm the result before ordering spectacles. Then for the right eye the best vision was obtained with + 1.5 sp. \odot + 2 D. cy. axis vertical ($\frac{6}{6}$); and for the left + 3 D. spherical \odot - 5 D. cylin. axis 20° from the vertical ($\frac{6}{6}$). These spectacles were therefore ordered, and the patient directed to wear them constantly.

CASE 15. *Anisometropia*.—Jane W—, æt. 30, presents herself complaining that the sight in her left eye has been gradually getting dim for some months. She is a small, healthy-looking woman, with nothing characteristic in her appearance. We test the acuteness of vision—

Right $\frac{6}{6}$ Hm. 1 D. = $\frac{6}{6}$.

Left $\frac{6}{18}$, not improved with spherical glasses.

We try retinoscopy, but the pupils are so small that the result is not very satisfactory. We are, however, able to make out in the left eye a reverse shadow in the horizontal meridian, which + 2 D. over-corrects, + 1.5 D. being the highest glass with which we get an opposite shadow; the vertical meridian appears emmetropic. There is, therefore, no doubt that the defective vision in this eye is due to astigmatism. The patient complains that the examination has made her eyes ache, so we do not proceed further, but order a solution of hydrobromate of homatropine (2 grs. to the \mathfrak{z} j) to be used every two hours and direct her to come again on the following day. Then the result with retinoscopy is—

$$\begin{array}{r} \text{R.} + 1\cdot5 \text{ D.} \\ \text{L.} - \left| \begin{array}{l} + \cdot 5 \text{ D.} \\ + 2 \text{ D.} \end{array} \right. \end{array}$$

We try this at the test type.

$$\begin{array}{l} \text{R.} \cdot \frac{6}{24} + 1\cdot5 \text{ D.} = \frac{6}{6}. \\ \text{L.} \cdot \frac{6}{36} + \frac{\cdot 5 \text{ D. sp.}}{1\cdot5 \text{ D. cy. axis vert.}} = \frac{6}{6}. \end{array}$$

We make a slight deduction from the sphere in each case for the homotropine and order for constant use:—

$$\begin{array}{l} \text{R.} + 1 \text{ D. sph.} \\ \text{L.} + 1\cdot5 \text{ D. cy. axis vert.} \end{array}$$

CASE 16. *Presbyopia*.—John G——, æt. 50, has always enjoyed good sight, he still sees distant objects well, but finds some difficulty in reading, especially during the evenings.

$$\begin{array}{l} \text{R.V.} \frac{6}{6}, \text{ no Hm.} \\ \text{L.V.} \frac{6}{6}, \text{ no Hm.} \end{array}$$

We try him with + 2 D. for reading, and with these he sees perfectly; this, therefore, is a simple case of presbyopia, requiring a pair of folders + 2 D. for reading, writing, &c.

CASE 17. *Hypermetropia and Presbyopia*.—Mr. K——, æt. 60, sees badly both near and distant objects, he wears + 4 D. for reading, but they are not comfortable.

$$\begin{array}{l} \text{R.V.} \frac{6}{36} \text{ Hm. } 3 \text{ D.} = \frac{6}{9}. \\ \text{L.V.} \frac{6}{36} \text{ Hm. } 3 \text{ D.} = \frac{6}{9}. \end{array}$$

He therefore requires + 3 D. for distance, and to find the glass he will require for reading, it is necessary to add on to this distance glass the glass he would require for presbyopia if he were an emmetrope, viz., + 4 D. We therefore try him with + 7 D., but these make his eyes ache, we next try + 6·5 D., and with these he sees comfortably.

This patient then requires two pairs of spectacles—

$$\begin{array}{l} + 3 \text{ D. for distance.} \\ + 6\cdot5 \text{ D. for reading, \&c.} \end{array}$$

CASE 18. *Myopia and Presbyopia*.—Mrs. C——, æt. 55, complains that her eyes become tired at night; she has tried several pairs of spectacles, but without finding any that exactly suit her.

$$\begin{array}{l} \text{R.V.} \frac{6}{36} - 2 \text{ D.} = \frac{6}{9}. \\ \text{L.V.} \frac{6}{36} - 2 \text{ D.} = \frac{6}{9}. \end{array}$$

Our patient requires, therefore, this correction for distance, but she also wants glasses for reading and near work; an emmetrope of 55 requires presbyopic glasses + 3 D., she is, however, a myope of 2 D., so we have to deduct this from the presbyopic glass (3 D. - 2 D. = 1 D.) and try the + 1 D. for reading. With these she is able to read the smallest type comfortably, we therefore prescribe two pairs of spectacles—

$$\begin{aligned} & -2 \text{ D. for distance.} \\ & - +1 \text{ D. for reading.} \end{aligned}$$

CASE 19. *Myopia*.—Annie C——, æt. 9, was brought because she was unable to see the black-board at school.

$$\begin{aligned} \text{R.V. } \frac{6}{24} - 3.5 \text{ D.} &= \frac{6}{9}. \\ \text{L.V. } \frac{6}{24} - 2.5 \text{ D.} &= \frac{6}{9}. \end{aligned}$$

After using atropine—

$$\begin{aligned} \text{R.V. } \frac{6}{36} - 3 \text{ D.} &= \frac{6}{9}. \\ \text{L.V. } \frac{6}{24} - 2 \text{ D.} &= \frac{6}{9}. \end{aligned}$$

Ordered spectacles for distance R. - 3 D., L. - 2 D., with directions to present herself again in six months, when, should the myopia have increased, or if the child complain of asthenopia, it may be necessary to prescribe spectacles for constant use.

CASE 20. *Simple Myopic Astigmatism*.—Thomas J——, æt. 20, sees rather badly both near and distant objects.

$$\begin{aligned} \text{R.V. } \frac{6}{12}, \text{ not improved with glasses; with pin-hole} &= \frac{6}{9}. \\ \text{L.V. } \frac{6}{12}, \text{ not improved with glasses; with pin-hole} &= \frac{6}{9}. \end{aligned}$$

After atropine had been used for four days retinoscopy gave—

$$\begin{array}{cc} \begin{array}{c} | \\ \text{R.} \text{-----} \\ | \end{array} & +1 \text{ D.} \\ \text{Em.} & \\ \text{R. } +1 \text{ D. cy. axis horiz.} &= \frac{6}{9}. \\ \text{L. } +1 \text{ D. cy. axis horiz.} &= \frac{6}{9}. \end{array}$$

After the atropine has passed off—

$$\begin{aligned} \text{R. } -1 \text{ D. cy. axis vert.} &= \frac{6}{9}. \\ \text{L. } -1 \text{ D. cy. axis vert.} &= \frac{6}{9}. \end{aligned}$$

This correction was given for constant use.

CASE 21. *Compound Myopic Astigmatism*.—Miss N——, æt. 13, has seemed short-sighted for the last year or two. Mother and father both have good sight.

$$\begin{aligned} \text{R.V. } \frac{3}{60} - 9 \text{ D.} &= \frac{6}{24}. \\ \text{L.V. } \frac{3}{60} - 9 \text{ D.} &= \frac{6}{24}. \end{aligned}$$

The pupils are large, so that retinoscopy can be easily carried out.

$$\begin{array}{r}
 \text{R.} \left| \begin{array}{l} -10 \text{ D.} \\ \hline -6 \text{ D.} \end{array} \right. \qquad \text{L.} \left| \begin{array}{l} -10 \text{ D.} \\ \hline -7 \text{ D.} \end{array} \right. \\
 \\
 \text{R.V.} \frac{-6 \text{ D. sp.}}{-4 \text{ D. cy. axis horiz.}} = \frac{6}{18} \text{ and 2 letters of } \frac{6}{12}. \\
 \text{L.V.} \frac{-7 \text{ D. sp.}}{-3 \text{ D. cy. axis horiz.}} = \frac{6}{12}.
 \end{array}$$

On examination of the eyes with the ophthalmoscope the choroid is found to be exceedingly thin, there is a large crescent in both eyes and in the right three or four patches of choroiditis, with one hæmorrhage near the macula.

The patient was ordered the full correction for distance, and advised to do no reading, writing, or near work for six months, then to return for inspection; she was also recommended to spend as much of her time as possible in the open air, and a mixture containing syrup of the iodide of iron was prescribed.

CASE 22. *Concomitant Squint*.—George W——, æt. 5, has squinted inwards for the last three months. On covering the non-squinting eye and directing the little boy to look at the finger held a short distance from him, the deviating eye immediately righted itself and fixed the finger, the covered eye at the same time turning in. We prescribe a solution of atropine to be applied to both eyes, and at the end of a week the patient is brought back; the squint is now much less apparent, and with retinoscopy we find 3.5 D. of hypermetropia in each eye. The direct examination gives the same result. We order our patient spectacles + 2.5 D. to be worn constantly.

CASE 23. *Aphakia*.—Thomas B——, æt. 50, gamekeeper. Had the right lens removed for cataract nine months ago, and last week the opaque capsule remaining was needled.

R. V. \bar{c} + 11 D. = $\frac{6}{9}$ and with + 14 D. No. 1 of the near type was read with comfort, the patient was therefore ordered the following spectacles—

$$\begin{array}{l}
 + 11 \text{ D. for distance.} \\
 + 14 \text{ D. for near work.}
 \end{array}$$

These were arranged in a reversible frame, so that either glass could be brought in front of the right eye as occasion required.

APPENDIX.

IN the metrical system the unit of length is a metre, equal to 100 centimetres, 1000 millimetres or 40 English inches, so that 1 inch is equal to $2\frac{1}{2}$ centimetres, a lens of 1-metre focus is called a dioptré, a lens of $\frac{1}{2}$ a metre (50 cm.) is 2 D., $\frac{1}{10}$ of a metre (10 cm.) 10 D., &c.

In the old system the lenses were numbered according to their focal length in inches, a lens of 1-inch focus being the unit; a lens of 2-inch focus was expressed by the fraction $\frac{1}{2}$, one of 10-inch focus $\frac{1}{10}$, and so on. If we wish to convert a dioptric measurement into the corresponding inch measurement of the old system, we have only to remember that the unit 1 metre = 40 English inches, so that a glass of 1 D. = $\frac{1}{40}$ in the old system, 2 D. = $\frac{2}{40} = \frac{1}{20}$, 5 D. = $\frac{5}{40} = \frac{1}{8}$, and so on.

The table on the next page gives approximately the equivalent of each dioptré or part of a dioptré in English and French inches and in centimetres.

Dioptres.	English inches.	French inches.	Centimetres.
·25	160	146	400
·50	80	73	200
·75	52	50	130
1·	40	36	100
1·25	31	29	77
1·50	26	24	65
1·75	22	21	55
2·	20	18	50
2·25	17	16	43
2·50	16	15	40
2·75	14	13	35
3·	13	12	33
3·50	11	10	27
4·	10	9	25
4·50	9	8	22
5·	8	7	20
5·50	7	6½	17
6·	6½	6	16
7·	6	5	15
8·	5	4½	12½
9·	4½	4	11
10·	4	3½	10
11·	3½	3¼	9
12·	3¼	3	8
13·	3	2¾	7½
14·	2¾	2½	7
15·	2½	2¼	6½
16·	2¼	2⅛	6
18·	2⅛	2	5½
20·	2	1¾	5

Regulations for Candidates for Commissions in the Army.

A candidate must be able to read at least $\frac{6}{36}$ with each eye, without glasses, and this must be capable of correction with glasses up to $\frac{6}{6}$ in one eye and $\frac{6}{12}$ in the other, he must also be able to read No. 1 of the near type with one or both eyes.

Squint, colour blindness, or any serious disease of the eye renders the candidate ineligible.

Navy.

A candidate must be able to read $\frac{6}{6}$ with each eye, and the near type at the distance for which it is marked.

Colour blindness, squint, or any serious disease of the eye disqualifies.

Indian Civil Service.

A candidate must be able to read $\frac{6}{9}$ with one eye and $\frac{6}{6}$ with the other, with or without correcting lenses.

Any disease of the fundus disqualifies. Myopia, however, with a posterior staphyloma may be passed, if the ametropia do not exceed 2.5 D., and the candidate has a visual acuteness equal to that stated above.

Indian Medical Service.

The candidate must have a visual acuteness of $\frac{6}{6}$ in one eye and $\frac{6}{12}$ in the other. Hypermetropia and myopia must not exceed 5 D., and then with the proper correction must come up to the above standard.

Astigmatism does not disqualify a candidate, provided the combined spherical and cylindrical glass does not exceed 5 D., and the visual acuteness equals $\frac{6}{6}$ in one eye and $\frac{6}{12}$ in the other; colour blindness, ocular paralysis, or any disease of the fundus renders the candidate ineligible.

TEST TYPES.

33 cm.*

No. 1.

A dull grey sky, hills and trees, and meadow banks and boats deepening down into undistinguishable masses in neutral tint; the river like another grey sky—as smooth and unruffled, save when boats are plashing about. Down by the lock yonder a bonfire is shooting up a ruddy glare into the dusk gathering about the wooded hill in the background, and white bell tents are dotted here and there in the valley, cold and spectral, or all aglow with lights within. Up under the willows, weird-looking figures are rigging up awnings over boats, in which they are going to sleep for the night, and in many of which brilliant lights are bringing brawny

50 cm.

No. 2.

oarsmen into bold relief against the black shadows in the trees behind. Just above the bridge acres of small boats lie slumbering along the towing-path, the water softly plashing a lullaby beneath them. Lower down, far as the eye can reach, lights are twinkling and flashing in countless multitudes, and sounds of music, softened by distance, come tiukling over the gleaming river. It is ten o'clock and past, and the great throng of holiday-makers has for the most part dispersed apparently; but with the fading out of daylight there has gradually

60 cm.

No. 3.

beamed out upon the river, a scene which, if it were to be enjoyed only in Venice, and once every five years, would draw spectators from all the ends of the earth. One side of the river is seemingly all but deserted, and lies hidden in darkness as profound as darkness can be in the height of summer, with nothing but a thin curtain of clouds spread out beneath a nearly full moon. But the side of the river opposite to the towing-

90 cm.

No. 4.

path is one long line of sparkling light, while over the dark glistening river seemingly hundreds of boats are paddling about, many of them decked out with Chinese lanterns and riding lights at their tiny mast-heads. The brilliancy and vivacity of the scene, combined with its quietude and placidity, is difficult to describe, without appearing to

* The number indicates the distance at which the type should be seen by a normal eye.

1 m.

No. 5.

indulge in somewhat extravagant language. Henley Regatta seems to be year by year growing in popular favour—unfortunately, no doubt, many will think—and the line of house-boats which a few seasons ago extended no great distance down below the winning flag and the

1·5 m.

No. 6.

grand stand may be said now to reach right down the course of a mile and a quarter or so. By day these house-boats are exceedingly gay and pleasant looking, with their coloured awnings, their profusion of brilliant bunting,

1·8 m.

No. 7.

their extemporised flower gardens, the brightly-coloured boating costumes of the men, and the gay dresses of the ladies. Until quite a recent period the display by day was thought

2 m.

No. 8.

to be sufficient, but one or two boats began the fashion of illuminating after dark, and it has now become quite

3 m.

No. 9.

correct to light up.
Small boats followed

5 m.

No. 10.

in the wake,
the brilliant

6 m.

No. 11.

Z E D A O P

12 m.

No. 12.

B A E

18 m.

No. 13.

V E N

24 m.

No. 14.

D E


36 m.

No. 15.

N

60 m.

No. 16.



PRAY'S TEST TYPES FOR ASTIGMATISM.

Horizontal.



15°.



30°.



45°.



60°.



75°.



90°.



105°.



120°.



135°.



150°.



165°.



INDEX.

		A.	PAGE
Abducting prism		455
Abrasion of cornea		156
Abscess of cornea		132
" eyelids		28
" frontal sinus		381
" inner angle of eye		74
" lachrymal sac		68
" orbit		369
Abscission		145
Absorption, cure of cataract by		342
Accommodation		446
" absolute		451
" amplitude		449
" at different ages		452
" binocular		452
" diminution of		444
" of emmetropes		450
" of hypermetropes		450
" of myopes		450
" paralysis of		554
" produced by		554
" range of		449
" relative		451
" spasm of		555
Accommodative asthenopia		557
Acquired hypermetropia		552
Acuteness of vision		461
" hypermetropia		509
" myopia		524
" astigmatism		536
Adducting prism		455
Advancement operation		418
Aërial image		470
Albuminuria in retinitis		286
Alcoholism, a cause of amblyopia		325
Alternating strabismus		407

	PAGE
Amaurosis	323
Amblyopia	323
" colour blindness in	306
" from hæmorrhage.. .. .	324
" from disease of the brain.. .. .	324
" from over-suckling	325
" diabetes, and lead poisoning	325
" from uræmic poisoning	325
" tobacco, quinine, alcohol	325
" general considerations	324
" prognosis and causes of	325
Ametropia	442
Amplitude of accommodation	449
" convergence	456
Anæsthesia of the cornea (in glaucoma)	279
Anatomy of angle of anterior chamber	269
" canal of Petit	271
" capsule of Tenon	273
" conjunctiva	75
" choroid	214
" ciliary muscle	205
" cornea	120
" the iris	174
" lens	329
" lymphatic system	271
" muscles of eye	389
" nerves of cornea	121
" retina	283
" sclerotic	166
" tunica vasculosa	215
" vitreous humour.. .. .	235
Aneurism by anastomosis (orbital)	378
" of ophthalmic artery	378
Angle α	405
" γ	405
" metrical, of convergence	453
" of deviation	455
" of strabismus	408
" principal	429
" visual	445
Anisometropia	547, 444
" treatment of	547
Anterior focal point	441
" focus	441
Aphakia.. .. .	513
" test for	513
" treatment of	513
Apoplexy of the retina	293
Apparent strabismus	404
Arcus senilis	162
Argyll-Robertson pupil	5

	PAGE
Army, regulations for	576
Artery, central of retina, appearances of	21
Artificial eyes, adaption of	386
" pupil	198, 201
" " by excision	201
" " iridectomy	201
" " Tyrrell's hook	200
" " in zonular cataract	200
" " state of eye requiring	198
Asthenopia	556
" accommodative	557
" muscular	559
" reflex	561
Astigmatism	530
" causes of	535
" compound hypermetropic	533
" " myopic	533
" estimation of	537
" irregular	530
" mixed	533
" principal meridians in	531
" regular	531
" shape of disc in	539
" simple hypermetropic	533
" simple myopic	533
" symptoms of	536
" treatment of	542
Astigmatic clock-face	538
Asymmetry of cornea	530
Atrophy of optic disc	264
" " " tabetic	266
" " " excavation in	265
" retina	291
Atropine in iritis	183
" in retinoscopy	481
" in ulcers of cornea	128
" counter-indicated in glaucoma	277
" " granular lids	103
Axial line in hypermetropia	506
" " myopia	518
Axis, optic	406, 440
" principal	429
" secondary	434
" visual	406
B.	
Bandages in extraction	349
" keratitis	125
Belladonna, use of, in iritis	184

	PAGE
Biconcave lenses	431
Biconvex	431
Binocular accommodation	452
" vision	392
Blepharitis	28
Blepharospasm, clonic.. .. .	59
" tonic	59
Blood effused into choroid	227
" " conjunctiva	364
" " eyelids	26
" " retina	293
" " vitreous	240
Blows inflicted on the cornea	156
" " " eyelids.. .. .	26
" " " sclerotic	172

C.

Calcareous concretions in canaliculus	67
" " choroid	233
Calomel in pustular conjunctivitis	109
Canaliculi, stricture of.. .. .	67
Capsule of lens in capsular cataract	333
" " inflammation of	371
Cardinal points	440
Carcinoma of lachrymal gland	64
Caries of orbit	368
Cases, retinoscopy	498
" others	566
Cataract.. .. .	330
" anæsthetics in extraction	338
" black	335
" capsular	331
" causes of	331
" cortical	332
" diagnosis of forms of	331
" extent of lens involved	335
" extraction of, iridectomy in	345
" " accidents in	337
" " after treatment	369
" " iritis	352
" " keratitis following	351
" " prolapse of iris	349
" glasses.. .. .	513
" Liebreich's operation for	355
" linear extraction of	347
" " " Bowman and Critchett's traction " " " operation	355
" " " Von Graefe's	347
" " " without excision of iris	339

	PAGE
Cataract, posterior polar	334
" removal of, in capsule	356
" selection of operation	339
" senile	331
" soft	331
" solution of	342
" suction operation for	343
" traumatic	333
" treatment after operation	349
" zonular	333
Catarrhal conjunctivitis	76
Cellulitis of orbit	369
Centre of motion of the eye	441
" optical	441
Chalazion of eyelids	37
Chemosis of conjunctiva	79
Cholesterine in the vitreous	240
Choroid, thinning of, in myopia	524
" anatomy of	23, 214
" coloboma of	223
" detachment of	228
" extravasation of blood into	227
" hæmorrhage from	227
" hexagonal cells of	284
" injuries of	226
" ossification of	233
" sarcoma of	225
" suppuration of	223
" sympathetic irritation of	210
" tubercle of	225
" tumours of	225
" wounds of	226
Choroiditis, central	219
" disseminata	219
" myopic	220
" senile	220
" serous, acute	220
" specific	219
" suppurative	223
Chrom-hydrosis	35
Cicatrices of the conjunctiva	111
" " eyelids	27
Cilia, inversion of	49
" removal of	50
Ciliary body	205
" muscle, function of	447
" " in hypermetropia	507
" " in myopia	523
Civil Service, regulations for	576
Colloid disease of elastic lamina	234
Colour blindness	10, 306

	PAGE
Colour division	7
Colour sense	10
Compound hypermetropic astigmatism	533
" myopic astigmatism	533
" system, points of	440
Concave lenses	431
" mirror in retinoscopy	489
Concomitant squint	407
Condylomata of the iris	193
Conical cornea	153
Conjugate focus	433
Conjunctiva, chemosis of	79
" cicatrices of	111
" diseases of	76
" foreign bodies adhering to	110
" granular bodies in	44
" hyperæmia of	76
" injuries of	110
" serous effusion into	79, 116
" structure of	75
" tumours of	118
" warts of	118
Conjunctivitis	76
" diphtheritic	90
" exanthematous	109
" granular	94
" muco-purulent	79
" pustular	107
" tubercular	106
Convergence	452
" amplitude of	456
" insufficiency of	559
" metrical angle	453
" punctum proximum of	453
" punctum remotum of	455
" range of	455
" relative	458
Convergent strabismus	409
Convex lenses	431
Corelysis	197
Cornea, abrasions of	156
" abscess of	132
" anæsthesia of (in glaucoma).. .. .	279
" anatomy of	120
" conical.. .. .	153
" contusion of	156
" degeneration of	162
" fistula of	145
" foreign substance on	159
" " " imbedded in	159
" hernia of	141

	PAGE
Cornea, herpes of	138
" image formed on	447
" inflammation of	122
" injuries of	156
" leprous affections of	164
" nerve lesion of	136
" opacities of	138, 147
" " chemical	165
" " earthy matter	149
" pannus.. .. .	150
" paracentesis of	134, 143
" perforation of	160
" peritomy	152
" specks or opacities of	147
" staphyloma of	142, 168
" tattooing	149
" ulcers of	138
" " from injury to nerves.	136
" vascular	138
" wounds of	156
Corneitis (see keratitis)	122
Crab lice on eyelashes.. .. .	31
Crescent, myopic	523
Crystalline lens, anatomy of	329
" " diseases of	329
Cyclitis	205
Cylindrical glasses	437
" lenses	437
Cysticercus in iris	193
" vitreous	242
Cysts in conjunctiva	118
" eyelids	36
" iris	192
" orbit	374

D.

Dacryops	64
Daltonism (colour blindness).. .. .	10, 306
Descemet's membrane	4
Detachment of retina	298
" " in myopia	298
Deviation, angle of	455
" primary	406
" secondary	406
Diabetes a cause of cataract	331
Dilatation of pupil, mechanism of	194
Dioptre	445
Dioptric system	445

	PAGE
Diplopia, crossed	391
" direct	392
Direct ophthalmoscopic, examination	473
Disc, Placido's	546
" shape of, in astigmatism	539
Dislocation of eyeball	384
" lens	361
Distant type	462
Divergent strabismus	413
Divergence, appearance of	404
Donders	549, 557
Duct lachrymal, stricture of	65
" nasal, obliteration of	75

E.

Ectropion	43
Elasticity of capsule	447
" of lens	447
" " diminution with age	549
Electricity in paralysis of ocular muscles	403
Elongation of eyeball in myopia	518
Embolism of retinal artery	296
Emergent ray	427
Emmetropia	442
" punctum proximum in	448
" punctum remotum in	448
Encysted tumours of eyelids	36
" " orbit	374
Entozoa in the iris	193
" " vitreous	242
Entropion	39
Epiphora	66
Episcleritis	167
Epithelioma of eyelids	32
Erect image	17
Erysipelas of eyelids	31
Eserine	415
" in glaucoma	280
" in mydriasis	194
Evacuation of aqueous	140
Evisceration	387
Examination of the eye	1
" " colour sight	10, 306
" " compare the eyes	1
" " retinoscopy	18
" " lateral method of	18
" " lids	1
" " with ophthalmoscope	12
" " cornea	4

	PAGE
Examination of the iris	5
" " lachrymal apparatus	2
" " tension of globe	23
" " test types	462
" " visual field	7
Exercises, orthoptic	416
Exophthalmia	372
Exophthalmic goitre	372
Eye	440
" refracting media	440
" " surfaces of	440
Eyeball, rupture of	172
" dislocation of	384
" extirpation of	385
" sarcoma of	375
" tension of	23
Eyelashes, eversion of	43
" inversion of	39
" removal of	40
Eyelids, abscess of	28
" anatomy of	25
" aneurism by anastomosis of	39
" burns of	27
" contusion	26
" encysted tumours of	36
" epithelial cancer of	32
" erysipelas of	31
" eversion of	43
" herpes of	34
" inflammation of	28
" inversion of	39
" miliun of	36
" nævi	38
" œdema of	27
" paralysis of	54
" phlegmon of	31
" rodent ulcer	33
" sebaceous tumours	36
" spasm of	58
" syphilitic ulceration of	31
" tumours of	37
" union of	54
" warts of	36
" wounds of	26

F.

Face, asymmetry of, in astigmatism	536
Far point (see punctum remotum)	448
Fistula of cornea	145

	PAGE
Fistula of lachrymal gland	64
" sac	69
Focal illumination	18
" length	446
" interval	532
" anterior, points	441
Focus, conjugate	433
" principal.. .. .	433
" virtual	437
Foreign bodies in aqueous chamber	161
" " conjunctiva	2
" " cornea	159
" " iris	189
" " orbit	364
" " vitreous	242
Form sense	6
Formation of images	435
Fracture of walls of orbit	364
Frontal sinus, distension of	381
Fundus of healthy eye, appearance of	19
G.	
Gland, lachrymal, diseases of.. .. .	62
" " excision of.. .. .	65
Glasses	563
" biconcave	431
" biconvex	431
" concave	431, 464
" convex	431, 464
" cylindrical	437
" orthoscopic	553
" pantoscopic	565
" prismatic	565
" spherical	445
" stenopaic	565
" tinted	565
Glaucoma	269
" consecutive	275
" eserine in	280
" inflammatory	276
" iridectomy	280
" pathology	275
" sclerotomy in	281
" simplex	279
" symptoms of	278
" treatment of	280
Glioma of retina	303
Goggles	566
Granular lids	94
Grooving tarsal cartilage	53
Gunshot wounds of orbit	365

H.

PAGE

Hæmorrhage from retinal vessels	293
Hemeralopia	316
Hemiopia	320
Hereditary, tendency in hypermetropia	507
" tendency in myopia	521
Hernia of cornea	141
Herpes zoster of eyelids	34
Homonymous images	392
Hordeolum	28
Hyalitis	237
Hydatids in iris	193
" orbit	395
Hyperæmia of conjunctiva	76
" iris	175
" optic papilla	248
" retina	285
Hypermetropia	503
" absolute	506
" acquired	552
" amount of	509
" angle α in	507
" axial	506
" causes of	506
" estimation of	509
" facultative	506
" latent	505
" length of eyeball in	506
" manifest	505
" relative	506
" spectacles for	511
" symptoms of	508
" tests for	509
" treatment for	511
Hypermetropic astigmatism, simple	533
" " compound	533

I.

Images, crossed	392
" formation of	435
" homonymous	392
" in emmetropia	441
" on cornea	447
" on lens	447
" projected	437
" real	436
" virtual	436
Indirect ophthalmoscopic examination	15

	PAGE
Injuries of choroid	226
" conjunctiva	110
" cornea	156
" crystalline lens	361
" eyebrow and eyelids	364
" iris	188
" orbit	364
" retina	298
" vitreous	242
Insufficiency of convergence	559
" " test for	561
Intermittent strabismus	407
Internal recti	389
Interval of Sturm	532
" focal	532
Inversion of images by lenses	436
" " by the eye	441
Iris in accommodation	447
" anatomy of	174
" coloboma of	191
" cysticercus of	193
" detachment of	190
" examination of	5
" foreign bodies in	189
" functional diseases of	194
" hyperæmia of	175
" in hypermetropia	507
" injuries of	188
" leprous affections of	193
" prolapse of	190
" staphyloma of	142
" tumours of	192
Iritis	176
" gonorrhœal	180
" iridectomy in	198
" parenchymatous	180
" plastic	178
" symptoms common to all forms of	176
" tubercular	182
" treatment of	184
Irregular astigmatism	530
Ischæmia of retina	286

J.

Jackson, Dr.	494
Jaeger, test type	465
Javal and Schlötz ophthalmometer	542

K.

	PAGE
Keratitis	122
" interstitial	125
" phlyctenular	126
" punctata	4, 181
" rheumatic	129
" suppurative, acute	132
" " subacute	134
" syphilitic	125

L.

Lachrymal apparatus, examination of	2, 62
" canaliculus, stricture of	67
" cysts	64
" fistula	64
" gland	62
" " extirpation of	65
" " hypertrophy of	63
" " inflammation of	62
" " scirrhous of	64
" " sac, abscess of	68
" " " fistula of	69
" " " inflammation of	68
" " " mucocele of	72
" " " obliteration of	71
" " " polypus of	73
Lamina vitrea of choroid	215
Landolt	456
Latent hypermetropia	505
Length, focal	446
" of eyeball	441
" in hypermetropia	506
" in myopia	518
Lens, crystalline, anatomy of	329
" " diseases of	330
" " dislocation of	361
" " in accommodation	447
" " suspensory ligament of	447
Lenses	430, 563
" biconcave	431
" biconvex	431
" concave	431, 464
" converging	431
" convex	431, 464
" cylindrical	437
" decentred	561
" diverging	431

	PAGE
Lenses, foci of	433
„ images, formed by	435
„ influence of, on the size of the image	564
„ orthoscopic	553
„ principal focus	433
„ prismatic	565
„ refraction by	432
„ spherical	445
„ table for presbyopia	551
Leucoma	147
Light sense	11
Long sight (<i>see</i> hypermetropia)	503

M.

Macula lutea	22, 462
Manifest hypermetropia	505
Maxillary sinus, pressure on orbit from	383
Medium, refraction by	428
Meibomian glands, apertures of	25
„ cysts	37
Meniscus	431
Mercury in iritis	184
Metrical angle	453
„ system of lenses	445
Micropsia	327
Microphthalmos	507
Milium of eyelids	36
Mirror, concave for retinoscopy	489
„ plane	494
„ reflection by a plane	424
„ „ from a concave	430
„ „ from a convex	429
Mixed astigmatism	533
Monocular vision in myopia	523
Monolateral strabismus	407
Movements of mirror in retinoscopy	487
Mucocele of lachrymal sac	72
Muco-purulent conjunctivitis	79
Muscæ volitantes	237
Muscle, ciliary	447
„ iris	174
Muscles of eyeball, action of	389
„ „ „ combined	391
„ „ division of, in paralysis	403
„ „ strabismus	407
„ „ paralysis of	393
Muscular asthenopia	559
Mydriasis	194
Myopia, axial	518

	PAGE
Myopia, causes of	518
" characters of, by ophthalmoscope	523
" determining causes	520
" diagnosis of	524
" estimation of degree	524
" formation of image in	522
" length of eyeball in	518
" malignant	516
" posterior staphyloma in	518
" progressive	516
" statistics in	521
" symptoms of	522
" treatment by division of external rectus	414
" " " lenses	525
Myopic astigmatism	533
" crescent	523
" ophthalmoscopic appearances in	523
Myosis	195

N.

Nævus of eyelids	38
Nagel on convergence	453
Nasal duct, catheterism of	70
" obstruction of	73
Navy, regulations for	576
Near point (punctum proximum)	448
Nebulæ of cornea	147
Necrosis of orbital walls	367
Negative angle, α	406
Nerve, optic, in hypermetropia	507
" " myopia	522
Nerve fibres, opaque	303
Neuritis	258
Neuro-retinitis	288
Night blindness	316
Nodal points	441
Nystagmus	419

O.

Oedema of the conjunctiva	79
" " optic papilla	261
" " retina	297
Onyx	132
Opacities of cornea	147
" crystalline lens	330
" vitreous	238
Opaque nerve fibres	303
Ophthalmia (<i>see</i> conjunctivitis)	76

	PAGE
Ophthalmia, sympathetic	210
Ophthalmodynamometer	456
Ophthalmological Congress	446
Ophthalmometer	542
Ophthalmoscope	12
" appearance of healthy eye, by	10
" arrangement of patient	13
" direct method	13, 17
" indirect method	15
" retinal vessel seen by	16
Ophthalmoscopic appearances	19
Optic axis	440
" disc in myopia	523
" nerve in hypermetropia	507
" " " myopia	522
" " anatomy of	246
" " atrophy of	264
" " diseases of	246
" " excavation of	273
" " " in glaucoma	273
" " congenital malformation	274
" " healthy, as seen with ophthalmoscope	20
" papilla	248
" " anæmia of	261
" " capillary hyperæmia of	248
" " inflammation of	249
" " " fibrinous	250
" " " interstitial	250
" " " malarial	255
" " " œdema of	261
" " " pathology of	250
" " " syphilitic	254
Optical centre	441
Optics	423
Optometer of Tweedy	544
Orbit, abscess of	369
" caries of walls	368
" cellular tissue, inflammation of	369
" contusion of edge of	364
" encysted tumours of	374
" exophthalmos	372
" exostosis	377
" foreign bodies in	364
" gunshot wounds of	365
" hydatids in	375
" injuries of	364
" necrosis of walls of	367
" periostitis of	366
" sarcoma of	374
Orbital aneurism	378
Orthoptic exercises	416
Orthoscopic lenses	553

P.

	PAGE
Palpebral fissure, elongation of	42
Pannus	150
Pantoscopic spectacles.. .. .	565
Paracentesis of cornea	134, 142
Paralysis of accommodation	554
" muscles of eye	393
" " " causes of	400
" " " prognosis of	401
" " " treatment of	402
" external rectus	395
" inferior rectus	399
" " oblique	399
" internal rectus	399
" iris	194
" levator palpebræ.. .. .	64
" orbicularis palpebrarum	57
" superior rectus	396
" " oblique	399
" third nerve	395
Pediculi	31
Perimeter	8
Periodic-strabismus	407
Periostitis of orbit	366
Pin-hole test	461
Placido's disc	546
Points, cardinal	440
" nodal	441
" principal	441
Polypus of lachrymal sac	73
Position in myopia	521
Posterior staphyloma	518
Pray, test letters of	580
Presbyopia	444, 549
" age at which it commences	549
" definition.. .. .	549
" glasses for	551
" symptoms of	551
" table for.. .. .	551
" treatment of	551
Principal angle	429
" focus	433
" points	441
Prismatic spectacles	565
Prisms	428
" abducting	455
" adducting	455
" test for binocular vision	392, 406
" to test convergence	455

	PAGE
Prisms, use of	455
Progressive myopia	516
Protectors	566
Pseudo Glioma	245
Pterygium	114
Ptosis	54
Punctum proximum	448
" " in emmetropia	448
" " in hypermetropia	450
" " in myopia	451
" remotum	448
" " in emmetropia	450
" " in hypermetropia	450
" " in myopia	451
Pupil in accommodation	447
" in hypermetropia	507
" in myopia	523
Pupil, artificial	198
" " circumstances requiring	198
" " by corelysis	197
" " excision	201
" " excision, Tyrrell's hook in	200
" " iridectomy	201
" " position of	200
Pustular conjunctivitis	107
R.	
Range of accommodation	449
" convergence	455
Rays	423
" emergent	427
" incident	427
Recti, internal	389
Reflection	423
" by concave surface	425
" by convex surface	426
" by plane surface	424
Reflex asthenopia	561
Refraction	427
" diminution of	552
" estimation of	460
" by the eye	440
" index of	427
" by plane surface	428
" by prisms	428
" by spherical surface	429
Regular astigmatism	531
Regulations for army	576
" for civil service	576
" for navy	576

	PAGE
Relative accommodation	458
Relative convergence	458
Remotum punctum	448
" " in emmetropia	448
" " in hypermetropia	450
" " in myopia	451
Retina, anatomy of	283
" appearance of vessels of	22
" detachment of	298
" embolism of vessels of	296
" hæmorrhage into	293
" hyperæmia of	285
" inflammation of	286
" " diabetic	290
" " nephritic	286
" ischæmia of	286
" œdema of	297
" opacity of	286
" pigmentary degeneration of	290
" tumours of	303
Retinal image, size of, in hypermetropia	471
" " in myopia	471
Retinal reflex	22
Retinitis, albuminuric	286
" pigmentosa	290
Retinoscopy	481
" in astigmatism	540
" cases of	498
" in hypermetropia	510
" in myopia	525
" mirror for	481
" oblique movements in	492
" plane mirror in	494
" rate of movement in	487
Rodent ulcer	33
Rods and cones	439
Rupture of cornea	157

S.

Scheffler	553
Scheiner's test	467
Sclero-choroiditis, anterior	168
" posterior	230
Sclerotic	173
" rupture of	172
" tumours of	173
" wounds	171
Sclerotomy	281
Scotoma	322


	PAGE
Secondary changes in myopia	524
Shadow test	481
Shadows in retinoscopy	481
Short sight (myopia)	515
Simple hypermetropia.. .. .	503
Simple myopic astigmatism	533
Snellen	462
Sparkling synchysis	240
Spasm of accommodation	555
" causes of	555
" symptoms of	555
" treatment for	556
Spectacles (<i>see also</i> glasses)	563
" for aphakia.. .. .	515
" for astigmatism	542, 563
" for hypermetropia.. .. .	511, 563
" for myopia	527, 563
" for presbyopia	551
" for strabismus	414
Squint (<i>see</i> strabismus)	404
Staphyloma of cornea	142
" " treatment of	143
" sclerotic, anterior	142
" " posterior	229
Statistics in myopia	521
Stenopaic slit	546
" glasses	565
Stereoscope	416
Strabismometer.. .. .	408
Strabismus	404
" alternating	407
" angle of	408
" apparent	406
" causes of	410
" concomitant	406
" constant	407
" convergent	409
" divergent.. .. .	413
" monolateral	407
" paralytic	392
" periodic	407
" real	406
" treatment of	414
Sturm, interval of	532
Style, use of	69
Surfaces, refracting, of the eye	440
Symblepharon	113
Sympathetic cyclitis	210
Symptoms of asthenopia	556
" astigmatism	536
" hypermetropia	508

	PAGE
Symptoms of myopia	522
" presbyopia	551
Synechia, anterior	161
" posterior	177
Syphilitic iritis.. .. .	178
" keratitis	125
" ulceration of eyelids	31

T.

Table for presbyopia	551
" of amplitude of accommodation	452
" of angles of convergence	457
" of inches and dioptries.. .. .	575
" of length of axial line in hypermetropia	506
" " " myopia	518
Tattooing cornea	149
Tenotomy of muscles in paralysis	417
" " strabismus	417
Tension of the eyeball.. .. .	23
Test for aphakia	513
" clock face	538
" fan.. .. .	539
" Pray's letters	580
" objects	537
" pin-hole	461
" types for near vision	462
" Jaeger	462
" Snellen	462
Tinea tarsi	28
Tobacco, effects on optic disc	325
Traumatic cataract	333
Treatment of asthenopia	558
" astigmatism	542
" hypermetropia	511
" myopia	525
" paralysis of accommodation	554
" presbyopia	551
" spasm of accommodation	556
" strabismus	414
Trichiasis	49
Tumours of choroid	225
" conjunctiva	118
" eyelids	37
" iris	192
" orbit	374
" retina	303
Tweedy's optometer	544

	U.						PAGE
Ulcers of the cornea	138
" " eyelids	31
	V.						
Vascular cornea	138
Vision, acuteness of	461
" binocular	392
" normal	462
Visual angle	462
" axis	405
" field	7
Vitreous humour	235
" anatomy of	235
" effusion of blood into	240
" entozoa in	242
" flocculent bodies in	239
" foreign bodies in	242
" inflammation of	237
" opacities of	238
	W.						
Wounds of the choroid	226
" " conjunctiva	111
" " cornea..	156
" " eyelids..	26
" " orbit	365
" " sclerotic	171
	X.						
Xanthelasma palpebrarum	35
Xerophthalmia..	110
	Y.						
Yellow spot	22, 462
Young	530
	Z.						
Zonular cataract	333



J. & A. CHURCHILL'S
MEDICAL CLASS BOOKS.

ANATOMY.

BRAUNE.—An Atlas of Topographical Anatomy, after Plane Sections of Frozen Bodies. By WILHELM BRAUNE, Professor of Anatomy in the University of Leipzig. Translated by EDWARD BELLAMY, F.R.C.S., Surgeon to Charing Cross Hospital, and Lecturer on Surgery in its School. With 34 Photo-lithographic Plates and 46 Woodcuts. Large Imp. 8vo, 40s.

FLOWER.—Diagrams of the Nerves of the Human Body, exhibiting their Origin, Divisions, and Connexions, with their Distribution to the various Regions of the Cutaneous Surface, and to all the Muscles. By WILLIAM H. FLOWER, C.B., F.R.C.S., F.R.S. Third Edition, containing 6 Plates. Royal 4to, 12s.

GODLEE.—An Atlas of Human Anatomy: illustrating most of the ordinary Dissections and many not usually practised by the Student. By RICKMAN J. GODLEE, M.S., F.R.C.S., Surgeon to University College Hospital; Teacher of Operative Surgery, and Assistant Professor of Clinical Surgery in University College; With 48 Imp. 4to Coloured Plates, containing 112 Figures, and a Volume of Explanatory Text, with many Engravings. 8vo, £4 14s. 6d.

HEATH.—Practical Anatomy: a Manual of Dissections. By CHRISTOPHER HEATH, F.R.C.S., Holme Professor of Clinical Surgery in University College and Surgeon to the Hospital. Seventh Edition, revised by RICKMAN J. GODLEE, M.S. Lond., F.R.C.S., Teacher of Operative Surgery, and Assistant Professor of Clinical Surgery in University College, and Surgeon to the Hospital. With 24 Coloured Plates and 278 Engravings. Crown 8vo, 15s.

11, NEW BURLINGTON STREET.

ANATOMY—*continued.*

HOLDEN.—**A Manual of the Dissection of the Human Body.** By LUTHER HOLDEN, F.R.C.S., Consulting-Surgeon to St. Bartholomew's Hospital. Fifth Edition, by JOHN LANGTON F.R.C.S. and Member of the Court of Examiners; Surgeon to St. Bartholomew's Hospital. With 208 Engravings. 8vo, 20s.

By the same Author.

Human Osteology: comprising a Description of the Bones, with Delineations of the Attachments of the Muscles, the General and Microscopical Structure of Bone and its Development. Seventh Edition, edited by CHARLES STEWART, Conservator of the Museum and Hunterian Professor of Comparative Anatomy and Physiology, R.C.S., and R. W. REID, M.D., F.R.C.S., Professor of Anatomy in the University of Aberdeen. With 59 Lithographic Plates and 75 Engravings. Royal 8vo, 16s.

ALSO,

Landmarks, Medical and Surgical. Fourth Edition. 8vo, 3s. 6d.

MORRIS.—**The Anatomy of the Joints of Man.** By HENRY MORRIS, M.A., F.R.C.S., Surgeon to, and Lecturer on Anatomy and Practical Surgery at, the Middlesex Hospital. With 44 Plates (19 Coloured) and Engravings. 8vo, 16s.

WAGSTAFFE.—**The Student's Guide to Human Osteology.** By WM. WARWICK WAGSTAFFE, F.R.C.S., late Assistant-Surgeon to, and Lecturer on Anatomy at, St. Thomas's Hospital. With 23 Plates and 66 Engravings. Fcap. 8vo, 10s. 6d.

WILSON — BUCHANAN — CLARK. — **Wilson's Anatomist's Vade-Mecum: a System of Human Anatomy.** Tenth Edition, by GEORGE BUCHANAN, Professor of Clinical Surgery in the University of Glasgow, and HENRY E. CLARK, M.R.C.S., Lecturer on Anatomy in the Glasgow Royal Infirmary School of Medicine. With 450 Engravings, including 26 Coloured Plates. Crown 8vo, 18s.

BOTANY.

BENTLEY AND TRIMEN.—Medicinal Plants:

being descriptions, with original Figures, of the Principal Plants employed in Medicine, and an account of their Properties and Uses. By ROBERT BENTLEY, F.L.S., and HENRY TRIMEN, M.B., F.R.S., F.L.S. In 4 Vols., large 8vo, with 306 Coloured Plates, bound in half morocco, gilt edges, £11 11s.

BENTLEY.—A Manual of Botany. By Robert

BENTLEY, F.L.S., M.R.C.S., Emeritus Professor of Botany in King's College and to the Pharmaceutical Society. With nearly 1178 Engravings. Fifth Edition. Crown 8vo, 15s.

By the same Author.

The Student's Guide to Structural, Morphological, and Physiological Botany. With 660 Engravings Fcap. 8vo, 7s. 6d.

ALSO,

The Student's Guide to Systematic Botany, including the Classification of Plants and Descriptive Botany. With 357 Engravings. Fcap. 8vo, 3s. 6d.

CHEMISTRY.

BERNAYS.—Notes on Analytical Chemistry

for Students in Medicine. By ALBERT J. BERNAYS, Ph.D., F.C.S., F.I.C., Professor of Chemistry, &c., at St. Thomas's Hospital Medical School. Third Edition. Crown 8vo, 4s. 6d.

BLOXAM.—Chemistry, Inorganic and Organic;

with Experiments. By CHARLES L. BLOXAM. Seventh Edition, by JOHN MILLAR THOMSON, Professor of Chemistry, King's College, London, and ARTHUR G. BLOXAM, Demonstrator of Chemistry, Royal Agricultural College, Cirencester. With 282 Illustrations. 8vo, 18s.

By the same Author.

Laboratory Teaching; or, Progressive

Exercises in Practical Chemistry. Fifth Edition. With 89 Engravings. Crown 8vo, 5s. 6d.

BOWMAN AND BLOXAM.—Practical Chemistry,

including Analysis. By JOHN E. BOWMAN, and CHARLES L. BLOXAM, late Professor of Chemistry in King's College. Eighth Edition. With 90 Engravings. Fcap. 8vo, 5s. 6d.

CHEMISTRY—*continued.*

CLOWES.—**Practical Chemistry and Qualitative Analysis.** Adapted for use in the Laboratories of Colleges and Schools. By FRANK CLOWES, D.Sc. Lond., Professor of Chemistry at the University College, Nottingham. Fifth Edition. With 57 Engravings and Frontispiece. Post 8vo, 7s. 6d.

COOK.—**Introductory Inorganic Analysis.** A First Course of Chemical Testing. By ERNEST H. COOK, D.Sc. Lond. F.C.S., Physical Science Master, Merchant Venturers' School, Bristol. Crown 8vo, 1s. 6d.

FOWNES.—**Manual of Chemistry.**—*See WATTS.*

FRANKLAND AND JAPP.—**Inorganic Chemistry.** By EDWARD FRANKLAND, Ph.D., D.C.L., F.R.S., and F. R. JAPP, M.A., Ph.D., F.I.C., Professor of Chemistry in the University of Aberdeen. With 2 Lithographic Plates and numerous Wood Engravings. 8vo, 24s.

JOHNSON.—**The Analyst's Laboratory Companion.** By ALFRED E. JOHNSON, Assoc. R.C.Sc.I., F.I.C., F.C.S., First Prizeman in Chemistry, Physics, and Mathematics of R.C.Sc.I. Crown 8vo, 5s.

MORLEY.—**Outlines of Organic Chemistry.** By H. FORSTER MORLEY, M.A., D.Sc., Joint Editor of "Watts' Dictionary of Chemistry." Crown 8vo, 7s. 6d.

VACHER.—**A Primer of Chemistry, including Analysis.** By ARTHUR VACHER. 18mo, 1s.

VALENTIN.—**Chemical Tables for the Lecture-room and Laboratory.** By WILLIAM G. VALENTIN, F.C.S. In Five large Sheets, 5s. 6d.

VALENTIN AND HODGKINSON.—**A Course of Qualitative Chemical Analysis.** By the late W. G. VALENTIN, F.C.S. Seventh Edition by Dr. W. R. HODGKINSON, F.R.S.E., Professor of Chemistry and Physics in the Royal Artillery College, and Royal Military Academy, Woolwich; assisted by H. CHAPMAN-JONES, F.C.S., Demonstrator in the Royal School of Mines, and F. E. MATTHEWS, Ph.D., of Cooper's Hill College. With Engravings and Map of Spectra. 8vo, 8s. 6d.

The Tables for the Qualitative Analysis of Simple and Compound Substances, with Map of Spectra, printed separately. 8vo, 2s. 6d.

11, NEW BURLINGTON STREET.

CHEMISTRY—*continued.*

WATTS.—Manual of Chemistry, Theoretical and Practical. (Based on Fownes' Manual.) BY HENRY WATTS, B.A., F.R.S.

VOL. I.—Physical and Inorganic Chemistry. Second Edition (Fourteenth of Fownes'). By WILLIAM A. TILDEN, D.Sc., F.R.S., Professor of Chemistry in the Mason College, Birmingham. With 122 Wood Engravings, and Coloured Plate of Spectra. Crown 8vo, 8s. 6d.

VOL. II.—Chemistry of Carbon-Compounds, or Organic Chemistry. Second Edition (Thirteenth of Fownes'). Edited by WM. A. TILDEN, D.Sc., F.R.S. With Engravings. Crown 8vo, 10s.

CHILDREN, DISEASES OF.

DAY.—A Manual of the Diseases of Children. By WILLIAM H. DAY, M.D., Physician to the Samaritan Hospital for Women and Children. Second Edition. Crown 8vo, 12s. 6d.

ELLIS.—A Practical Manual of the Diseases of Children. By EDWARD ELLIS, M.D., late Senior Physician to the Victoria Hospital for Sick Children. With a Formulary. Fifth Edition. Crown 8vo, 10s.

GOODHART.—The Student's Guide to Diseases of Children. By JAMES FREDERIC GOODHART, M.D., F.R.C.P., Physician to Guy's Hospital and Lecturer on Pathology in its Medical School. Fourth Edition. Fcap. 8vo, 10s. 6d.

SMITH.—A Practical Treatise on Disease in Children. By EUSTACE SMITH, M.D., F.R.C.P., Physician to H.M. the King of the Belgians, and to the East London Hospital for Children. Second Edition. 8vo, 22s.

By the same Author.

Clinical Studies of Disease in Children.
Second Edition. Post 8vo, 7s. 6d.

Also,

On the Wasting Diseases of Infants and Children. Fifth Edition. Post 8vo, 8s. 6d.

STEINER.—Compendium of Children's Diseases; a Handbook for Practitioners and Students. By JOHANN STEINER, M.D. Translated by LAWSON TAIT, F.R.C.S., Surgeon to the Birmingham Hospital for Women, &c. 8vo, 12s. 6d.

DENTISTRY.

GORGAS. — **Dental Medicine: a Manual of**
Dental Materia Medica and Therapeutics. By FERDINAND J. S. GORGAS,
A.M., M.D., D.D.S., Professor of Dental Surgery and Science, &c., in
the University of Maryland. Third Edition. 8vo, 16s.

HARRIS. — **The Principles and Practice of**
Dentistry; including Anatomy, Physiology, Pathology, Therapeutics,
Dental Surgery, and Mechanism. By CHAPIN A. HARRIS, M.D., D.D.S.
Twelfth Edition, revised and edited by FERDINAND J. S. GORGAS,
A.M., M.D., D.D.S. With over 1,000 Illustrations. 8vo, 33s.

STOCKEN. — **Elements of Dental Materia Medica**
and Therapeutics, with Pharmacopœia. By JAMES STOCKEN, L.D.S.R.C.S.S.,
late Lecturer on Dental Materia Medica and Therapeutics and Dental
Surgeon to the National Dental Hospital; assisted by THOMAS GADDES,
L.D.S. Eng. and Edin. Third Edition. Fcap. 8vo, 7s. 6d.

TOMES (C. S.). — **Manual of Dental Anatomy,**
Human and Comparative. By CHARLES S. TOMES, M.A., F.R.S.
Third Edition. With 212 Engravings. Crown 8vo, 12s. 6d.

TOMES (J. and C. S.). — **A System of Dental**
Surgery. By Sir JOHN TOMES, F.R.S., and CHARLES S. TOMES, M.A.,
M.R.C.S., F.R.S. Third Edition. With 292 Engravings. Crown
8vo, 15s.

EAR, DISEASES OF.

BURNETT. — **The Ear: its Anatomy, Physio-**
logy, and Diseases. A Practical Treatise for the Use of Medical
Students and Practitioners. By CHARLES H. BURNETT, M.D., Aural
Surgeon to the Presbyterian Hospital, Philadelphia. Second Edition.
With 107 Engravings. 8vo, 18s.

DALBY. — **On Diseases and Injuries of the Ear.**
By SIR WILLIAM B. DALBY, F.R.C.S., Aural Surgeon to, and Lecturer
on Aural Surgery at, St. George's Hospital. Third Edition. With
Engravings. Crown 8vo. 7s. 6d.

11, *NEW BURLINGTON STREET.*

EAR, DISEASES OF—*continued.*

JONES.—Practitioner's Handbook of Diseases

of the Ear and Naso-Pharynx. By H. MACNAUGHTON JONES, M.D., M.Ch.; Examiner, and late Professor in the Queen's University; and Surgeon to the Cork Ophthalmic and Aural Hospital. Third Edition of "Aural Surgery." With 128 Engravings, and 2 Coloured Plates (16 Figures). Royal 8vo, 6s.

By the same Author.

Atlas of the Diseases of the Membrana

Tympani. In Coloured Plates, containing 59 Figures. With Explanatory Text. Crown 4to, 21s.

FORENSIC MEDICINE.

ABERCROMBIE.—The Student's Guide to

Medical Jurisprudence. By JOHN ABERCROMBIE, M.D., F.R.C.P., Physician to Charing Cross Hospital. Fcap. 8vo, 7s. 6d.

OGSTON.—Lectures on Medical Jurisprudence.

By FRANCIS OGSTON, M.D., late Professor of Medical Jurisprudence and Medical Logic in the University of Aberdeen. Edited by FRANCIS OGSTON, Jun., M.D., late Lecturer on Practical Toxicology in the University of Aberdeen. With 12 Plates. 8vo, 18s.

TAYLOR.—The Principles and Practice of

Medical Jurisprudence. By ALFRED S. TAYLOR, M.D., F.R.S. Third Edition, revised by THOMAS STEVENSON, M.D., F.R.C.P., Lecturer on Chemistry and Medical Jurisprudence at Guy's Hospital; Examiner in Chemistry at the Royal College of Physicians; Official Analyst to the Home Office. With 188 Engravings. 2 Vols. 8vo, 31s. 6d.

By the same Author.

A Manual of Medical Jurisprudence.

Eleventh Edition, revised by THOMAS STEVENSON, M.D., F.R.C.P. With 56 Engravings. Crown 8vo, 14s.

ALSO,

On Poisons, in relation to Medical Juris-

prudence and Medicine. Third Edition. With 104 Engravings. Crown 8vo, 16s.

TIDY AND WOODMAN.—A Handy-Book of

Forensic Medicine and Toxicology. By C. MEYMOTT TIDY, M.B.; and W. BATHURST WOODMAN, M.D., F.R.C.P. With 8 Lithographic Plates and 116 Wood Engravings. 8vo, 31s. 6d.

HYGIENE.

PARKES.—A Manual of Practical Hygiene.

By EDMUND A. PARKES, M.D., F.R.S. Seventh Edition by F. DE CHAUMONT, M.D., F.R.S., late Professor of Military Hygiene in the Army Medical School. With 9 Plates and 101 Engravings. 8vo, 18s.

WILSON.—A Handbook of Hygiene and Sanitary Science.

By GEORGE WILSON, M.A., M.D., F.R.S.E., Medical Officer of Health for Mid Warwickshire. Sixth Edition. With Engravings. Crown 8vo, 10s. 6d.

MATERIA MEDICA AND THERAPEUTICS.

LESCHER.—Recent Materia Medica. Notes

on their Origin and Therapeutics. By F. HARWOOD LESCHER, F.C.S., Pereira Medallist. Third Edition. 8vo, 2s. 6d.

OWEN.—A Manual of Materia Medica; in-

corporating the Author's "Tables of Materia Medica." By ISAMBARD OWEN, M.D., F.R.C.P., Lecturer on Materia Medica and Therapeutics to St. George's Hospital. Second Edition. Crown 8vo, 6s. 8d.

ROYLE AND HARLEY.—A Manual of Materia

Medica and Therapeutics. By J. FORBES ROYLE, M.D., F.R.S., and JOHN HARLEY, M.D., F.R.C.P., Physician to, and Joint Lecturer on Clinical Medicine at, St. Thomas's Hospital. Sixth Edition, including addition and alterations in the B.P. 1885. With 139 Engravings. Crown 8vo, 15s.

SOUTHALL.—The Organic Materia Medica of

the British Pharmacopœia, Systematically Arranged. By W. SOUTHALL, F.L.S. Fourth Edition. Crown 8vo, 5s.

THOROWGOOD.—The Student's Guide to

Materia Medica and Therapeutics. By JOHN C. THOROWGOOD, M.D., F.R.C.P. Second Edition. With Engravings. Fcap. 8vo, 7s.

WARING.—A Manual of Practical Therapeu-

tics. By EDWARD J. WARING, C.I.E., M.D., F.R.C.P. Fourth Edition, revised by the Author and DUDLEY W. BUXTON, M.D., M.R.C.P. Crown 8vo, 14s.

MEDICINE.

CHARTERIS.—**The Student's Guide to the Practice of Medicine.** By M. CHARTERIS, M.D., Professor of Therapeutics and Materia Medica, University of Glasgow. With Engravings on Copper and Wood. Fifth Edition. Fcap. 8vo, 9s.

FAGGE.—**The Principles and Practice of Medicine.** By the late C. HILTON FAGGE, M.D., F.R.C.P., Edited by PHILIP H. PYE-SMITH, M.D., F.R.S., F.R.C.P., Physician to, and Lecturer on Medicine in, Guy's Hospital. Second Edition. 2 Vols. 8vo. Cloth, 38s., leather, 44s.

FENWICK.—**The Student's Guide to Medical Diagnosis.** By SAMUEL FENWICK, M.D., F.R.C.P., Physician to the London Hospital. Sixth Edition. With 114 Engravings. Fcap. 8vo, 7s.

By the same Author.

The Student's Outlines of Medical Treatment. Second Edition. Fcap. 8vo, 7s.

FOWLER.—**A Dictionary of Practical Medicine.** By Various Writers. Edited by JAMES KINGSTON FOWLER, M.A., M.D., F.R.C.P., Senior Assistant Physician to, and Lecturer on Pathological Anatomy at, Middlesex Hospital. 8vo., cloth, 21s. ; half-calf, 25s.

HARRIS.—**The Student's Guide to Diseases of the Chest.** By VINCENT D. HARRIS, M.D., F.R.C.P., Physician to the Victoria Park Hospital for Diseases of the Chest. With 55 Engravings, plain and Coloured. Fcap. 8vo, 7s. 6d.

NIXON.—**Handbook of Hospital Practice and Physical Diagnosis.** By CHRISTOPHER J. NIXON, M.D., LL.D. Professor of Medicine in the Catholic University, Dublin; Examiner in Medicine, K.Q.C.P.I., and for the Conjoint Examinations of K.Q.C.P. and S. Irel. With Plates and Engravings. 8vo, 9s.

TAYLOR.—**A Manual of the Practice of Medicine.** By FREDERICK TAYLOR, M.D., F.R.C.P., Physician to, and Lecturer on Medicine at, Guy's Hospital. With 23 Illustrations. Crown 8vo, 15s.

WARNER.—**The Student's Guide to Clinical Medicine and Case-Taking.** By FRANCIS WARNER, M.D., F.R.C.P., Physician to the London Hospital. Second Edition. Fcap. 8vo, 5s.

MIDWIFERY.

- BARNES.**—Lectures on Obstetric Operations, including the Treatment of Hæmorrhage, and forming a Guide to the Management of Difficult Labour. By ROBERT BARNES, M.D., F.R.C.P., Consulting Obstetric Physician to St. George's Hospital. Fourth Edition. With 121 Engravings. 8vo, 12s. 6d.
- BURTON.**—Handbook of Midwifery for Midwives. By JOHN E. BURTON, M.R.C.S., L.R.C.P., Surgeon to the Liverpool Hospital for Women. Second Edition. With Engravings. Fcap 8vo, 6s.
- GALABIN.**—A Manual of Midwifery. By Alfred LEWIS GALABIN, M.A., M.D., F.R.C.P., Obstetric Physician and Lecturer on Midwifery, &c., to Guy's Hospital, Examiner in Midwifery to the Conjoint Examining Board for England. With 227 Engravings. Crown 8vo, 15s.
- RAMSBOTHAM.**—The Principles and Practice of Obstetric Medicine and Surgery. By FRANCIS H. RAMSBOTHAM, M.D., formerly Obstetric Physician to the London Hospital. Fifth Edition. With 120 Plates, forming one thick handsome volume. 8vo, 22s.
- REYNOLDS.**—Notes on Midwifery: specially designed to assist the Student in preparing for Examination. By J. J. REYNOLDS, L.R.C.P., M.R.C.S. Second Edition. With 15 Engravings. Fcap. 8vo, 4s.
- ROBERTS.**—The Student's Guide to the Practice of Midwifery. By D. LLOYD ROBERTS, M.D., F.R.C.P., Lecturer on Clinical Midwifery and Diseases of Women at Owen's College, Physician to St. Mary's Hospital, Manchester. Third Edition. With 2 Coloured Plates and 127 Engravings. Fcap. 8vo, 7s. 6d.
- SCHROEDER.**—A Manual of Midwifery; including the Pathology of Pregnancy and the Puerperal State. By KARL SCHROEDER, M.D., Professor of Midwifery in the University of Erlangen. Translated by C. H. CARTER, M.D. With Engravings. 8vo, 12s. 6d.
- SWAYNE.**—Obstetric Aphorisms for the Use of Students commencing Midwifery Practice. By JOSEPH G. SWAYNE, M.D., Lecturer on Obstetric Medicine at the Bristol Medical School. Ninth Edition. With 17 Engravings. Fcap. 8vo, 3s. 6d.
-

MICROSCOPY.

- CARPENTER.**—**The Microscope and its Revelations.** By WILLIAM B. CARPENTER, C.B., M.D., F.R.S. Seventh Edition. Edited by Rev. Dr. DALLINGER, F.R.S. With about 600 Engravings. Crown 8vo. *(In the press.)*
- LEE.**—**The Microtomist's Vade-Mecum; a Handbook of the Methods of Microscopic Anatomy.** By ARTHUR BOLLES LEE, Assistant in the Russian Laboratory of Zoology at Villefranche-sur-Mer (Nice). Second Edition. 8vo, 12s. 6d.

OPHTHALMOLOGY.

- GOWERS.**—**A Manual and Atlas of Medical Ophthalmoscopy.** By W. R. GOWERS, M.D., F.R.S., F.R.C.P., Physician to the National Hospital for the Paralysed and Epileptic. Third Edition. Edited with the assistance of MARCUS GUNN, M.B., F.R.C.S., Surgeon to the Royal London Ophthalmic Hospital; Ophthalmic Surgeon to the National Hospital for the Paralysed and Epileptic. With 12 Autotype Plates and 83 Engravings. 8vo, 16s.
- HARTRIDGE.**—**The Refraction of the Eye.** By GUSTAVUS HARTRIDGE, F.R.C.S., Surgeon to the Royal Westminster Ophthalmic Hospital. Fourth Edition. With 98 Illustrations, Test Types, &c. Crown 8vo, 6s.
- HIGGINS.**—**Hints on Ophthalmic Out-Patient Practice.** By CHARLES HIGGINS, F.R.C.S., Ophthalmic Surgeon to, and Lecturer on Ophthalmology at, Guy's Hospital. Third Edition. Fcap. 8vo, 3s.
- MACNAMARA.**—**A Manual of the Diseases of the Eye.** By CHARLES MACNAMARA, F.R.C.S., Surgeon to, and Lecturer on Surgery at, the Westminster Hospital. Fourth Edition. With 4 Coloured Plates and 66 Engravings. Crown 8vo, 10s. 6d.
- NETTLESHIP.**—**The Student's Guide to Diseases of the Eye.** By EDWARD NETTLESHIP, F.R.C.S., Ophthalmic Surgeon to St. Thomas's Hospital, Surgeon to the Royal London Ophthalmic Hospital. Fifth Edition. With 164 Engravings, and a Coloured Plate illustrating Colour-blindness. Fcap. 8vo, 7s. 6d.
- POLLOCK.**—**The Normal and Pathological Histology of the Human Eye and Eyelids.** By C. FRED. POLLOCK, M.D., F.R.C.S.E., and F.R.S.E., Surgeon for Diseases of the Eye, Anderson's College Dispensary, Glasgow. With 100 Plates, containing 230 Original Drawings by the Author, Lithographed in black and colours. Crown 8vo, 15s.

OPHTHALMOLOGY—*continued.*

WOLFE.—**On Diseases and Injuries of the Eye :**

a Course of Systematic and Clinical Lectures to Students and Medical Practitioners. By J. R. WOLFE, M.D., F.R.C.S.E., Senior Surgeon to the Glasgow Ophthalmic Institution, Lecturer on Ophthalmic Medicine and Surgery in Anderson's College. With 10 Coloured Plates, and 120 Wood Engravings, 8vo, 21s.

PATHOLOGY.

BOWLBY.—**The Student's Guide to Surgical**

Pathology and Morbid Anatomy. By ANTHONY A. BOWLBY, F.R.C.S., Surgical Registrar and Demonstrator of Practical Surgery and Surgical Pathology at St. Bartholomew's Hospital. Second Edition. With 158 Engravings. Fcap. 8vo, 9s.

JONES AND SIEVEKING.—**A Manual of Patho-**

logical Anatomy. By C. HANDFIELD JONES, M.B., F.R.S., and SIR EDWARD H. SIEVEKING, M.D., F.R.C.P. Second Edition. Edited, with considerable enlargement, by J. F. PAYNE, M.B., Physician to, and Lecturer on Pathological Anatomy at, St. Thomas's Hospital. With 195 Engravings. Crown 8vo, 16s.

LANCEREAUX.—**Atlas of Pathological Ana-**

tomy. By Dr. LANCEREAUX. Translated by W. S. GREENFIELD, M.D., Professor of Pathology in the University of Edinburgh. With 70 Coloured Plates. Imperial 8vo, £5 5s.

MOORE.—**Pathological Anatomy of Diseases,**

arranged according to the Nomenclature of Diseases of the R.C.P. Lond. By NORMAN MOORE, M.D., Assistant Physician and Lecturer on Pathological Anatomy to St. Bartholomew's Hospital. With 110 Illustrations. Fcap. 8vo, 8s. 6d.

SUTTON.—**An Introduction to General**

Pathology. By JOHN BLAND SUTTON, F.R.C.S., Sir E. WILSON Lecturer on Pathology, R.C.S.; Assistant Surgeon to, and Lecturer on Anatomy at, Middlesex Hospital. With 149 Engravings. 8vo, 14s.

WYNTER AND WETHERED.—**A Manual of**

Clinical and Practical Pathology. By W. ESSEX WYNTER, M.D., Medical Registrar and late Demonstrator of Anatomy and Chemistry at the Middlesex Hospital; and FRANK J. WETHERED, M.D., Assistant Physician to the City of London Hospital for Diseases of the Chest. With 4 Coloured Plates and 67 other Illustrations, 8vo, 12s. 6d.

11, NEW BURLINGTON STREET.

PHYSIOLOGY.

- CARPENTER.**—Principles of Human Physiology. By WILLIAM B. CARPENTER, C.B., M.D., F.R.S. Ninth Edition. Edited by Henry Power, M.B., F.R.C.S. With 3 Steel Plates and 377 Wood Engravings. 8vo, 31s. 6d.
- DALTON.**—A Treatise on Human Physiology: designed for the use of Students and Practitioners of Medicine. By JOHN C. DALTON, M.D., Professor of Physiology and Hygiene in the College of Physicians and Surgeons, New York. Seventh Edition. With 252 Engravings. Royal 8vo, 20s.
- FREY.**—The Histology and Histo-Chemistry of Man. A Treatise on the Elements of Composition and Structure of the Human Body. By HEINRICH FREY, Professor of Medicine in Zurich. Translated by ARTHUR E. BARKER, Surgeon to the University College Hospital. With 608 Engravings. 8vo, 21s.
- SANDERSON.**—Handbook for the Physiological Laboratory: containing an Exposition of the fundamental facts of the Science, with explicit Directions for their demonstration. By J. BURDON SANDERSON, M.D., F.R.S.; E. KLEIN, M.D., F.R.S.; MICHAEL FOSTER, M.D., F.R.S., and T. LAUDER BRUNTON, M.D., F.R.S. 2 Vols., with 123 Plates. 8vo, 24s.
- SHORE.**—Elementary Practical Biology. Vegetable. By THOMAS W. SHORE, M.D., B.Sc. Lond., Lecturer on Comparative Anatomy at St. Bartholomew's Hospital. 8vo, 6s.
- YEO.**—A Manual of Physiology for the Use of Junior Students of Medicine. By GERALD F. YEO, M.D., F.R.C.S., F.R.S., late Professor of Physiology in King's College, London. Second Edition. With 318 Engravings (many figures). Crown 8vo, 14s.

PSYCHOLOGY.

- BUCKNILL AND TUKE.**—A Manual of Psychological Medicine: containing the Lunacy Laws, Nosology, Ætiology, Statistics, Description, Diagnosis, Pathology, and Treatment of Insanity, with an Appendix of Cases. By JOHN C. BUCKNILL, M.D. F.R.S., and D. HACK TUKE, M.D., F.R.C.P. Fourth Edition with 12 Plates (30 Figures). 8vo, 25s.
- CLOUSTON.**—Clinical Lectures on Mental Diseases. By THOMAS S. CLOUSTON, M.D., and F.R.C.P. Edin.; Lecturer on Mental Diseases in the University of Edinburgh. Second Edition. With 8 Plates (6 Coloured). Crown 8vo, 12s. 6d.

SURGERY.

BELLAMY.—**The Student's Guide to Surgical Anatomy**; an Introduction to Operative Surgery. By EDWARD BELLAMY, F.R.C.S., Surgeon to, and Lecturer on Surgery at, Charing Cross Hospital. Third Edition. With 80 Engravings. Fcap. 8vo, 7s. 6d.

BRYANT.—**A Manual for the Practice of Surgery.** By THOMAS BRYANT, F.R.C.S., Consulting Surgeon to Guy's Hospital. Fourth Edition. With 750 Illustrations (many being coloured), and including 6 Chromo-Lithographic Plates. 2 Vols. Crown 8vo, 32s.

DRUITT AND BOYD.—**Druitt's Surgeon's Vade-Mecum**; a Manual of Modern Surgery. Edited by STANLEY BOYD, M.B., B.S. Lond., F.R.C.S., Assistant Surgeon and Pathologist to the Charing Cross Hospital. Twelfth Edition. With 373 Engravings. Crown 8vo, 16s.

HEATH.—**A Manual of Minor Surgery and Bandaging.** By CHRISTOPHER HEATH, F.R.C.S., Holme Professor of Clinical Surgery in University College and Surgeon to the Hospital. Ninth Edition. With 146 Engravings. Fcap. 8vo, 6s.

By the same Author.

A Course of Operative Surgery: with Twenty Plates (containing many figures) drawn from Nature by M. LÉVEILLÉ, and Coloured. Second Edition. Large 8vo, 30s.

ALSO,

The Student's Guide to Surgical Diagnosis. Second Edition. Fcap. 8vo, 6s. 6d.

JACOBSON.—**The Operations of Surgery: intended especially for the use of those recently appointed on a Hospital Staff, and for those preparing for the Higher Examinations.** By W. H. A. JACOBSON, M.A., M.B., M.Ch. Oxon., F.R.C.S., Assistant Surgeon to Guy's Hospital, and Lecturer on Anatomy in the Medical School. With 199 Engravings. 8vo, 30s.

11, NEW BURLINGTON STREET.

SURGERY—*continued.*

SOUTHAM.—**Regional Surgery: including Surgical Diagnosis.** A Manual for the use of Students. BY **FREDERICK A. SOUTHAM, M.A., M.B. Oxon., F.R.C.S.,** Assistant-Surgeon to the Royal Infirmary, and Assistant-Lecturer on Surgery in the Owen's College School of Medicine, Manchester. Vol. 2. The Upper Extremity and Thorax. Crown 8vo, 7s. 6d. Vol. 3. The Abdomen and Lower Extremity. Crown 8vo, 7s.

WALSHAM.—**Surgery: its Theory and Practice** (Student's Guide Series). By **WILLIAM J. WALSHAM, F.R.C.S.,** Assistant Surgeon to, and Lecturer on Anatomy at, St. Bartholomew's Hospital. Third Edition. With 318 Engravings. Fcap. 8vo, 10s. 6d.

TERMINOLOGY.

MAXWELL.—**Terminologia Medica Polyglotta:** a Concise International Dictionary of Medical Terms (French, Latin, English, German, Italian, Spanish, and Russian). By **THEODORE MAXWELL, M.D., B.Sc. Lond., F.R.C.S. Edin.** Roy. 8vo, 16s.

MAYNE.—**A Medical Vocabulary: being an Explanation of all Terms and Phrases used in the various Departments of Medical Science and Practice, giving their Derivation, Meaning, Application, and Pronunciation.** By **R. G. MAYNE, M.D., LL.D.** Sixth Edition, by **W. W. WAGSTAFFE, B.A., F.R.C.S.** Crown 8vo, 10s. 6d.

TREVES AND LANG.—**A German-English Dictionary of Medical Terms.** By **FREDERICK TREVES, F.R.C.S.,** Surgeon to the London Hospital, and **HUGO LANG, B.A.** Half-bound in calf, 12s.

WOMEN, DISEASES OF.

BARNES.—**A Clinical History of the Medical and Surgical Diseases of Women.** By **ROBERT BARNES, M.D., F.R.C.P.,** Obstetric Physician to, and Lecturer on Diseases of Women, &c., at, St. George's Hospital. Second Edition. With 181 Engravings. 8vo, 28s.

DUNCAN.—**Clinical Lectures on the Diseases of Women.** By **J. MATTHEWS DUNCAN, A.M., M.D., LL.D., F.R.C.P. F.R.S.,** late Physician Accoucheur to, and Lecturer on Midwifery at, St. Bartholomew's Hospital. Fourth Edition. 8vo, 16s.

WOMEN, DISEASES OF—*continued.*

GALABIN.—**The Student's Guide to the Diseases of Women.** By ALFRED L. GALABIN, M.D., F.R.C.P., Obstetric Physician to Guy's Hospital, Examiner in Obstetric Medicine to the University of Cambridge, and to the R. C. P. Lond. Fourth Edition. With 94 Engravings. Fcap. 8vo, 7s. 6d.

REYNOLDS.—**Notes on Diseases of Women.** Specially designed to assist the Student in preparing for Examination. By J. J. REYNOLDS, L.R.C.P., M.R.C.S. Third Edition. Fcap. 8vo, 2s. 6d.

SAVAGE.—**The Surgery of the Female Pelvic Organs.** By HENRY SAVAGE, M.D., Lond., F.R.C.S., one of the Consulting Medical Officers of the Samaritan Hospital for Women. Fifth Edition, with 17 Lithographic Plates (15 Coloured), and 52 Woodcuts. Royal 4to, 35s.

WEST AND DUNCAN.—**Lectures on the Diseases of Women.** By CHARLES WEST, M.D., F.R.C.P. Fourth Edition. Revised and in part re-written by the Author, with numerous additions by J. MATTHEWS DUNCAN, M.D., F.R.C.P., F.R.S., late Obstetric Physician to St. Bartholomew's Hospital. 8vo, 16s.

ZOOLOGY.

CHAUVEAU AND FLEMING.—**The Comparative Anatomy of the Domesticated Animals.** By A. CHAUVEAU, Professor at the Lyons Veterinary School; and GEORGE FLEMING, Principal Veterinary Surgeon of the Army. With 450 Engravings. 31s. 6d.

HUXLEY.—**Manual of the Anatomy of Invertebrated Animals.** By THOMAS H. HUXLEY, LL.D., F.R.S. With 156 Engravings. Post 8vo, 16s.

By the same Author.

Manual of the Anatomy of Vertebrated Animals. With 110 Engravings. Post 8vo, 12s.

WILSON.—**The Student's Guide to Zoology:** a Manual of the Principles of Zoological Science. By ANDREW WILSON Lecturer on Natural History, Edinburgh. With Engravings. Fcap 8vo, 6s. 6d.

11. NEW BURLINGTON STREET.

